

# Visual acuity loss and OCT changes as initial signs of leukaemia

Jose M Ortiz<sup>1</sup>, Jose M Ruiz-Moreno<sup>1,2</sup>, Paola Pozo-Martos<sup>1</sup>, Javier A Montero<sup>2,3</sup>

<sup>1</sup>Department of Ophthalmology and Albacete Hospital, Castilla La Mancha University, Albacete, Spain

<sup>2</sup>Alicante Institute of Ophthalmology, VISSUM, Vitreo-Retinal Unit, Alicante, Spain

<sup>3</sup>Pío del Río Hortega University Hospital, Ophthalmology Unit, Valladolid, Spain

**Correspondence to:** Javier A Montero. Pío del Río Hortega University Hospital, Ophthalmology Unit. C/ Carraca s/n, Valladolid, 47012, Spain. javmonmor@hotmail.com

Received:2010-05-04 Accepted:2010-09-08

## Abstract

• **AIM:** To report two cases whose decreased visual acuity was the first symptom of leukaemia and optical coherence tomography (OCT) allowed identification and localization of the retinal lesions.

• **METHODS:** Retrospective, interventional, case reports.

• **RESULTS:** One case of lymphoblastic acute leukaemia and chronic lymphoid leukaemia were diagnosed following decreased visual acuity. OCT showed macular serous detachment in the first case. The second case presented hypo fluorescent retinal infiltrates which appeared as hyper reflective lesions by OCT. Retinal changes disappeared and visual acuity was recovered following complete remission of the neoplasm.

• **CONCLUSION:** OCT is a valuable, non invasive diagnostic tool permitting detection, localization and follow-up of ocular dissemination of neoplasms.

• **KEYWORDS:** acute lymphoblastic leukaemia; chronic lymphoid leukaemia; optical coherence tomography

DOI:10.3969/j.issn.1672-5123.2010.10.007

Ortiz JM, Ruiz-Moreno JM, Pozo-Martos P, Montero JA. Visual acuity loss and OCT changes as initial signs of leukaemia. *Int J Ophthalmol (Guoji Yanke Zazhi)* 2010;10(10):1864-1865

## INTRODUCTION

Leukaemias are neoplasms of the haematopoietic system which may affect the lymphopoietic or the myelopoietic line of proliferation (lymphoid or myeloid leukaemia, respectively) and be classified in acute or chronic, according to the degree of cellular differentiation<sup>[1]</sup>.

Ocular involvement in leukaemias is not uncommon and may occur in up to 28% of the cases<sup>[1,2]</sup>. Leukaemic infiltration of the eye and the orbit is third following meningeal and testicular involvement. Other ocular structures may also be involved such as the conjunctiva, cornea, sclera, iris, retina,

choroid, vitreous and optic nerve<sup>[1,2]</sup>. Retinal findings may include intraretinal haemorrhages (frequently with a whitish central area), leukaemic infiltrates, central retinal vein occlusion and vitreous haemorrhages<sup>[2]</sup>. Decreased visual acuity is an unusual initial symptom of leukaemia<sup>[3]</sup>.

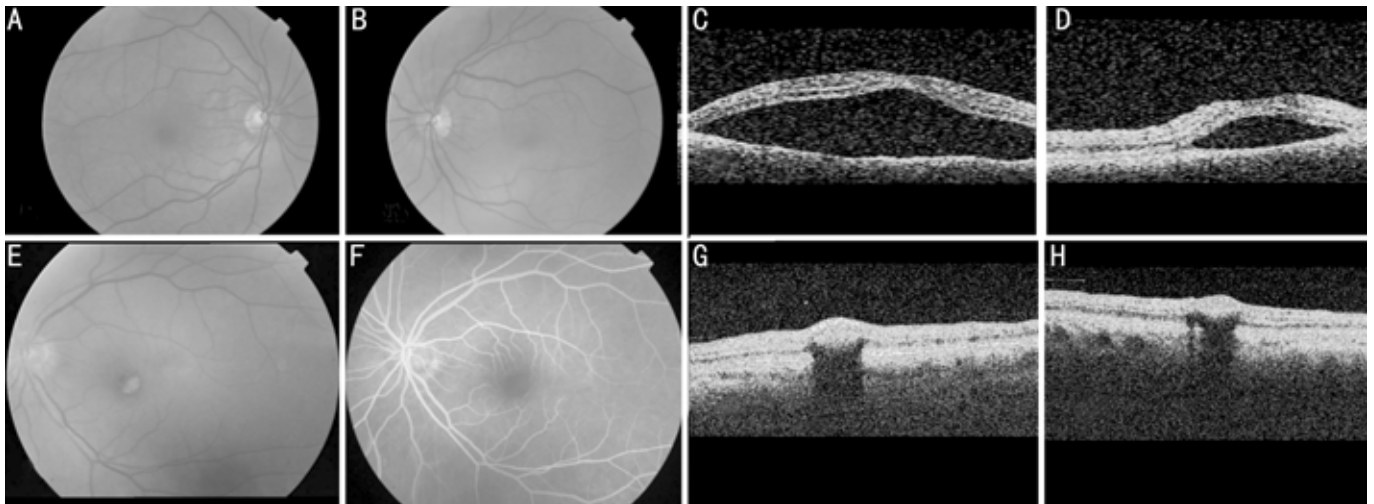
In this paper we report two cases of decreased visual acuity as the first symptom of leukaemia in which optical coherence tomography (OCT) allowed identification and localization of the retinal lesions. Written informed consent was obtained prior to data gathering. This work was performed following the guidelines for clinical investigation required by the Ethics Committee of the Albacete Hospital.

## CASE REPORTS

**Case 1** A 44-year-old male reported a scotoma in his left eye (LE) for the last 48 hours. Best-corrected visual acuity (BCVA) was 1.0 in his right eye (RE) and 0.3 in his LE. Posterior segment examination disclosed an inferior serous macular detachment in his LE extending to the inferior temporal arcade (Figure 1A-D).

Two days later BCVA was 0.2 in his LE. Fundus examination remained unchanged in the LE whereas the RE showed two small retinal serous detachments in the posterior pole. Four days later BCVA was 0.3 in both eyes. Fundus examination and OCT revealed bilateral retinal serous detachment involving the macula. The patient was started on oral acetazolamide (250 mg tid). Ten days later the patient reported malaise and presented a thoracic nodular exanthema which was diagnosed as a suspect leukemoid reaction. BCVA was 0.1 RE and 0.3 LE. Blood tests were performed showing anaemia, thrombopenia and blastic changes in the white cell series. The patient was diagnosed of lymphoblastic acute leukaemia CD20 negative (L1 FAB). Three full chemotherapy cycles on Hyper-CVAD/MTX-Arac plus intrathecal therapy (cyclophosphamide/doxorubicin/vincristine/dexamethasone alternated with methotrexate/cytarabine) were performed and a complete remission of the leukaemia and the retinal detachment, with final BCVA 1.0 in both eyes.

**Case 2** A 57-year-old female with decreased BCVA in her LE for the past 30 days presented BCVA 0.1 and 0.2 in her RE and LE, respectively, with a well delimited red-yellowish lesion. Fluorescein angiography showed hypo fluorescence without fluorescein leakage, and OCT showed a subretinal hyper reflective lesion. A retinal lesion secondary to leukaemia was suspected and the patient was referred to a haematologist and was diagnosed of chronic lymphoid leukaemia (Figure 1E-H).



**Figure 1** A-B: Colour retinographies from case 1 showing bilateral macular detachment. C-D: Optical coherence tomography (OCT) confirm neurosensory detachment. E-F: Colour retinography and fluorescein angiography (FA) from case 2 showing a well delimited yellowish and red centred lesion corresponding to a hypo fluorescent area in the FA. G-H: OCT shows a subretinal hyper reflective lesion.

## DISCUSSION

We present two unusual cases in which decreased BCVA was the first symptom to suspect leukaemia. Chorioretinal lesions occur seldom as the first sign in leukaemias and they are usually reported after the patient has been diagnosed. Leukaemic involvement of the eye may occur as a local dissemination from the central nervous system through the subarachnoidal space to the choroid, or as a blood borne dissemination<sup>[4]</sup>.

Leukaemic infiltration of the choroid may interfere with the blood supply to the retinal pigment epithelium (RPE) and cause small areas of disruption. Leukaemic choroidal involvement has been seldom reported<sup>[4,5]</sup>, appearing as a serous retinal detachment with yellowish choroidal infiltrates or involving the RPE<sup>[5,6]</sup>.

Macular serous detachments are usually associated with age related macular degeneration and central serous choroidopathy<sup>[2]</sup>. Macular serous detachment has been seldom reported in association with leukaemia<sup>[3,6]</sup>, and even less frequently as the first sign of the disease.

Early diagnosis by non invasive procedures such as OCT, and therapy may improve visual outcome in patients with leukaemic ocular involvement<sup>[5]</sup>. Correct diagnosis of the condition is highly dependant on a clinical suspicion and requires imaging and histological confirmation, especially vitreous biopsy or flow cytometry as well as subretinal aspiration and retinal biopsy. Fardeau *et al*<sup>[7]</sup> recommend imaging and histological diagnosis in cases with round, hypofluorescent lesions which appear as nodular hyper reflective lesions by OCT as occurred in the second case reported.

OCT is a valuable, non invasive diagnostic procedure in patients with neoplasm and posterior segment involvement permitting detection, localization and follow-up of the lesions derived from eye involvement, either as a macular serous detachment (as in case 1) or as a nodular lesion of the inner retinal layers (as in case 2).

## REFERENCES

1 Marín J, Saavedra S, Sanz M, Díaz-Llopis M. Leucemias. In:

- Sánchez-Salorio M, Díaz-Llopis M, Benítez-del-Castillo JM, eds. Manifestaciones oftalmológicas de las enfermedades generales. Madrid: Sociedad Española de Oftalmología, 2001
- 2 Spaide RF, Goldbaum M, Wong DW, Tang KC, Iida T. Serous detachment of the retina. *Retina* 2003;23(6):820-846; quiz 895-896
- 3 Fackler TK, Bearely S, Odom T, Fekrat S, Cooney MJ. Acute lymphoblastic leukemia presenting as bilateral serous macular detachments. *Retina* 2006;26(6):710-712
- 4 Berthou C, Roncin S, Colin J, Abgrall JF. Ocular sites of acute leukemias. *J Fr Ophthalmol* 1996;19(6-7):470-478
- 5 Gordon KB, Rugo HS, Duncan JL, Irvine AR, Howes EL Jr, O'Brien JM, Carter SR. Ocular manifestations of leukemia; leukemic infiltration versus infectious process. *Ophthalmology* 2001;108(12):2293-2300
- 6 Riss JM, Kaplanski G, Righini-Chossegros M, Harle JR, Escoffier P, Saracco JB. Bilateral serous detachment of neuroepithelium of the posterior pole disclosing acute leukemia. *J Fr Ophthalmol* 1990;13(11-12):563-568
- 7 Fardeau C, Lee CP, Merle-Béral H, Cassoux N, Bodaghi B, Davi F, Lehoang P. Retinal fluorescein, indocyanine green angiography, and optic coherence tomography in non-Hodgkin primary intraocular lymphoma. *Am J Ophthalmol* 2009;147(5):886-894, 94 e1

## 以视力损失及 OCT 改变为首发症状的白血病

Jose M Ortiz<sup>1</sup>, Jose M Ruiz-Moreno<sup>1,2</sup>, Paola Pozo-Martos<sup>1</sup>, Javier A Montero<sup>2,3</sup>

(作者单位:<sup>1</sup> 西班牙 Castilla La Mancha 大学阿利坎特医学院眼科;<sup>2</sup> 西班牙阿利坎特眼科研究所视网膜科;<sup>3</sup> 西班牙 Valladolid, Pro del Río Hortega 大学附属医院眼科组)

通讯作者:Javier A Montero. javmonmor@hotmail.com

### 摘要

**目的:**报告 2 例以视力下降为首发症状的白血病患者,采用光学相干断层扫描(OCT)识别和定位视网膜病变。

**方法:**回顾性干涉个案报告。

**结果:**伴随视力下降,确诊急性淋巴细胞白血病和慢性淋巴细胞白血病患者各 1 例。OCT 发现 1 例为黄斑部浆液性脱离。另 1 例为视网膜低荧光浸润,OCT 表现为高反射性损伤。在随访时间内,肿瘤完全缓解后视网膜改变消失,视力明显恢复。

**结论:**OCT 是一种检测、定位和跟踪的眼部肿瘤有价值的,非侵入性的诊断工具。

**关键词:**急性淋巴细胞白血病;慢性淋巴细胞白血病;光学相干断层扫描