

Syphilitic uveitis: 3 cases report

Shin Wei Pan, Nor Sharina Yusof, Wan Hazabbah Wan Hitam, Raja Azmi Mohd Noor, Zunaina Embong

Department of Ophthalmology, School of Medical Sciences, Health Campus Universiti Sains Malaysia, 16150 Kubang Kerian, Kelantan, Malaysia

Correspondence to: Wan Hazabbah Wan Hitam. Department of Ophthalmology, School of Medical Sciences, Universiti Sains Malaysia, 16150 Kubang Kerian, Kelantan, Malaysia. hazabbah@kb.usm.my

Received:2010-08-18 Accepted:2010-11-15

Abstract

• **AIM:** To evaluate the clinical manifestations and visual outcome of syphilitic uveitis patients.

• **METHODS:** Case series of three patients with syphilitic uveitis were managed in Hospital USM.

• **RESULTS:** Three patients were diagnosed to have uveitis secondary to syphilis. All three patients were not known to have syphilis prior to presentation but had positive history of sexual promiscuity. All patients presented with progressive blurring of vision for average of one-month duration. Two of them had association with fever, ocular pain and floaters. Visual acuity at presentation ranged from 6/12 to hand movement. Mild anterior uveitis (non-granulomatous), vitritis and papillitis were present in all the patients. First patient had multifocal chorioretinitis with exudative retinal detachment. The second patient presented with exudative retinal detachment while the third patient had chorioretinitis only. All the patients were treated with intramuscular benzyl-penicillin 2.4 MU weekly for 4 weeks and two of them received oral doxycycline 200mg twice daily for 3 months. The uveitis responded well to the treatment and two of them showed dramatic visual improvement from 6/120 to 6/21 and 6/12 to 6/6. The one with worse outcome was confirmed to have positive retroviral.

• **CONCLUSION:** Ocular syphilis presented here as non-granulomatous inflammation associated with exudative retinal detachment. Final visual outcome is generally good despite slow improvement after treatment.

• **KEYWORDS:** syphilis; uveitis; chorioretinitis; exudative retinal detachment

DOI:10.3969/j.issn.1672-5123.2010.12.004

Pan SW, Yusof NS, Hitam WHW, Noor RAM, Embong Z. Syphilitic uveitis: 3 cases report. *Int J Ophthalmol (Guji Yanke Zazhi)* 2010;10(12):2242-2245

INTRODUCTION

Syphilis is a sexually transmitted, chronic, systemic infection caused by the spirochete *Treponema pallidum*.

It can affect all the structures of the eye causing conjunctivitis, episcleritis, interstitial keratitis, iridocyclitis, anterior, intermediate, posterior uveitis, secondary glaucoma, cataract, vitritis, chorioretinitis, vasculitis, serous retinal detachment, papillitis and optic neuropathy^[1]. Uveitis represents the most common ocular manifestations of acquired syphilis^[2,3]. Involvement of the eye may be the presenting manifestation of syphilis and it often associated with delayed diagnosis and treatment, which may result in irreversible visual loss and structural changes^[1]. Herewith, we report three cases of syphilitic uveitis and illustrate its clinical manifestations and visual outcome in response to the treatment given.

CASE 1

A 68-year-old Chinese man presented with history of progressive blurring of vision in the left eye for one-month duration. It was associated with pain, redness and seeing floaters. He was also having low grade fever a week prior to admission. He had history of sexual promiscuity and was treated several times for sexually transmitted disease about 40 years ago. Patient was generally well with no neurological deficit. Ocular examinations revealed visual acuity of 6/12 in the right and 6/120 in the left eye. The intraocular pressure was normal in the right but was raised in the left (35mmHg). The conjunctiva of the left eye was injected with mild cornea oedema. There was presence of fine keratic precipitates with moderate anterior chamber reaction and vitritis. The anterior segment of the right eye was normal. Both fundi showed hyperaemic swollen optic discs with multifocal chorioretinitis lesions in the periphery (Figure 1). There was also bilateral mild exudative retinal detachment inferiorly not involving the posterior pole. The macula in both eyes was oedematous. He was treated with topical steroids, cycloplegia and antiglaucoma. Blood investigations revealed venereal disease research laboratory (VDRL) test reactive at 1:2 with positive *Treponema pallidum* haemagglutination assay (TPHA). The Mantoux test and HIV were negative.

He was then started with intramuscular benzyl penicillin 2.4 MU weekly for 3 weeks and oral doxycycline 200mg daily. Patient was also given intravenous ciprofloxacin 200mg twice daily for 2 weeks and oral prednisolone for 4 weeks with tapering dose after that. Patient condition improved after six weeks of treatment. His visual acuity was improved to 6/6 in right eye and 6/21 in the left. The anterior uveitis and vitritis were resolved. Optic disc swelling in both eyes was reduced and the multifocal chorioretinitis lesions became pigmented and quiet. Oral doxycycline was continued up to 3 months.

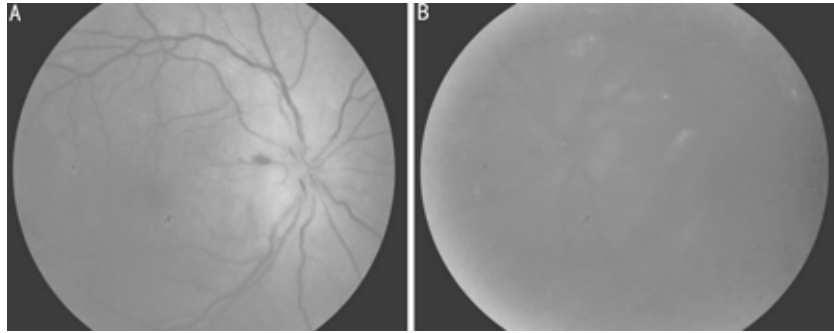


Figure 1 Fundus showed hyperemic swollen optic disc with multifocal chorioretinitis at the peripheral of the retina A: Right; B: Left.

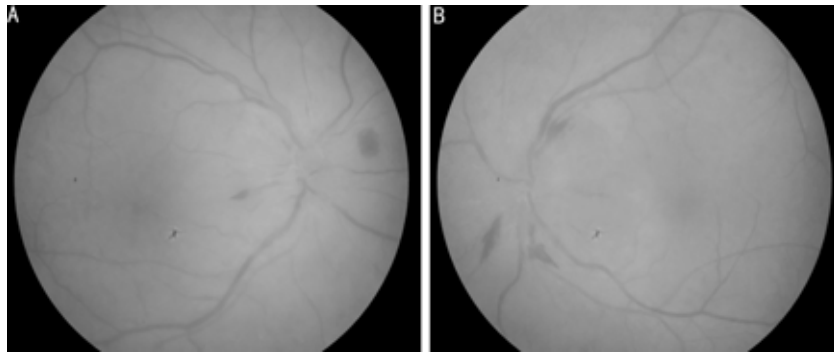


Figure 2 Fundus showed swollen optic discs with flamed shaped hemorrhages and congested peripapillary veins A:Right; B:Left.

During follow-up at 3 month post treatment, both eyes were quiet and both optic discs were normal.

CASE 2

A 66-year-old Malay man, chronic smoker, presented with history of progressive painless blurring of vision in both eyes for 3 weeks duration. It was associated with visual distortion and metamorphopsia. There was no history of redness, floaters, flashes of light and visual field defect. He also had underlying problem of ischemic heart disease and hypertension that were currently stable on treatment. He had history of marriages for five times and has ten children. Apart from that, he also reported to have history of sexual promiscuity during young age. Patient was generally healthy with no neurological deficit. Ocular examination revealed his visual acuity in both eyes was 6/12. There was no relative afferent papillary defect. Both conjunctivae were normal and not injected. There was presence of diffuse fine keratic precipitates in both eyes with mild anterior chamber inflammation and vitritis. Peripheral fundus showed mild exudative retinal detachment in both eyes sparing of macular area. Both optic discs appeared swollen and hyperemic. Peripapillary veins were congested with flamed shaped hemorrhages surrounding the peripapillary area (Figure 2). However, there was no chorioretinitis lesion seen in both eyes.

Blood investigations revealed VDRL test reactive at 1:2 and TPHA was positive. Full blood count and ESR were normal. Mantoux test and retroviral test were negative. CT brain and orbit was normal. He was treated with intramuscular benzyl penicillin 2.4 MU weekly for 3 weeks. The exudative retinal detachment and optic disc papillitis was gradually resolved after one month. He achieved vision of 6/6 in both eyes at six month of follow-up.

CASE 3

A 40 year-old Malay man presented with history of progressive blurring of vision in both eyes for more than a month. It was associated with pain, redness and photophobia. He had history of low-grade fever for 3 weeks prior to admission. He is a homosexual with history of sexual promiscuity. He is also intravenous drug abuser for the past ten years. He had history of recurrent genital ulcer that resolved spontaneously. Patient general condition was healthy except for palpable lymph node in the inguinal region. There was no neurological deficit and no ulcer in genital area. Ocular examination revealed visual acuity of hand movement in both eyes. Both pupils were sluggish. The right eye was injected with presence of fine keratic precipitates. There was mild anterior chamber inflammation and vitritis in both eyes. The fundus view was hazy in the right eye. However, the left fundus showed hyperemic optic disc with retinitis and vasculitis (Figure 3). Blood investigations revealed ESR of only 2mm/h. VDRL test was reactive at 1:8 and TPHA was positive. Mantoux test and sputum acid fast bacilli (AFB) were negative with normal chest radiography. Tests for HIV were positive with CD4 count of >400. He was started on im benzyl penicillin 2.4 MU weekly for 3 weeks with oral doxycycline 200mg twice daily for 3 months. He was referred to the infectious disease unit for further management of HIV status. Antiretroviral was not started as he has not fulfilled the criteria. Patient's condition was improved after completion of intramuscular benzyl penicillin. His visual acuity was improved to counting finger at one foot after 3 months. The anterior uveitis and vitritis were resolved. The views of both fundi were clear with residual chorioretinal scar.

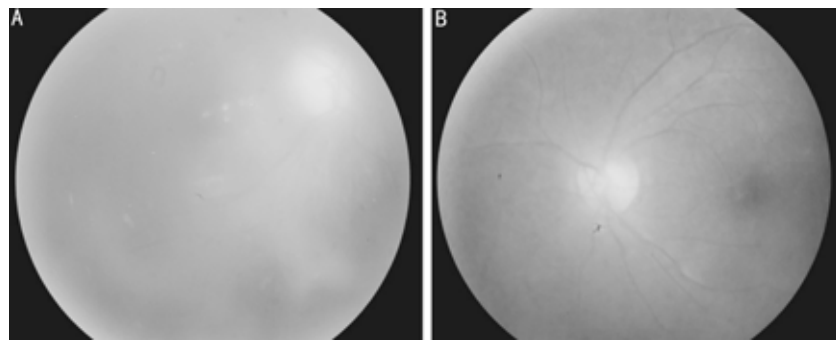


Figure 3 Fundus showed hazy view due to vitritis with hyperemic optic disc, retinitis and vasculitis A: Right; B:Left.

DISCUSSION

Syphilis is known to be the great masquerader of diseases. It is transmitted via direct sexual contact, contact with infected lesion or transplacental transmission in congenital syphilis. The incidence of this disease was greatly reduced with the advent of Penicillin. However, it has resurgence with the prevalence of Human Immunodeficiency Virus infection in high risk behavior lifestyle. In the metropolitan UK, ocular syphilis was rare but is now merely uncommon due to rise in incidence of syphilis^[4]. Nevertheless, the incidences of ocular syphilis were not increased in Asian country as noted by Anshu *et al*^[5]. Syphilis infection can be divided into four stages, namely primary, secondary, latent and tertiary syphilis. The eye could be affected in any stage of the disease. Primary syphilis is characterized by a chancre. It is a painless ulceration appearing 2-6 weeks after infection and spontaneously resolves within 3-6 weeks. Secondary syphilis presents commonly with maculopapular rash, which is non-specific and spontaneously resolve. When left untreated, the patients will progress to tertiary syphilis. Tertiary syphilis is characterized by cardiovascular involvement and neurosyphilis. Involvement of the eye has a wide range of presentation from interstitial keratitis, anterior uveitis, posterior uveitis, panuveitis to serous retinal detachment with contradictory prevalence^[1,5,7]. Our case series here show non-granulomatous panuveitis as the main manifestation of ocular syphilis. Both patients have no other systemic manifestations of syphilis, indicating that ocular uveitis can be the initial presentation of syphilis^[1].

Diagnosis of infection with *Treponema pallidum* based on clinical presentation and supported by traditional serologic testing such as non-treponemal test and treponemal test. Non-treponemal test includes VDRL and the rapid plasma regain (RPR) test, which are useful in screening for active disease and antibody quantification. Treponemal tests such as fluorescent treponemal antibody absorption (FTA-ABS) test, the microhemagglutination-*T. pallidum* (MHA-TA) test and the *T. pallidum*-particle agglutination test are used for confirmation of previous or current infection^[8]. The VDRL titre may not be proportional to the level of the disease activity, rendering it ineffective for the monitoring the effects of treatment^[9]. Recent advancement in enzyme immunoassays and polymerase chain reaction-based assays are some of the more sensitive tests that can be used. However, these tests

are not widely available. Literature has suggested CSF VDRL for the diagnosis of neurosyphilis^[7] but most case series did not have a high yield of VDRL in their patients^[11]. The CSF VDRL test is highly specific but not sensitive and a negative result should not eliminate the suspicion of neurosyphilis. In our case series, the diagnosis of syphilitic uveitis was made, based on laboratory blood investigations with no CSF analysis done.

Penicillin remains the mainstay of therapy for all stages and sites of syphilis. The most current published recommendation for the treatment of early syphilis-primary, secondary, or early latent are to give 2.4 MU of penicillin-G benzathine intramuscularly for two to three weeks^[10]. This dose maintains a blood concentration above that minimally acceptable for treponemicidal concentration. The neurosyphilis treatment regime varies, but generally recommends intravenous penicillin G 12-24 MU per day for up to 21 days. The optic nerve, retina and other neuroepithelial structures are embryological derived from the central nervous system. Involvement of these structures would constitute as neurosyphilis and be treated as such as suggested by Browning^[6]. However, our patients were all treated with penicillin intramuscularly and have shown great improvement clinically and also in visual function. All syphilitic uveitis patients progress need to be monitored as literature revealed 14% risk of relapse even in the group of patient whom were given the neurosyphilis regime^[6].

HIV-infected patients responded less well serologically than HIV-negative patients as they are noted to be more prone to progressive syphilitic infection. Patients co-infected with HIV have a more severe course and poorer visual outcome^[11], which is in keeping with our patient in case 3 whom only has slight improvement in vision after completion of treatment. On the other hand, patients in case 1 and 2, who were HIV negative showed dramatic improvement after treatment.

The most common presentation in HIV-positive patients was posterior uveitis and patients whom present with isolated syphilitic anterior uveitis were 14.5 times more likely to be HIV-positive^[3]. The fact that ocular symptoms led to the discovery of HIV seropositivity in our patient and in other studies^[2,11], highlights the need for HIV screening in patients with syphilitic uveitis. Patient with HIV-positive were 1.34 times more likely to have CSF abnormality with or without syphilis, thus undermining the benefit of this test in this group

of patients^[3,11]. There was no significant difference in efficacy for the different treatment modalities between intravenous and intramuscular treatment in this group of patient and with aggressive treatment there is still possibility of relapse^[2,3]. These patients may need prolonged treatment and need close monitoring post treatment^[3,11].

In conclusion, non-granulomatous uveitis can be the initial presentation in patients not known to have syphilis. Awareness of the myriad presentations of ocular syphilis will aid in early diagnosis and treatment. Early detection and treatment will usually preserve visual acuity and ocular function. Final visual outcome is generally good despite slow improvement after treatment.

REFERENCES

- 1 Hong MC, Sheu SJ, Wu TT, Chuang CT. Ocular uveitis as the initial presentation of syphilis. *J Chinese Med Assoc* 2007;70(7):274-280
- 2 Lynn WA, Lightman S. Syphilis and HIV: a dangerous combination. *Lancet Infect Dis* 2004;4(7):456-466
- 3 Amarantunge BC, Camuglia JE, Hall AJ. Syphilitic uveitis: a review of clinical manifestations and treatment outcomes of syphilitic uveitis in human immunodeficiency virus-positive and negative patients. *Clin Exp Ophthalmology* 2010;38(1):68-74
- 4 Doris JP, Saha K, Jones NP, Suthankar A. Ocular syphilis: the new epidemic. *Eye* 2006;20(6):703-705
- 5 Anshu A, Cheng C, Chee S. Syphilitic uveitis: an Asian perspective. *Brit J Ophthalmology* 2008;92(5):594-597
- 6 Browning DJ. Posterior segment manifestations of active ocular syphilis, their response to a neurosyphilis regimen of penicillin therapy, and the Influence of Human Immunodeficiency Virus Status on response. *Ophthalmology* 2000;107(11):2015-2023
- 7 Pinon-Mosquera R, Jimenez-Benito J, Olea-Cascon J. Syphilitic bilateral panuveitis: a case report. *Arch Soc Esp Oftalmol* 2009;84(2):101-104
- 8 Aldave AJ, King JA, Cunningham ET. Ocular syphilis. *Curr Opin Ophthalmol* 2001;12(6):433-441

9 Chao JR, Khurana RN, Fawzi AA. Syphilis: reemergence of an old adversary. *Ophthalmology* 2006;113(11):2074-2079

10 Centers for Disease Control and Prevention; 1993 Sexually transmitted diseases - Treatment guidelines. *MMWR* 1993;42(RR-14):27-46

11 Tran THC, Cassoux N, Bodaghi B. Syphilitic uveitis in patients infected with human immunodeficiency virus. *Graefes Arch Clin Exp Ophthalmol* 2005;243(9):863-869

梅毒性葡萄膜炎 3 例

Shin Wei Pan, Nor Sharina Yusof, Wan Hazabbah Wan Hitam, Raja Azmi Mohd Noor, Zunaina Embong

(作者单位: 马来西亚吉兰丹, 马来西亚理科大学医学院眼科)

通讯作者: Wan Hazabbah Wan Hitam. hazabbah@kb.usm.my

摘要

目的: 评估梅毒性葡萄膜炎患者的临床表现和视力。

方法: 梅毒性葡萄膜炎患者 3 例在 USM 医院接受治疗。

结果: 患者 3 例被诊断为继发性梅毒性葡萄膜炎, 这 3 例患者患病之前均不知道患有梅毒, 但他们有明确的乱交史。并且每个月都伴有逐步的视力下降。其中两人伴有发热、眼痛、眼前悬浮物。视力从 6/12 到手动。所有患者均出现前葡萄膜炎, 玻璃体炎和视神经炎。第一例患者出现了多灶性脉络膜视网膜炎, 并伴有渗出性视网膜脱离。第二例患者出现渗出性视网膜脱离, 而第三例患者仅出现了脉络膜视网膜炎。所有患者每周注射苄青霉素 2.4MU, 共 4wk, 其中 2 例患者口服多西霉素 200mg 2 次/d, 共 3mo。治疗效果良好, 其中 2 例患者有显著的视力上升, 分别从 6/120 到 6/21 和 6/12 到 6/6。其中较严重的 1 例患者出现逆转录酶为阳性。

结论: 眼梅毒作为非肉芽肿性的炎症与渗出性视网膜脱离有关。治疗后虽然视力恢复比较缓慢, 但普遍有良好的效果。

关键词: 梅毒; 葡萄膜炎; 脉络膜视网膜炎; 渗出性视网膜脱离