

Vitreous hemorrhage and fibrovascular proliferation after laser-induced chorioretinal venous anastomosis

Tomoyasu Shiraya, Satoshi Kato, Takashi Shigeeda, Harumi Fukushima

Department of Ophthalmology, University of Tokyo Graduate School of Medicine, Tokyo, Japan

Correspondence to: Satoshi Kato. Department of Ophthalmology, University of Tokyo Graduate School of Medicine, 7-3-1, Hongo, Bunkyo-ku, Tokyo, 113-8655, Japan. katou-s@ka2. so-net. ne. jp

Received: 2011-02-10 Accepted: 2011-03-28

Abstract

• **AIM:** To describe a case in which vitrectomy was required for vitreous hemorrhage and fibrovascular proliferation after laser-induced chorioretinal venous anastomosis (LCVA) for non-ischemic central retinal vein occlusion (CRVO).

• **METHODS:** Observational case report.

• **RESULTS:** A 72-year-old man complained of central scotoma in the left eye, and was diagnosed as suffering from non-ischemic CRVO. LCVA was performed in another hospital. Although favorable visual function was briefly maintained postoperatively, severe vitreous hemorrhage developed in his left eye, necessitating vitrectomy.

• **CONCLUSION:** Considering that LCVA carries a risk of serious complications, we must apply this treatment with caution, especially in ethnic groups, such as the Japanese, in whom pigmentation reacts to photocoagulation excessively.

• **KEYWORDS:** vitreous hemorrhage; fibrovascular proliferation; laser-induced chorioretinal venous anastomosis; non-ischemic central retinal vein occlusion

DOI: 10. 3969/j. issn. 1672-5123. 2011. 05. 004

Shiraya T, Kato S, Shigeeda T, Fukushima H. Vitreous hemorrhage and fibrovascular proliferation after laser-induced chorioretinal venous anastomosis. *Guji Yanke Zazhi (Int J Ophthalmol)* 2011; 11 (5): 765-766

INTRODUCTION

One of the treatments for non-ischemic central retinal vein occlusion (CRVO) is laser-induced chorioretinal venous anastomosis (LCVA), first proposed by Mcallister nearly a decade ago^[1,2]. The aim of LCVA is to create a chorioretinal venous anastomosis using laser photocoagulation, allowing obstructed venous blood to enter the choroid, and thereby circumventing the site of occlusion. However, many studies conducted after McAllister's proposal obtained rather low success rates with LCVA for CRVO (approximately 30% to 50%) and numerous complications were documented.

We present a case in which vitrectomy was required for vitreous hemorrhage and fibrovascular change which developed

after LCVA for non-ischemic CRVO, despite temporary favorable visual function have been achieved with this treatment.

CASE REPORT

A 72-year-old man complained of central scotoma in the left eye in early July, 2002. He consulted an ophthalmologist on August 21st. CRVO was diagnosed in his left eye and he underwent LCVA. However, one week later, he became anxious about his ocular condition and asked for a second opinion at our hospital. His visual acuity was 20/100 in the left eye. Funduscopy revealed retinal vein dilation, blot hemorrhages, slight macular edema, vitreous hemorrhage and choroidal neovascularization associated with a fibrovascular membrane. As fluorescein angiography (FA) revealed no ischemic areas, we assumed the CRVO to be of the non-ischemic type and followed this patient without further photocoagulation. One month after LCVA, his visual acuity was unchanged (Figure 1) but had improved to 20/40 two months later and, at this time, funduscopy showed resolution of the macular edema but worsening of the fibrovascular membrane which involved traction of the chorioretinal anastomosis. Six months after LCVA, his visual acuity recovered to 20/25 thanks to disappearance of both the macular edema and the retinal hemorrhages, but the fibrovascular membrane persisted and vitreous hemorrhage was detected at the inferior fundus (Figure 2). Subsequently however, severe vitreous hemorrhage developed and his visual acuity deteriorated to hand motion. We anticipated absorption of the hemorrhage, but, unfortunately, this did not occur. On March 23rd 2003, we conducted vitrectomy with cataract surgery for the purpose of removing the vitreous hemorrhage and eliminating the retinal traction caused by the fibrovascular membrane. He had no systemic diseases other than hypertension. During the operation, posterior vitreous detachment was identified, but not in the region between the optic disc and the LCVA spot where the retina and the vitreous adhered to each other. Therefore, we removed the adhesion, and excised both the vitreous hemorrhage and the fibrovascular membrane using a vitreous cutter. His visual acuity was better than 20/20 after the surgery. Six months after the operation, the fundus had stabilized, although inactivated fibrovascular membrane persisted (Figure 3).

DISCUSSION

After the presentation of Mcallister's report^[1], LCVA became popular and began to be widely used for the treatment of non-ischemic CRVO in many other institutions. However, many subsequent reports highlighted the disadvantages of this method^[3-5].




Figure 1 One month after LVCA, funduscopy showed blot hemorrhages, slight macular edema, vitreous hemorrhage and choroidal neovascularization accompanying fibrovascular membrane formation. A fluorescein angiography (FA) revealed no ischemic areas.

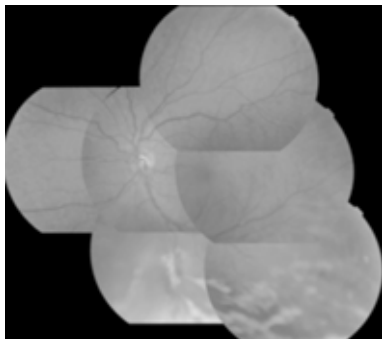


Figure 2 Six months after LCVA, macular edema and retinal hemorrhage disappeared, but the fibrovascular membrane persisted and vitreous hemorrhage could be seen at the inferior fundus.

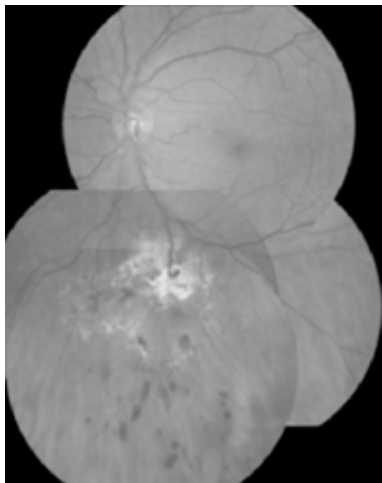


Figure 3 Six months after vitrectomy, the fibrovascular membrane dissection resulted in the vitreous hemorrhage being totally absorbed. Although a small amount of fibrous membrane could still be seen, no signs of re-activation were evident.

For example, choroidal neovascular membrane^[3], preretinal membrane, tractional retinal detachment^[4], anterior segment neovascularization, vitreous hemorrhage, and fibrovascular membrane^[5] were reportedly observed after this therapy.

In the present case, initial visual acuity was 20/100 at our hospital. Consequently, this patient did not seem to have a good chance of vision improvement. Therefore, LCVA was an

appropriate choice of treatment in this case. However, the patient underwent LCVA and consequently suffered significantly more severe visual complications. Although his visual acuity was ultimately restored, the acceptability of LCVA for non-ischemic CRVO should be reconsidered. As non-ischemic CRVO has a better prognosis than ischemic CRVO. In relatively pigmented races like the Japanese, the application of this treatment should be carefully considered because reactions to photocoagulation tend to be excessive. Even if this treatment is used, it should be performed using a modified technique^[6,7] to prevent complications.

REFERENCES

- 1 Mcallister IL, Constable IJ. Laser-induced chorioretinal venous anastomosis for treatment of nonischemic central retinal vein occlusion. *Arch Ophthalmol* 1995;113:456-462
- 2 Mcallister IL, Douglas JP, Constable IJ, Yu D. Laser-induced chorioretinal venous anastomosis for nonischemic central retinal vein occlusion; Evaluation of the complications and their risk factors. *Am J Ophthalmol* 1998;126:219-229
- 3 Eccarius SG, Moran MJ, Slingsby JG. Choroidal neovascular membrane after laser-induced chorioretinal anastomosis. *Am J Ophthalmol* 1996;122:590-591
- 4 Luttrull JK. Epiretinal membrane and traction retinal detachment complicating laser-induced chorioretinal venous anastomosis. *Am J Ophthalmol* 1997;123:698-699
- 5 Browning DJ, Antoszyk AN. Laser chorioretinal venous anastomosis for nonischemic central retinal vein occlusion. *Ophthalmology* 1998;105:670-679
- 6 Leonard BC, Coupland SG, Kertes PJ, Bate R. Long-term follow-up of a modified technique for laser-induced chorioretinal venous anastomosis in nonischemic central retinal vein occlusion. *Ophthalmology* 2003;110:948-954
- 7 Chang MA, Finkelstein D. Modified laser-induced chorioretinal anastomosis for treatment of longstanding perfused central retinal vein occlusion. *Retina* 2005;26:824-825

激光诱导脉络膜视网膜静脉吻合术后玻璃体出血及纤维血管增生 1 例

Tomoyasu Shiraya, Satoshi Kato, Takashi Shigeeda, Harumi Fukushima

(作者单位:日本东京,东京大学医学研究生院眼科)

通讯作者:Satoshi Kato. katou-s@ka2.so-net.ne.jp

摘要

目的:报告 1 例非缺血性中央视网膜静脉阻塞的患者实施激光诱导脉络膜视网膜静脉吻合术后出现玻璃体出血及纤维血管增生而进行玻璃体切割术。

方法:病例报告。

结果:患者,男,72 岁,主诉左眼中央有一暗点,诊断为非缺血性中央视网膜静脉阻塞。在其他医院实施激光诱导脉络膜视网膜静脉吻合术。术后患者左眼视力短暂恢复,但并发严重的玻璃体出血,遂来我院实施玻璃体切割术。

结论:激光诱导脉络膜视网膜静脉吻合术有发生严重并发症的危险,要求临床医师慎重选择,特别是对于某些种族(比如日本),因为色素沉着可引起光凝过度反应。

关键词:玻璃体出血;纤维血管增生;激光诱导脉络膜视网膜静脉吻合术;非缺血性中央视网膜静脉阻塞