

Management and treatment of bizarre open globe trauma in three steps: a case report

Lala Ceklic¹, Slobodanka Latinovic¹, Aljoscha S. Neubauer², Djoko Obucina¹, Bobana Petrovic¹

¹Clinical Center of Eastern Sarajevo- Eye Clinic Kasindo, Eastern Sarajevo, BiH

²Ludvig Maximillian Univeristy Eye Clinic, Munich, Germany

Correspondence to: Lala Ceklic. Clinical Center of Eastern Sarajevo-Eye Clinic Kasindo, Eastern Sarajevo, BiH. lceklic@paleol.net

Received:2011-01-08 Accepted:2011-04-01

Abstract

• This is a case presentation of a very bizarre open globe trauma with anterior segment foreign body-fishing hook stuck in the cornea and iris. Complications due to this kind of eye trauma might be very hazardous and with serious impact on visual function. We are representing our approach and experience of three step management of this kind of eye injury: first-extract the foreign body, close and reconstruct the eyeball, second-fight inflammation, and third-restore the visual function by cataract surgery.

• **KEYWORDS:** eye trauma; anterior segment foreign body; traumatic cataract

DOI:10.3969/j.issn.1672-5123.2011.05.005

Ceklic L, Latinovic S, Neubauer AS, Obucina D, Petrovic B. Management and treatment of bizarre open globe trauma in three steps: a case report. *Guoji Yanke Zazhi(Int J Ophthalmol)* 2011; 11(5):767-768

CASE REPORT

A ten years old boy K. M presented with penetrating injury of the left eye with a foreign body- fishing hook, stuck in the cornea and iris. Injury occurred upon casting the fishing hook, when it bounced on the rock and hit the eye. The first examination (Figure 1) revealed the fishing hook with one of its three legs wedged in the anterior segment of the eye, penetrating full thickness of the cornea paracentral at 2 o'clock. Anterior chamber exhibited diffuse dispersion of blood and the tip of the hook stuck in the iris at 3 o'clock. Lens was clear and red reflex was without defects. Evaluation of the posterior segment revealed normal finding. Visual acuity measured by Snellen was 20/20 on both eyes. The child was immediately prepared for endotracheal general anesthesia and introduced to the operating room to extract the foreign body from the eye and repair the wound. After extraction of the fishing hook, blood from the anterior chamber was rinsed with

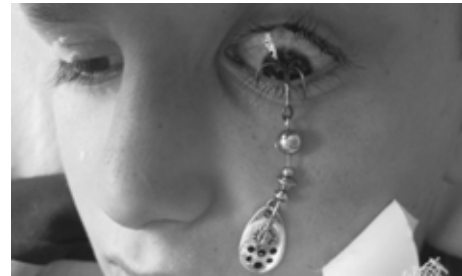

Figure 1 Fishing hook stuck in anterior segment of the eye.

a standard irrigation cannula, and 0.1mL of crystalline penicillin was injected intracamerally. One suture was placed on the corneal wound (Dexon 10/0). Anterior chamber was repaired but a slight fibrinous exudation was present. Micropuncture of anterior lenticular capsule caused by the tip of the fishing hook was noticed. Postoperatively, the child has been prescribed with systemic antibiotic (Amoxicillin 4 × 250mg) for 7 days, and locally with topical corticosteroids 4 times per day for 4 weeks and mydriaticum (atropin 10g/L) 2 times per day for 7 days.

Fourteen days later, the child returned complaining of foggy vision with visual loss on Snellen 20/200. The eye was quiet, without inflammation, corneal wound displayed noticeable siderosis, no leakage was present, anterior chamber was quiet without exudation and cells, pupil was in artificial mydriasis with posterior synechia in the region of capsular damage and cataract was evident. Ultrasound was performed and there was no evidence of intraocular inflammation and retinal damage.

Two months after the injury, child was referred to a pediatric cataract surgeon, and phacoemulsification with intraocular implantation of soft silicone (+ 21.50D) and sinechiolysis was performed. Seven days after this procedure vision on that eye with correction of -1.50D was 20/20. Examination results showed that eye was quiet without inflammation, siderosis was still evident on the injury site at two o'clock, fenestra and an atrophic zone of the iris appeared at 3 o'clock, pupil was round, regular, and intraocular lens (IOL) was placed in a capsular bag. There was a slight fibrosis on posterior capsule (Figure 2). Posterior segment of the eye was normal.

DISCUSSION

Eye trauma is considered as a very serious cause of visual disability in childhood. The outcome of our case was very good as a result of the immediate surgical treatment and cooperation of comprehensive and pediatric ophthalmologists.

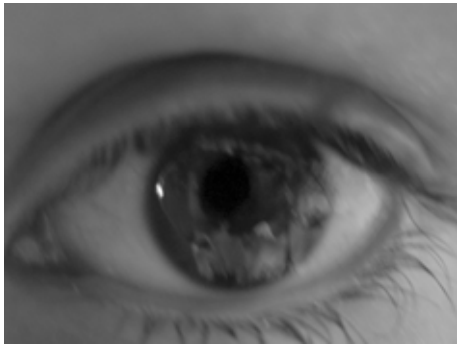


Figure 2 Seven days after phacoemulsification.

The main steps of such treatment are: first-extract the foreign body, close and reconstruct the eyeball, second-fight inflammation, and third-restore the visual function by cataract surgery.

We have a case of bizarre open globe injury with a fishing hook as an anterior segment foreign body. Approximately 2.5 million eye injuries occur annually in the United States. It is estimated that approximately 4%-5% of a comprehensive ophthalmologist's patients are seen as secondary to ocular injury. One third of all cases of childhood blindness result from ocular trauma. Complications due to this condition as we predicted are: hyphema, endophthalmitis, traumatic cataract, retinal detachment and loss of visual acuity^[1,2]. As in our case, the immediate surgical debridement, systemic application of antibiotics, and local and long lasting treatment with local corticosteroids and antibiotics could prevent inflammation which is a leading cause of visual disability and loss of visual function in similar cases. The prevalence of traumatic infective endophthalmitis was about 4.5%^[3]. Traumatic cataract may present as acute, subacute, or late consequence of ocular trauma^[4]. In our case, subacute cataract development

was observed. As a very profound lenticular opacification and decreased vision were present, we have performed cataract surgery and implanted the intraocular lens in the capsular bag, because no evidence of zonular damage was detected. There are doubts about whether aphakia is a preferable condition, but we have decided to perform the implantation immediately due to the faster visual recovery and favorable conditions for successful implantation that were present in this case.

REFERENCES

- 1 Bord SP, Linden J. Trauma to the globe and orbit. *Emerg Med Clin North Am* 2008;26(1):97-123
- 2 Esmali B, Elnor SG, Schork MA, Elnor VM. Visual outcome and ocular survival after penetrating trauma. A clinicopathologic study. *Ophthalmology* 1995;102(3):393-400
- 3 Jan S, Khan S, Mohammad S. Profile of Ocular emergencies requiring admission. *Pak J Ophthalmol* 2002;18:72-76
- 4 Graham RH, Mulrooney BC. Cataract traumatic. <http://emedicine.medscape.com/article/1211083-overview>

复杂性眼外伤治疗

Lala Ceklic¹, Slobodanka Latinovic¹, Aljoscha S. Neubauer², Djoko Obucina¹, Bobana Petrovic¹

(作者单位:¹波黑东萨拉热窝,东萨拉热窝眼科临床中心;²德国慕尼黑,Ludvig Maximilian 大学眼科诊所)

通讯作者:Lala Ceklic. lceklic@paleol.net

摘要

本文报告开放性眼球损伤1例,鱼钩卡在角膜和虹膜处。由于这种复杂眼外伤可能导致非常危险的并发症,并且严重影响视觉功能。现将处理方法总结如下:首先,取出异物,缝合眼球;其次,抗感染治疗;最后,实施白内障手术以便视力恢复。

关键词:眼外伤;前房异物;外伤性白内障