

# Foveal anatomical configuration in fellow eyes of patients with idiopathic macular hole by spectral – domain optical coherence tomography ( the FAC study )

Andre M. V. Gomes<sup>1,2</sup>, Thais S. Mendes<sup>1,3</sup>, Michele M. Freitag<sup>1</sup>, Suel Abujamra<sup>1</sup>

<sup>1</sup>Department of Ophthalmology, Suel Abujamra Institute, Sao Paulo 01531-000, Brazil

<sup>2</sup>Department of Ophthalmology, University of Sao Paulo, Sao Paulo 05403-900, Brazil

<sup>3</sup>Department of Ophthalmology, University of California, San Francisco, CA 94143, USA

**Correspondence to:** Thais S. Mendes. Department of Ophthalmology, Suel Abujamra Institute, 693 Tamandare St, 9<sup>th</sup> Floor, Sao Paulo 01525-001, Brazil. thaismendesoft@gmail.com

Received: 2013-12-04 Accepted: 2014-08-11

## SD-OCT 对特发性黄斑裂孔患者对侧眼中心凹组织形态的观察

Andre M. V. Gomes<sup>1,2</sup>, Thais S. Mendes<sup>1,3</sup>, Michele M. Freitag<sup>1</sup>, Suel Abujamra<sup>1</sup>

(作者单位:<sup>1</sup> 01531-000 巴西圣保罗, Suel Abujamra Institute 眼科; <sup>2</sup>05403-900 巴西圣保罗, 圣保罗大学眼科系; <sup>3</sup>94143 美国加利福尼亚, 加利福尼亚大学眼科系)

通讯作者: Thais S. Mendes. thaismendesoft@gmail.com

### 摘要

**目的:** 通过频域光学相干断层扫描 (spectral-domain optical coherence tomography, SD-OCT) 观测特发性黄斑裂孔患者对侧眼中心凹的形态结构变化。

**方法:** 将 50 例 50 眼研究对象分为两组: 组 1 为 25 例特发性黄斑裂孔患者, 组 2 为 25 位健康人 (对照组)。使用 RTVue 100 (Optovue, Inc., Fremont, CA, USA) 的“交叉十字”SD-OCT 扫描模式, 对所有研究对象进行黄斑中心凹广域 B 型方向扫描。通过卡尺工具测量二维横断面图上中心凹的形态面积。

**结果:** 组 1 中心凹形态面积为  $0.159 \pm 0.03 \text{mm}^2$ , 组 2 为  $0.079 \pm 0.01 \text{mm}^2$ 。两组比较, 差异有统计学意义 ( $P < 0.001$ )。组 1 中有 1 例患者对侧眼产生黄斑裂孔。

**结论:** 同健康人相比, 特发性黄斑裂孔患者的对侧眼中心凹形态有增大趋势。该发现结合其他的一些玻璃体黄斑的致病因素, 可能导致特发性黄斑裂孔。

**关键词:** 中心凹; 黄斑裂孔; 对侧眼

**引用:** Gomes AMV, Mendes TS, Freitag MM, Abujamra S. SD-OCT 对特发性黄斑裂孔患者对侧眼中心凹组织形态的观察. 国际眼科杂志 2014;14(11):1917-1920

### Abstract

• **AIM:** To evaluate anatomic foveal configuration changes in fellow eyes of patients with idiopathic macular hole using spectral-domain optical coherence tomography (SD-OCT).

• **METHODS:** Fifty eyes of fifty patients were studied and divided in two groups: group 1 = 25 patients with idiopathic macular hole and group 2 = 25 healthy individuals (control group). SD-OCT cross line scans were obtained using RTVue 100 (Optovue, Inc., Fremont, CA, USA). The widest foveal B-scan was selected on each patient. Bi-dimensional foveal configuration was measured in  $\text{mm}^2$  using caliper tool.

• **RESULTS:** The mean foveal configuration in group 1 was  $0.159 \pm 0.03 \text{mm}^2$  and in group 2 was  $0.079 \pm 0.01 \text{mm}^2$ . The difference between the two groups was statistically significantly ( $P < 0.001$ ). In group 1, one patient developed a macular hole in the fellow eye.

• **CONCLUSION:** Fellow eyes of patients with idiopathic macular hole tend to have an enlarged foveal configuration when compared to healthy subjects. Our finding combined with other vitreomacular risk factors may play a role in idiopathic macular hole formation.

• **KEYWORDS:** foveal pit; macular hole; fellow eyes

DOI:10.3980/j.issn.1672-5123.2014.11.01

**Citation:** Gomes AMV, Mendes TS, Freitag MM, Abujamra S. Foveal anatomical configuration in fellow eyes of patients with idiopathic macular hole by spectral-domain optical coherence tomography (the FAC study). *Guoji Yanke Zazhi (Int Eye Sci)* 2014;14(11):1917-1920

### INTRODUCTION

Idiopathic macular hole (IMH) was first described in 1869 by Knapp<sup>[1]</sup>. It has long been known as important cause of decreased central vision. In general, IMH occurs in women with increased incidence over 55 years old. Recent clinical observations have assembled lots of data discussing its formation and natural history<sup>[2-4]</sup>. There has been indicated an association between posterior vitreous detachment and early stages of full thickness IMH<sup>[4-7]</sup>.

Fellow eyes of patients with IMH can be affected in 13% during first 5y and 27% through 10y<sup>[8-12]</sup>. In the past, early diagnosis of IMH was a challenge for retinal specialists. Optical coherence tomography (OCT) has changed this scenario by

offering extremely refined and detailed images of retinal architecture and thickness; therefore an earlier diagnosis is possible<sup>[13-16]</sup>. The new generation of spectral-domain optical coherence tomography (SD-OCT) is capable to provide additional information of vitreoretinal microanatomical and structural changes during IHM formation, progression and surgical treatment<sup>[17-19]</sup>.

Unfortunately, the whole pathophysiology of IHM formation remains uncertain. Since Gass<sup>[20]</sup>, antero-posterior and tangential vitreomacular traction associated with posterior vitreous detachment and central cystic degeneration are part of the theory most accepted among retina specialists<sup>[5,7,9,12,15,16,21]</sup>. In this report, a new foveal configuration measurement in fellow eyes of patients with IMH is described and compared with healthy subjects using SD-OCT.

**SUBJECTS AND METHODS**

This is a retrospective study of 50 eyes of 50 patients at Ocular Surgery Center in Sao Paulo, Brazil. SD-OCT images were reviewed and analyzed from 2008 to 2011. Patients with IMH and healthy subjects were enrolled, group 1 (n = 25) and group 2 (n=25), respectively. All scans were acquired using RTVue 100 (Optovue, Inc., Fremont, CA, USA). OCT standard scan protocol was performed, including 3D scans, cross line and MM5. Statistical analysis was performed using t-test and covariance test (ANCOVA), in order to adjust age differences between study group and control group.

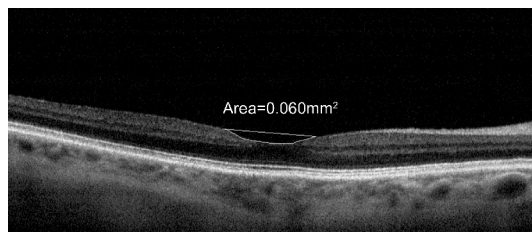
**Inclusion and Exclusion Criteria** For group 1, patients with IMH and healthy fellow eyes were selected. For group 2, only healthy individuals were enrolled. Patients with any of the following were excluded from the study: prior vitreomacular surgery and/or macular focal laser, secondary macular hole, partial vitreous detachment, epiretinal membrane, pseudohole, vitreomacular traction syndrome, high myopia (i.e. >6.0D), age-related macular degeneration, diabetic and/or hypertensive retinopathy, glaucoma, macular edema, any other vitreomacular disease.

**Foveal Configuration Measurements** Bi-dimensional foveal configuration was measured in mm<sup>2</sup> using manual caliper tool. The widest foveal B-scan was selected on each eye (Figures 1 and 2). All SD-OCT images were randomized and each measurement was performed three times by same observer and the mean foveal configuration was analyzed and compared in between groups.

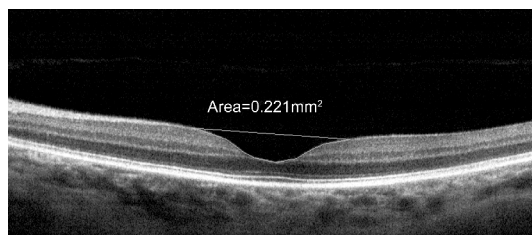**RESULTS**

Fifty eyes of fifty patients were included in the study, 33 individuals were women (66%). Twenty-five patients had IMH and twenty-five patients were healthy subjects (control group). The mean age was 68.8±7.12 and 53.8±14.76 years old, respectively.

Table 1 shows demographics, eye enrolled and mean SD-OCT foveal measurements in mm<sup>2</sup> for IMH group. Table 2 shows equal parameters of control group. Regarding mean foveal configuration measurements, fellow eyes of IMH group had a mean foveal configuration of 0.159 ±0.03mm<sup>2</sup> when compared



**Figure 1** SD-OCT foveal configuration measurement in mm<sup>2</sup>: healthy subject.



**Figure 2** SD-OCT foveal configuration measurement in mm<sup>2</sup>: fellow eye of patient with IMH.

**Table 1** Demographics, foveal configuration measurement of fellow eyes of patients with idiopathic macular hole

Patients' characteristics		SD-OCT measurements	
Group 1: Fellow eye of patients with IMH	Age (a)	Eye	Mean foveal configuration (mm <sup>2</sup> )
1	69	OE	0.116
2	68	OD	0.210
3	65	OD	0.191
4	73	OE	0.160
5	78	OE	0.179
6	73	OE	0.184
7	66	OE	0.218
8	66	OE	0.129
9	64	OE	0.143
10	65	OD	0.158
11	74	OD	0.152
12	66	OD	0.126
13	58	OE	0.114
14	70	OE	0.165
15	64	OE	0.135
16	78	OE	0.134
17	75	OE	0.158
18	60	OE	0.178
19	60	OE	0.179
20	62	OD	0.210
21	67	OD	0.138
22	91	OD	0.146
23	70	OD	0.137
24	63	OD	0.136
25	69	OD	0.172

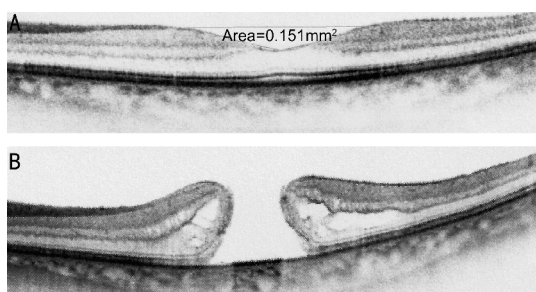
to control group that had a mean foveal configuration of 0.079 ± 0.01mm<sup>2</sup>, P value <0.001 (Table 3). After covariance analysis adjustments, mean fovea configurations were different regardless age differences between groups [F (1.47)= 113.17].

**Table 2 Demographics, foveal configuration measurements of healthy subjects**

Patient's characteristics		SD-OCT measurement	
Group 2: Control group	Age (a)	Eye	Mean foveal configuration (mm <sup>2</sup> )
1	63	OD	0.061
2	55	OD	0.076
3	62	OE	0.100
4	45	OE	0.059
5	34	OE	0.079
6	65	OD	0.101
7	76	OD	0.085
8	68	OE	0.099
9	64	OE	0.085
10	28	OD	0.095
11	28	OE	0.086
12	28	OD	0.088
13	28	OE	0.095
14	56	OE	0.078
15	68	OD	0.060
16	68	OE	0.063
17	59	OD	0.096
18	59	OE	0.076
19	62	OD	0.068
20	62	OE	0.076
21	55	OE	0.056
22	55	OD	0.083
23	36	OE	0.085
24	60	OD	0.063
25	62	OE	0.066

**Table 3 Mean total foveal configuration in mm<sup>2</sup>, group 1 and group 2**

Parameters	Mean foveal configuration (mm <sup>2</sup> )	P
Group 1 (n=25) Fellow eyes of IHM patients	0.159 (±0.03)	<0.001
Group 2 (n=25) Healthy subjects	0.079 (±0.01)	



**Figure 3 Fellow eye SD-OCT of patient 11** A: Bi-dimensional SD-OCT foveal configuration measurement in mm<sup>2</sup>; B: IMH.

**DISCUSSION**

Our study adds a new imaging tool to measure anatomic foveal configuration. It may help us understand the possible

microanatomical risk factor associated with IHM formation besides vitreomacular traction. The pathophysiology of IMH has been strongly discussed but it remains unclear. Some studies suggested that bilateral IHM could occur probably due to vitreoretinal anatomical and/or structural changes that are not yet identified. Since Gass and Johnson's<sup>[22]</sup> theory, some other authors have considered vitreous traction as the most important factor in IHM physiopathology<sup>[9,23]</sup>. However, a combination of factors is believed to be associated with its formation such as tangential vitreous traction as well as foveal cystic degeneration<sup>[12,24]</sup>.

SD-OCT has brought us new observations in retina anatomy. The development of high-quality and detailed images allowed us to complete study foveal microstructure<sup>[9]</sup>. Gentile studied serial OCTs with dynamic visualization of IMH anatomic changes during its progression. The morphing videos helped him to confirm an initial event of antero-posterior traction followed by a defect in the internal limiting membrane (ILM) that contributed to macular hole formation. Nevertheless, Barak *et al*<sup>[24]</sup> described a subgroup of patients (43%) with total posterior vitreous detachment that developed full thickness IMH after a period of time and they also presented a different OCT foveal configuration when compared to healthy subjects. Authors believe that an abnormal foveal configuration occurs before loss of foveal contour and it can play a role in the IMH development without necessarily being caused by vitreomacular traction.

In our study, we measured the foveal configuration of healthy fellow eyes of patients with IMH and compared with healthy individuals after correcting age difference between groups. It is the first description of measurements of foveal pit using SD-OCT manual caliper tool. Some studies have reported a dehiscent or weakened central foveal configuration as a primary event associated with Müller and glial cells proliferation followed by abnormal vitreous adherence and local traction<sup>[8,9]</sup>. We found only one patient of the study group that developed macular hole in the fellow eye (Figure 3). It may reinforce the influence of this additional factor for IMH formation, however this theory needs to be confirmed with further studies that may help to add a pre-stage to IMH classification, helping retinal specialists to screen patients with higher risk to develop macular hole if they already have or not other vitreomacular factors identified by SD-OCT.

Our results raise a new point of discussion: foveal microanatomic changes may appear earlier in IHM formation or an enlarged fovea can enhance the chance of macular hole formation, if it is associated with other vitreomacular risk factors (*i.e.* partial posterior vitreous detachment with foveal traction, foveal cyst and epiretinal membrane). Limitations of our study include a small number of subjects, short-time observation and its retrospective nature. We are conscious of other risk factors involved in IMH formation, however bilateral IMH have been described as higher as 22%<sup>[3]</sup>. Further large prospective study with serial OCT images over time in fellow eyes of patients with IMH may help us to clarify this new concept.

Finally, foveal configuration in fellow eyes of patients with IMH tends to be greater than healthy eyes. An enlarged fovea combined with well-known risk factors may play role in IMH development. In the past, earlier diagnosis of IMH was a great challenge in daily practice. Currently, SD-OCT has offered diagnostic capability to help with better assessment and follow-up of these patients allowing detailed evaluation of foveal anatomy and structure.

In conclusion, few IMH studies have assessed foveal morphology in IHM formation<sup>[4,7,21,24,25]</sup> but none of these has considered the correlation between an enlarged fovea measured by SD-OCT and a greater risk for developing IMH. Differences in foveal configuration in fellow eyes of patients with IMH was first described in this study and was found to be significantly wider than normal subjects. Further studies are needed to better assess this theory.

#### REFERENCES

- 1 Knapp H. Über isolirte zerreibungen der aderhaut in folge von traumen auf dem augapfel, Arch Augenheilk. 1896;1:6-29
- 2 Kim JW, Freeman WR, el-Haig W, Maguire AM, Arevalo JF, Azen SP. Baseline characteristics, natural history, and risk factors to progression in eyes with stage 2 macular holes. Results from a prospective randomized clinical trial. Vitrectomy for Macular Hole Study Group. *Ophthalmology* 1995;102(12):1818-1828; discussion 1828-1829
- 3 Bronstein MA, Trempe CL, Freeman HM. Fellow eyes of eyes with macular holes. *Am J Ophthalmol* 1981;92(6):757-761
- 4 Chan A, Duker J, Schuman JS, Schuman JS, Fujimoto JG. Stage 0 macular holes: observations by optical coherence tomography. *Ophthalmology* 2004;111(11):2027-2032
- 5 Chauhan DS, Antcliff RJ, Rai PA, Williamson TH, Marshall J. Papillofoveal traction in macular hole formation: the role of optical coherence tomography. *Arch Ophthalmol* 2000;118(1):32-38
- 6 Johnson M, Van Newkirk M, Meyer KA. Perifoveal vitreous detachment is the primary pathogenic event in idiopathic macular hole formation. *Arch Ophthalmol* 2001;119(2):215-222
- 7 Spaide RF, Wong D, Fisher Y, Goldbaum M. Correlation of vitreous attachment and foveal deformation in early macular hole states. *Am J Ophthalmol* 2002;133(2):226-229
- 8 Lewis ML, Cohen SM, Smiddy WE, Gass JD. Bilaterality of idiopathic macular holes. *Graefes Arch Clin Exp Ophthalmol* 1996;234(4):241-245
- 9 Smiddy WE, Flynn HW Jr. Pathogenesis of macular holes and therapeutic implications. *Am J Ophthalmol* 2004;137(3):525-537
- 10 Ezra E, Wells JA, Gray RH, Kinsella FM, Orr GM, Grego J, Arden GB, Gregor ZJ. Incidence of idiopathic full-thickness macular holes in fellow eyes. A 5-year prospective natural history study. *Ophthalmology* 1998;105(2):353-359

- 11 Kumagai K, Ogino N, Hangai M, Larson E. Percentage of fellow eyes that develop full-thickness macular hole in patients with unilateral macular hole. *Arch Ophthalmol* 2012;130(3):393-394
- 12 Ho AC, Guyer DR, Fine SL. Macular hole. *Surv Ophthalmol* 1998;42(5):393-416
- 13 Azzolini C, Patelli F, Brancato R. Correlation between optical coherence tomography data and biomicroscopic interpretation of idiopathic macular hole. *Am J Ophthalmol* 2001;123(3):348-355
- 14 Altaweel M, Ip M. Macular hole: improved understanding of pathogenesis, staging, and management based on optical coherence tomography. *Semin Ophthalmol* 2003;18(2):58-66
- 15 Gaudric A, Haouchine B, Massin P, Paques M, Blain P, Erginay A. Macular hole formation: new data provided by optical coherence tomography. *Arch Ophthalmol* 1999;117(6):744-751
- 16 Michalewska Z, Michalewski J, Sikorski BL, Kałuzny JJ, Wojtkowski M, Adelman RA, Nawrocki J. A study of macular hole formation by serial spectral optical coherence tomography. *Clin Experiment Ophthalmol* 2009;37(4):373-383
- 17 Drexler W, Sattmann H, Hermann B, Ko TH, Stur M, Unterhuber A, Scholda C, Findl O, Wirtitsch M, Fujimoto JG, Fercher AF. Enhanced visualization of macular pathology with the use of ultrahigh-resolution optical coherence tomography. *Arch Ophthalmol* 2003;121(5):695-706
- 18 Takahashi A, Yoshida A, Nagaoka T, Takamiya A, Sato E, Kagokawa H, Kameyama D, Sogawa K, Ishiko S, Hirokawa H. Idiopathic full-thickness macular holes and the vitreomacular interface: a high-resolution spectral-domain optical coherence tomography study. *Am J Ophthalmol* 2012;154(5):881-892. e2
- 19 Ooka E, Mitamura Y, Baba T, Kitahashi M, Oshitari T, Yamamoto S. Foveal microstructure on spectral-domain optical coherence tomographic images and visual function after macular hole surgery. *Am J Ophthalmol* 2011;152(2):283-290. e1
- 20 Gass JD. Reappraisal of biomicroscopic classification of stages of development of a macular hole. *Am J Ophthalmol* 1995;119(6):752-759
- 21 Besirli CG, Johnson MW. Traction-induced foveal damage predisposes eyes with pre-existing posterior vitreous detachment to idiopathic macular hole formation. *Eye (Lond)* 2012;26(6):792-795
- 22 Johnson RN, Gass JD. Idiopathic macular holes. Observations, stages of formation, and implications for surgical intervention. *Ophthalmology* 1988;95(7):917-924
- 23 Gentile RC, Landa G, Pons ME, Elliott D, Rosen RB. Macular hole formation, progression, and surgical repair: case series of serial optical coherence tomography and time lapse morphing video study. *BMC Ophthalmol* 2010;10:24
- 24 Barak Y, Sherman MP, Schaal S. Mathematical analysis of specific anatomic foveal configurations predisposing to the formation of macular holes. *Invest Ophthalmol Vis Sci* 2011;52(11):8266-8270
- 25 Kumagai K, Hangai M, Larson E, Ogino N. Foveal thickness in healthy fellow eyes of patients with unilateral macular holes. *Am J Ophthalmol* 2013;156(1):140-148