

Surgical staging as a therapy for retinopathy of prematurity

Jun Yu, Qi Zhang, Yu Xu, Ping Fei, Pei-Quan Zhao, Xiao-Li Kang

Foundation item: National Natural Science Foundation of China (No. 81200703)

Department of Ophthalmology, Xinhua Hospital Affiliated to Shanghai Jiao Tong University School of Medicine, Shanghai 200092, China

Co-first authors: Jun Yu and Qi Zhang

Correspondence to: Pei - Quan Zhao; Xiao - Li Kang. Department of Ophthalmology, Xinhua Hospital Affiliated to Shanghai Jiao Tong University School of Medicine, No. 1665 Kongjiang Road, Shanghai 200092, China. zhaopeiquan2011@126.com; kangxiaoli2013@126.com

Received: 2014-04-17 Accepted: 2015-01-12

治疗早产儿视网膜病变的一种新思路:分期手术

于军,张琦,许宇,费萍,赵培泉,亢晓丽

基金项目:国家自然科学基金项目(No. 81200703)

(作者单位:200092 中国上海市,上海交通大学医学院附属新华医院眼科)

作者简介:于军,毕业于上海交通大学,博士,主治医师,研究方向:斜,弱视,屈光不正及儿童眼部的诊断治疗;张琦,毕业于上海交通大学,硕士,副主任医师,研究方向:玻璃体、视网膜疾病。

通讯作者:赵培泉,毕业于上海复旦大学,博士,主任医师,博士生导师,眼科主任。研究方向:玻璃体、视网膜疾病,专长复杂性眼底疾病显微手术,以及白内障超声乳化和玻璃体视网膜病变的联合手术。zhaopeiquan2011@126.com; 亢晓丽,毕业于中国医科大学,博士,主任医师,硕士生导师,眼科副主任,研究方向:斜视,弱视,屈光不正及儿童眼部的诊断治疗。kangxiaoli2013@126.com

引用:于军,张琦,许宇,费萍,赵培泉,亢晓丽. 治疗早产儿视网膜病变的一种新思路:分期手术. 国际眼科杂志 2015; 15(3): 396-397

DOI:10.3980/j.issn.1672-5123.2015.3.04

Citation: Yu J, Zhang Q, Xu Y, Fei P, Zhao PQ, Kang XL. Surgical staging as a therapy for retinopathy of prematurity. *Guoji Yanke Zazhi(Int Eye Sci)* 2015;15(3):396-397

Dear Sir,

We are Dr. Yu J, and Dr. Zhang Q, from Department of Ophthalmology, Xinhua Hospital Affiliated to Shanghai Jiao Tong University School of Medicine, Shanghai, China. We write to present a case report of a novel therapy concept: staged surgery as a therapy for retinopathy of prematurity (ROP).

ROP is a neovascular retinal disorder. It can affect the vision of infants of low birth weight and young gestational age. Serious ROP can progress to childhood loss of vision, even

blindness. Consequently, early screening and therapy are curial for infants with a low birth weight.

However, when the retinas of these infants begin to detach and/or progress to stage 4 or 5, surgical interventions are the only effective choice for retinal reattachment and foveal formation.

ROP can be categorized according to the international classification of retinopathy of prematurity revisited. In brief, this ROP classification includes the following stages: stage 1, demarcation line; stage 2, ridge; stage 3, extraretinal fibrovascular proliferation; stage 4, partial retinal detachment; and stage 5, total retinal detachment^[1].

The current surgical operation for stage 4 or 5 ROP includes vitrectomy with or without lensectomy^[2-4]. There are several potential complications during these stages, such as corneal opacity, the disappearance of anterior chamber, occlusion of the pupil and secondary glaucoma, all of which could increase the difficulty of the operations or even cause them to fail. Based on our previous clinical experience, we have attempted to apply a novel therapy concept, staged surgery, to improve the chance of success. Following out clinical observations, we believe that this type of surgical method could be used to help treat stage 4 or 5 ROP.

The patient was a female infant who was born at 28wk gestation and at a birth weight of 1800 g^[2]. The baby was 2 months old and weighed 5000 g when she was first taken to see the doctor on this condition. She was screened for stage 5 ROP following a clinical evaluation. Her symptoms included corneal opacity, anterior chamber disappearance and retinal detachment. The baby was submitted to surgery after obtaining informed consent from her parents. The ophthalmologist implemented the surgical therapy in two steps. Stage 1 surgery included closed lensectomy and was associated with anterior vitrectomy. Stage 2 surgery included closed vitrectomy. During stage 1 surgery, three limbal paracentesis procedures were applied at the 8:00, 10:00 and 2:00 positions. Viscoelastic substance was injected to achieve separation of the pupil adhesion, and remove then. The lens and anterior vitreous were then removed by vitreous cutter (Figure 1). Medication was administered to maintain the retina following the stage 1 surgery. A local application of glucocorticoid ophthalmic ointment or eye drops, such as Tobradex[®] or Pred Forte[®], or intravitreal injection, such as ranibizumab (Lucentis[®]) or triamcinolone acetonide, was applied to maintain the retina^[5,6]. Nearly 1mo later, the cornea of the infant became transparent, and the intraocular vascular activity subsided. These events signaled the time for stage 2

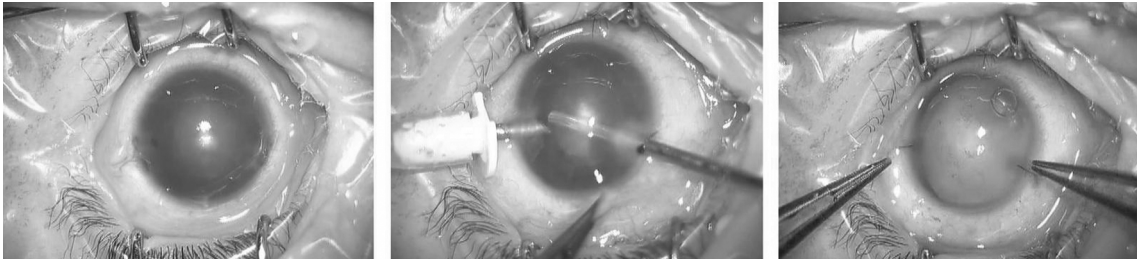


Figure 1 Procedures of stage 1 surgery.

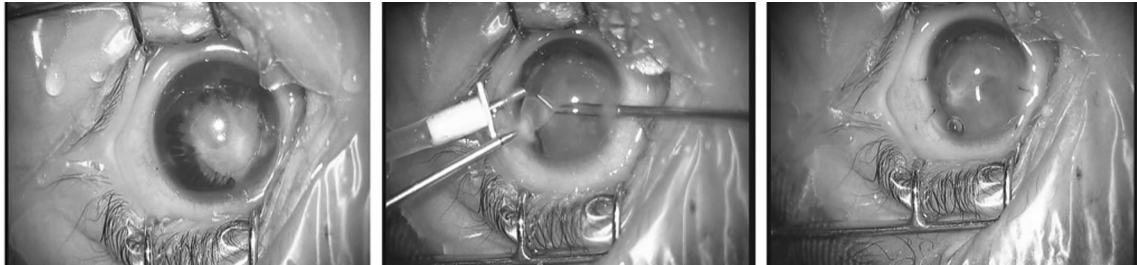


Figure 2 Procedures of stage 2 surgery.

surgery: closed vitrectomy. The proliferative membranes and the residual vitreous were removed. Viscoelastics were also injected to achieve retinal reattachment (Figure 2).

In premature infants, the neural retina and retinal vasculature are immature. After the birth of these infants, retinal development becomes overactive. Furthermore, the intake of high-concentration oxygen could accelerate this symptom^[7,8]. More severe manifestations of these diseases include neovascularization and subretinal/intraretinal hemorrhage exudate. The vascularized preretinal membranes that can give rise to a series of diseases, such as retinal folds, macular ectopia, retinal detachment, secondary glaucoma and the anterior chamber missing. Surgery is the only method available to treat these serious symptoms. Based on our pre-clinical research, we found that vitrectomy was hard to perform successfully because of these complications. As a result, we attempted to implement the operation in two steps. The first step involves “saving” the cornea. During stage 1 surgery, we only cut the lens and anterior vitreous to reconstruct the anterior chamber. After this operation, pharmacotherapy was applied. We frequently use a local application of glucocorticoid ophthalmic ointment or eye drops, such as TobraDex® or Pred Forte®, or an intravitreal injection, such as ranibizumab (Lucentis®) or triamcinolone acetonide, to maintain the retina after stage 1 surgery^[7,8]. The ophthalmologist must check the infant regularly during this time. The medications help treat retinal anti-angiogenesis. This process usually continues for one or two months. When the retina transitions from “active” to “inactive,” it is time for stage 2 surgery. Currently, many ophthalmologists agree that lens-sparing vitrectomy fails to prevent the progression of retinal detachment in cases of aggressive posterior ROP due to insufficient removal of the vitreous gel at the vitreous base, compared with lensectomy with vitrectomy in which the gel is completely removed^[9,10].

Furthermore, advanced ROP can involve serious complications,

such as corneal opacity, anterior chamber disappearance, occlusion of the pupil, secondary glaucoma, or intraocular vascular activity that has not yet subsided. All these complications increase the difficulty of surgery. Vitrectomy with lensectomy is less prone to failure due to surgical damage and complications. Consequently, the choice of surgical timing and method are critical.

Compared with the formerly applied methods, we believe that staged surgery is an appropriate choice for the treatment of advanced ROP.

REFERENCES

- 1 International Committee for the Classification of Retinopathy of Prematurity. The International Classification of Retinopathy of Prematurity revisited. *Arch Ophthalmol* 2005;123(7):991-999
- 2 Mota A, Carneiro A, Breda J, Rosas V, Magalhães A, Silva R, Falcão-Reis F. Combination of intravitreal ranibizumab and laser photocoagulation for aggressive posteriorretinopathy of prematurity. *Case Rep Ophthalmol* 2012;3(1):136-141
- 3 Mandal K, Drury JA, Clark DI. An unusual case of retinopathy of prematurity. *J Perinatol* 2007;27(5):315-316
- 4 Nishina S, Suzuki Y, Yokoi T, Kobayashi Y, Noda E, Azuma N. Clinical features of congenital retinal folds. *Am J Ophthalmol* 2012;153(1):81-87. e1
- 5 Shah PK, Narendran V, Kalpana N. Triamcinolone acetonide-assisted vitrectomy for stage 4 retinopathy of prematurity. *Int Ophthalmol* 2011;31(3):237-238
- 6 Sallam A, Comer R, Chang J, Grigg J, Andrews R, McCluskey P, Lightman S. Short-term safety and efficacy of intravitreal triamcinolone acetonide for uveitic macular edema in children. *Arch Ophthalmol* 2008;126(2):200-205
- 7 Fulton A, Hansen R, Moskowitz A, Akula J. The neurovascular retina in retinopathy of prematurity. *Prog Retin Eye Res* 2009;28(6):452-482
- 8 Afzal A, Shaw L, Ljubimov A, Boulton M, Segal M, Grant M. Retinal and choroidal microangiopathies; therapeutic opportunities. *Microvasc Res* 2007;74(2-3):131-144
- 9 Azuma N, Ishikawa K, Hama Y, Hiraoka M, Suzuki Y, Nishina S. Early vitreous surgery for aggressive posterior retinopathy of prematurity. *Am J Ophthalmol* 2006;142(4):636-643
- 10 Fei P, Zhao PQ, Chen RJ, Yu Z. Histopathological study of epiretinal membranes in retinopathy of prematurity. *Zhonghua Yan Ke Za Zhi* 2008;44(7):629-633