

Influence of pars plana vitrectomy on ocular surface using noninvasive Keratograph 5M

Ling-Ling Fan¹, Shi-Jian Fan², Jian Gao¹, Lun Liu¹, Rong-Feng Liao¹

引用: 范玲玲, 范仕剑, 高健, 刘伦, 廖荣丰. Keratograph 5M 评估玻璃体切除手术对眼表的影响. 国际眼科杂志 2020; 20(11): 1847-1852

Foundation items: Anhui Natural Science Foundation Youth Project (No.1908085QH381); The First Affiliated Hospital of Anhui Medical University Training Program of National Natural Science Foundation for Young Scientists (No. 2017kj26)

¹Department of Ophthalmology, the First Affiliated Hospital of Anhui Medical University, Hefei 230022, Anhui Province, China

²Department of Laboratory, the First Affiliated Hospital of Anhui Medical University, Hefei 230022, Anhui Province, China

Correspondence to: Lun Liu. Department of Ophthalmology, the First Affiliated Hospital of Anhui Medical University, Hefei 230022, Anhui Province, China. 1054789268@qq.com; Rong-Feng Liao. Department of Ophthalmology, the First Affiliated Hospital of Anhui Medical University, Hefei 230022, Anhui Province, China. liaorfayyk@126.com

Received: 2019-10-29 Accepted: 2020-06-22

Keratograph 5M 评估玻璃体切除手术对眼表的影响

范玲玲¹, 范仕剑², 高健¹, 刘伦¹, 廖荣丰¹

基金项目: 安徽省自然科学基金青年项目 (No.1908085QH381); 安徽医科大学第一附属医院国家自然科学基金青年培育项目 (No.2017kj26)

(作者单位: 230022 中国安徽省合肥市, 安徽医科大学第一附属医院¹眼科; ²实验室)

作者简介: 范玲玲, 毕业于天津医科大学, 博士, 主治医师, 讲师; 研究方向: 眼底病, 眼外伤。

通讯作者: 刘伦, 安徽医科大学, 博士, 副主任医师, 讲师, 研究方向: 眼底病. 1054789268@qq.com; 廖荣丰, 安徽医科大学, 博士, 主任医师, 教授, 博士生导师, 研究方向: 白内障, 眼表疾病. liaorfayyk@126.com

摘要

目的: 该研究旨在应用 Keratograph 5M 评估玻璃体切除手术 (PPV) 对眼表的影响。

方法: 本研究纳入 23G 玻璃体切除手术的患者 30 例 30 眼。分别于手术前、手术后 1、2、4、8 及 12wk 行眼表疾病指数 (OSDI) 问卷评分, 采集眼表参数包括泪河高度

(TMH)、非侵入性泪膜破裂时间 (NITBUT) 和眼红指数, 并进一步分析各临床参数之间的相关性。

结果: 玻璃体切除术后 4wk 内, 畏光、异物感较术前显著增加, 但是手术后 8、12wk 降至术前水平; 术后 1wk 眼胀不适较前显著增加, 但术后 2、4、8 及 12wk 与术前无显著差异。OSDI 评分在术后 4wk 内显著增加, 但在术后 8wk 及 12wk 降至术前水平。TMH 在术后 2wk 较前增高, 但与术前相比差异无统计学意义。首次 NITBUT 和平均 NITBUT 在术后 8wk 内显著缩短, 但术后 12wk 延长至术前水平。眼红指数在术后 4wk 内显著增加, 但术后 8wk 降至术前水平。首次 NITBUT 和平均 NITBUT 在每次随访时间点均呈显著正相关, TMH 与平均 NITBUT 在术后 1wk 呈显著正相关。

结论: Keratograph 5M 可作为评估玻璃体切除手术对眼表影响的一种可靠方法。玻璃体切除手术可引起早期眼表症状及体征的改变, 但是这些改变在手术后 12wk 内将逐渐恢复到术前水平。

关键词: 眼表综合分析仪; 泪膜; 玻璃体切除手术; 干眼综合征

Abstract

• **AIM:** To evaluate the influence of pars plana vitrectomy (PPV) on ocular surface using Keratograph 5M.

• **METHODS:** Totally 30 consecutive patients (30 eyes) undergoing primary 23G PPV were recruited in the study. Ocular Surface Disease Index (OSDI) questionnaire was performed. Ocular surface parameters, including tear meniscus height (TMH), noninvasive tear break up time (NITBUT) and bulbar redness score were obtained preoperatively, in 2, 4, 8 and 12wk postoperatively by Keratograph 5M. Correlations between all the clinical parameters were analyzed further.

• **RESULTS:** The percentages of both photophobia and gritty within 4wk after PPV were significantly higher than preoperation, while they decreased to the preoperative levels in both 8wk and 12wk postoperatively. The percentage of sore eyes in the first week postoperatively was significantly higher than preoperation, but there were no significant differences between the percentages of preoperation and 2, 4, 8 and 12wk postoperatively. OSDI score increased significantly within 4wk postoperatively, but it returned to the preoperative level in 8 and 12wk. TMH increased with 2wk postoperatively, but there were no significant differences compared with preoperation. Both NITBUT - first and NITBUT - average shortened significantly within 8wk postoperatively, but they gradually improved to the preoperative levels in 12wk.

Bulbar redness score was significantly higher than the preoperative level within 4wk postoperatively, but it returned to the preoperative level in 8wk. NITBUT–first and NITBUT–average had a significant positive correlation at each visit. TMH had a significant positive correlation with NITBUT–average in the first week postoperatively.

• **CONCLUSION:** Keratograph 5M can provide a reliable noninvasive method to assess the influence of PPV on the ocular surface. PPV may cause various changes in both symptoms and signs of ocular surface damages at the early stage, while all these changes will return to preoperative levels gradually in 12wk postoperatively.

• **KEYWORDS:** Keratograph; tear film; pars plana vitrectomy; dry eye syndrome

DOI:10.3980/j.issn.1672-5123.2020.11.02

Citation: Fan LL, Fan SJ, Gao J, Liu L, Liao RF. Influence of pars plana vitrectomy on ocular surface using noninvasive Keratograph 5M. *Guoji Yanke Zazhi (Int Eye Sci)* 2020; 20(11): 1847–1852

INTRODUCTION

Pars plana vitrectomy (PPV) was first introduced as a new treatment for vitreoretinal diseases by Robert Machemer in 1971. With the evolution and development of vitrectomy machines and related instruments, surgical techniques have been improved and the application of PPV has increased significantly in recent years. However, many patients undergoing PPV have complained of dry eye–related irritative symptoms postoperatively.

Dry eye syndrome is a multifactorial disease of tears and ocular surface due to tear deficiency and over evaporation, which can be caused by many complex factors, including inflammation, hyperosmolarity of tears, and neurosensory abnormalities, as well as unstable tear films^[1-2]. It leads to ocular discomfort and visual impairment, which can impact the quality of life greatly^[3]. Bulbar redness, or conjunctival hyperemia, is a non–specific ocular response due to multiple ocular surface disorders, including conjunctivitis, anterior eye inflammation, contact lens wear and dry eye syndrome. There are also many reports about the influence of surgical interventions on the ocular surface, such as corneal refractive surgery^[4], cataract surgery^[5] and glaucoma surgery^[6]. Evaluation of tear film and bulbar redness may help us to know the surgery–induced ocular surface changes and guide appropriate treatments. Nevertheless, the influence of PPV on ocular surface is poorly understood so far.

Traditional methods evaluating dry eye have been widely used in clinical practice, including Schirmer test and fluorescein tear break up time (TBUT). However, these invasive examinations are subjective, difficult, and time–consuming, which need patients to cooperate very well. Additionally, these invasive examinations have been shown to have poor accuracy and reproducibility. The noninvasive Keratography 5M, advanced Placido topography, provides reliable objective measurements of ocular surface parameters including tear

meniscus height (TMH), noninvasive TBUT (NITBUT), and bulbar redness score, with acceptable repeatability and reproducibility^[7-8]. It has been used in the evaluation of ocular surface in recent years, especially the diagnosis of dry eye. In this study, we used the Keratograph 5M (Oculus Optikgeräte GmbH, Wetzlar, Germany) to evaluate the changes of ocular surface after PPV, which is beneficial to manage PPV induced ocular surface damages.

SUBJECTS AND METHODS

Participants This prospective, descriptive study was approved by the Ethics Committee of the First Hospital Affiliated of Anhui Medical University and followed the tenets of the Declaration of Helsinki. Informed consent was obtained from all individual participants included in the study. From April 2018 to October 2018, a total of 30 eyes from 30 consecutive patients who underwent primary 23G PPV in our hospital were recruited. Their age ranged from 43–75 years with a mean of 59.33±7.68 years. Half of them were male and the other half were female. All the patients were followed up for 3mo. Exclusion criteria were: 1) age ≤18 or ≥75 years; 2) any eye diseases influencing ocular surface (*e.g.* keratoconjunctivitis, ectropion, hypophthalmos or glaucoma); 3) history of ocular injury or other ocular surgery within 6mo; 4) use of topical ocular medications influencing ocular surface within one week before the operation; 5) any other drugs used for postoperative complications during the follow–up period; 6) the follow–up period less than 3mo.

Surgical Techniques The three–port conventional 23G PPV was done in all the 30 eyes by a single vitreoretinal surgeon under retrobulbar anesthesia induced with 0.1% Ropivacaine hydrochloride. During the surgery, blood, anterior–posterior traction, fibrovascular tissues and membranes were removed as completely and safely as possible. For the patients with macular hole, internal limiting membranes stained with indocyanine green were peeled to at least one disc diameter from the edge of the hole. Endolaser photocoagulation or retinal cryotherapy was done for sealing the retinal hole. Filtered air or silicone oil was used as intraocular tamponade if necessary. After removal of the cannula from the ports, sclerotomies were sutured with 8.0 absorbable sutures (VICRYL™, W9560) and the ports were checked for leakages. After surgery, all the patients with intraocular air or silicone oil tamponade were instructed to maintain a prone position to achieve better effects. Additionally, all patients were given topical eye drops of tobramycin–dexamethasone (TobraDex, Alcon) and pranoprofen (Pranopulin, Senju) four times daily for 1mo, and tropicamide–phenylephrine (Mydrin–P, Santen) was used twice daily for 2wk.

Ocular Surface Disease Index Questionnaire for Ocular Symptoms Subjective symptoms of ocular irritation were assessed by the 12–item OSID questionnaire. We modified the questionnaire by deleting the 4 and 5 items, which assess the existence of blurred and poor vision. Because it was difficult to distinguish the change of these symptoms caused by PPV alone

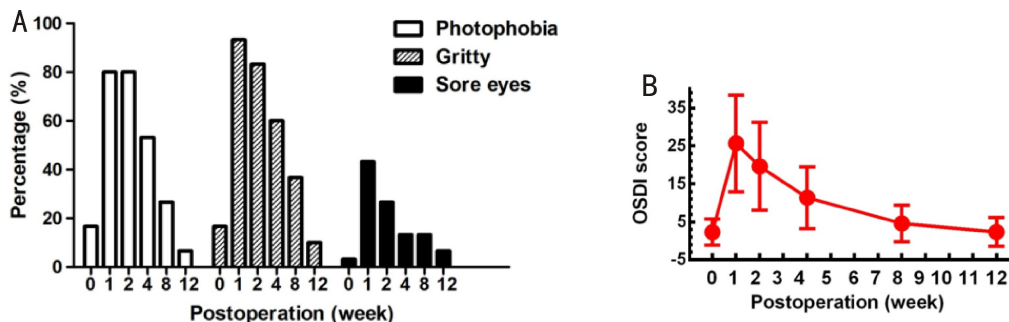


Figure 1 Changes of ocular surface symptoms and OSDI scores A: Changes in the distribution of photophobia, gritty and sore eyes; B: Change in OSDI score.

Table 1 Clinical parameters of preoperation and each visit postoperatively (mean±SD, n=30)

Clinical parameters	Baseline	1wk	2wk	4wk	8wk	12wk
OSDI score	2.3±3.44	25.69±12.74	19.62±11.57	11.39±8.12	4.64±4.81	2.36±3.82
TMH (mm)	0.29±0.11	0.34±0.13	0.31±0.1	0.29±0.12	0.28±0.08	0.26±0.08
NITBUT-first (s)	12.11±3.28	4.58±1.7	6.52±2.58	8.86±2.82	10.65±2.8	12.46±3.11
NITBUT-average (s)	19.09±2.77	8.63±1.94	14.4±2.8	11.72±2.73	16.83±3.05	19.15±2.86
Bulbar redness score	1.66±0.5	2.69±0.74	2.24±0.67	1.98±0.65	1.71±0.47	1.57±0.43

OSDI: Ocular Surface Disease Index; TMH: Tear meniscus height; NITBUT: Noninvasive tear break up time.

or combined with PPV induced dry eye condition. OSDI score was calculated by the following formula; total points of all answered questions×100/total number of answered questions×4.

Keratography 5M Clinical examinations were all performed by the same ophthalmic technician using the Keratograph 5M under the manufacturer’s instructions. All the ocular surface parameters were obtained preoperatively, in 1wk, 2wk, 4wk, 8wk, and 12wk postoperatively. Additionally, all examinations were performed sequentially with 5min break as follows.

Tear Meniscus Height The subjects were instructed to look at a central target in the system and blink normally. The keratograph was set to “Tear film Scan (TF-Scan), tear meniscus” mode to capture an image of the ocular surface focused on the tear film following the manufacturer’s instructions as previously reported^[9]. The central MH was measured manually by cursors provided by the system.

Noninvasive Tear Break up Time Tear film stability was assessed in the “TF-Scan, NITBUT” mode. After manual focusing, the patients were asked to blink twice and then keep their eyes open as long as possible. At the same time, a video was recorded showing the presentation of tear film break up over time. The NITBUT-first and NITBUT-average were generated automatically. The simultaneous time of the tear film starts to break up was the NITBUT-first. NITBUT-average indicated the mean of all TBUTs occurring on the whole observed cornea.

Bulbar Redness Bulbar redness was measured in the “R-Scan” mode. Subjects were instructed to focus on the light target. Then image of exposed bulbar conjunctiva was captured manually and the redness score was generated automatically. The score was calculated based on the area percentage ratio between blood vessels and the rest of the analyzed bulbar

conjunctiva.

Statistical Analysis Statistical analysis was performed by SPSS 19.0 software. All values were expressed by mean ± standard deviation (SD). The Kolmogorov-Smirnov test was applied to test the normality of the data. One-way analysis of variance and paired *t*-test were used for comparing differences in all variables. Chi-square test was used to analyze the percentages. Correlations between all variables were tested using Pearson’s correlation test. *P* values less than 0.01 were considered statistically significant.

RESULTS

Ocular Surface Symptoms and OSDI score Most patients complained of ocular surface discomfort after PPV, mainly including photophobia, gritty and sore eyes. Distributions of these symptoms during the follow-up were shown in Figure 1A. The percentages of either photophobia or gritty increased significantly at 1wk, 2wk and 4wk postoperatively (*P*<0.001, *P*<0.001, *P*=0.003; *P*<0.001, *P*<0.001, *P*=0.001, respectively), while they decreased to the preoperative levels in both 8 weeks and 12wk postoperatively (*P*=0.347, *P*=0.228; *P*=0.08, *P*=0.448, respectively). The percentage of sore eyes in the first week postoperatively was significantly higher than preoperation (*P*<0.001), but there were no significant differences between the percentages of pre-operation and 2wk, 4wk, 8wk and 12wk postoperatively (*P*=0.011, *P*=0.161, *P*=0.161, *P*=0.554, respectively).

Table 1 showed the OSDI score at each visit and the change of OSDI score was shown in Figure 1B. Compared with the preoperative value, the OSDI scores were all significantly higher in 1wk, 2wk and 4wk postoperatively (*P*<0.001, *P*<0.001, *P*<0.001, respectively), while they decreased to the preoperative level in 8wk and 12wk postoperatively (*P*=0.024, *P*=1, respectively).

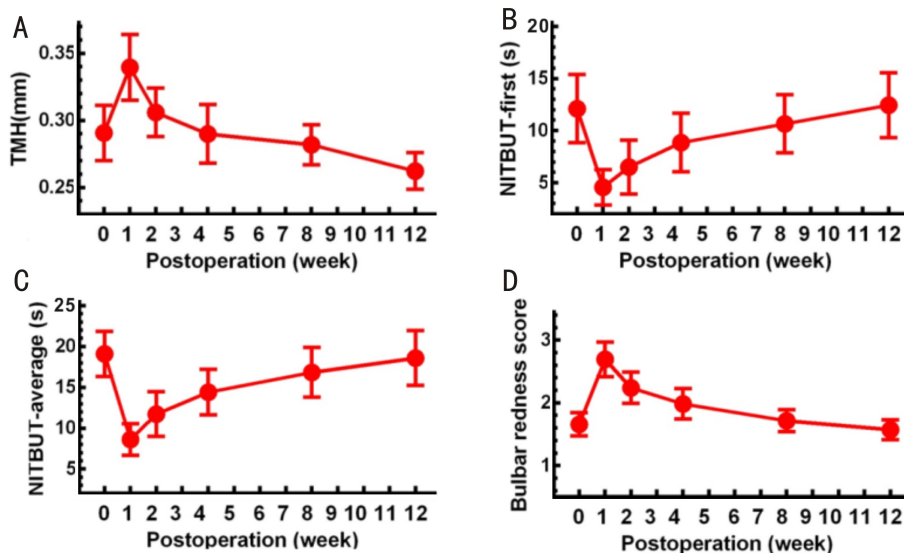


Figure 2 Changes of ocular surface parameters measured by Keratograph 5M A: Changes in TMH; B: Changes in NITBUT-first; C: Changes in NITBUT-average; D: Changes in Bulbar redness.

Ocular Surface Parameters Measured by Keratograph 5M

Table 1 summarized the ocular surface parameters at each visit, including TMH, NITBUT-first, NITBUT-average and bulbar redness score. In comparison with preoperative TMH, the values were higher within 2wk than preoperation, while there were no significant differences at every visit postoperatively ($P=0.012$, $P=0.336$, $P=0.665$, $P=0.508$, $P=0.088$, respectively). The change in TMH was shown in Figure 2A.

The change in NITBUT - first was shown in Figure 2B. NITBUT - first values in 1wk, 2wk, 4wk and 8wk postoperatively were all significantly lower than preoperation ($P<0.001$, $P<0.001$, $P<0.001$, $P<0.001$, respectively). However, there was no significant difference between the values in 12wk postoperatively and preoperation ($P=0.172$). Similar to the changes in NITBUT - first and OSDI score, NITBUT-average was significantly shortened after PPV, but gradually improved as time passed (Figure 2C). The values in 1wk, 2wk, 4wk and 8wk postoperatively were significantly lower than preoperation ($P<0.001$, $P<0.001$, $P<0.001$, $P<0.001$, respectively). However, the values were not significantly different between 12wks postoperatively and preoperation ($P=0.781$). The change in the bulbar redness score was shown in Figure 2D. The score was significantly higher in 1wk, 2wk and 4wk postoperatively than preoperation ($P<0.001$, $P<0.001$, $P<0.001$, respectively). However, compared to preoperation, there were no significant differences in both 8wk and 12wk postoperatively ($P=0.184$, $P=0.108$, respectively).

Correlations Between Clinical Parameters Correlations between all clinical parameters were analyzed. Significant positive correlation was found between NITBUT - first and NITBUT-average at each visit ($r = 0.548$, $P = 0.002$; $r = 0.586$, $P = 0.001$; $r = 0.58$, $P = 0.001$; $r = 0.587$, $P < 0.001$; $r = 0.634$, $P = 0.001$; $r = 0.584$, $P = 0.001$, respectively). In

addition to this, we also found that TMH had a significant positive correlation with NITBUT - average ($r = 0.49$, $P = 0.006$) in the first week postoperatively.

DISCUSSION

Compared with other traditional methods, Oculus Keratograph is a noninvasive and objective method to assess the ocular surface, which is more likely to be applied in clinical practice with high practicability. Many studies reported that the stability of ocular surface was damaged after some surgery, causing dry eye related symptoms and signs, such as photorefractive keratectomy, laser in situ keratomileusis, and cataract surgery. In this study, we analyzed the changes of ocular surface after PPV via OSDI questionnaire, and measuring TMH, NITBUT and bulbar redness via Keratograph 5M.

In the current study, we found many patients complained of eye discomfort, including photophobia and gritty, especially within 4wk postoperatively. Also, there were many patients complaining of sore eyes, especially in the first week. OSDI questionnaire was used to assess symptoms of ocular surface subjectively in our study, which is one of the most commonly used questionnaires to assess dry eye. Our results showed that OSDI score increased significantly within 4wk after PPV, and it returned to preoperative level in 8 and 12wk postoperatively. This changing pattern corresponds with our clinical observation that few patients complain of eye discomfort after 4wk postoperatively. Tropicamide - phenylephrine (Mydrin - P, Santen) was provided for all patients routinely, which can lead to photophobia. Thus, the symptom of photophobia may be caused by both the PPV and Mydrin-P.

Schirmer test is a traditional method for detecting tear secretion, while it's an invasive operation which induces reflex tearing. A positive correlation between TMH and Schirmer test value has been reported^[10]. Thus, TMH can be considered as a noninvasive test for tear secretion and it's also a sensitive

indicator of tear deficiency before dry eye appearance^[11]. Our study showed TMH increased 0.05 mm in 1wk and 0.02 in 2wk postoperatively which has little clinical significance, and there were no significant differences compared to pre-operation. PPV induced stimulation of ocular surface may contribute to reflex tearing, such as surgical incisions, sutures, and bulbar conjunctival edema. Along with the incision healing, sutures absorption, conjunctival edema subsiding and trauma repair, tear secretion decreases and returns to the baseline level.

TBUT reflects the stability of tear film, which is an important index to evaluate dry eye^[12]. Fluorescein TBUT is widely used in clinical examination, while the fluorescein dye can destabilize the tear film and it has been reported that fluorescein BUT can be affected by the volume of fluorescein. Oculus Keratograph can detect the very early changes of the tear film and record very low NITBUT objectively with high reliability and repeatability^[13-14]. Cox *et al*^[15] reported that NITBUT measured by Keratograph 4 can be substituted for the numerical fluorescein TBUT value. The present study recorded the changes of both NITBUT-first and NITBUT-average after PPV via Keratograph 5M. We found both of them were decreased significantly within 8wk postoperatively, especially in the first week, and recovered to the baseline levels gradually in 12wk postoperatively. Similar to our study, Cetinkaya *et al*^[16] reported that fluorescein TBUT impaired up to 1mo after phacoemulsification, followed by a recovering trend toward the preoperative level in 12wk. There was a significant positive correlation between NITBUT - first and NITBUT-average at each visit, demonstrating either of them can be used to evaluate tear film stability.

Golbet cells within conjunctival epithelium are special cells secreting mucins onto the ocular surface^[17]. Mucins secreted plays an important role in maintaining tear film stability, which can assist with removal of debris from the tear film and contribute to the hydrophilicity of tear film^[10-20]. Previous studies reported that the density of goblet cells didn't return to a preoperative level even at 3mo after cataract surgery^[21], but MUC5AC could recover to the preoperative level at 3mo after phacotrabeculectomy^[22]. Heimann *et al*^[23] reported that there was a significant decrease in MUC5AC positive goblet cells and distribution change of MUC1 in the conjunctival specimens of patients undergoing posterior segment surgery, which may contribute to the development of tear film instability and dry eye. The decrease in goblet cells has been reported to be correlated with the operative time of cataract surgery^[24]. Compared with cataract and glaucoma surgery, the operative time of PPV is longer, which may contribute to the decrease in goblet cells and tear film instability.

Operation induced damage to the cornea and conjunctiva destabilizes tear film. Intraoperative ocular surface manipulation, vigorous irrigation and microscopic light exposure were reported to be related to dry eye after cataract

surgery^[25], which may be associated with reduced goblet cell density. Thus, we presumed that ocular surface damage during PPV contributed to the tear film instability. Additionally, surgical incisions, conjunctival sutures and edema lead to morphological changes of ocular surface, which may also affect tear distribution and leading to a decrease of tear film stability^[26]. In this study, we found there was moderate correlation between TMH and NITBUT-average just in the first week after PPV, demonstrating that the effect of surgery-induced reflex tearing on tear film instability was weak.

Benzalkonium chloride is the most common preservative used in eye drops. It can cause lots of ocular adverse effects, including dry eye, ocular inflammation, trabecular meshwork degeneration, and even optic nerve injury, which is associated with its mitotoxic effect^[27]. In our study, all three eye drops used postoperatively contained benzalkonium chloride which may also contribute to tear film instability and dry eye postoperatively. However, the influence of benzalkonium chloride on meibomian glands takes weeks. So, benzalkonium chloride may have little contribution to the tear film instability within 8wk postoperatively.

Bulbar redness is a common clinical sign after ophthalmic surgery, and it may reflect the response of ocular surface to pathogenic stimuli and the severity of inflammation. Fujita *et al*^[28] reported that IL-1 β , IL-6, and IL-8 increased significantly after PPV. Thus, inflammatory events of the ocular surface can be evaluated *via* detecting bulbar redness. In clinical practice, bulbar redness is mainly assessed by photographic scales, including Institute for Eye Research scale, the Efron scale, and the Validated Bulbar Redness grading scale^[29]. Unlike the image-based scales, keratograph is the first commercially available device that can evaluate bulbar redness by analyzing the captured images automatically and objectively. Wu *et al*^[30] reported that its reproducibility was much higher than the other three image-based scales for evaluating bulbar redness. In our study, the bulbar redness score increased significantly within the 4wk postoperatively, but it recovered to the preoperative level in 8wk postoperatively. These results correspond with our clinical observation that most patients complain of eye discomfort within the 4wk after PPV, especially within the 2wk postoperatively. However, the sample size of this study is very small, which needs to be expanded. Also, another study on 25G PPV without sutures needs to be carried out further to exclude the impact of sutures and PPV associated risk factors will be analyzed further to reduce ocular surface damage.

In conclusion, to the best of our knowledge, this is the first study to evaluate the ocular surface after PPV *via* noninvasive Keratograph, including tear film and bulbar redness. Our results demonstrated that PPV caused various changes in the symptoms and signs of ocular surface damage at an early stage, while these changes returned to preoperative levels gradually afterwards. This study can serve as a guide for further treatment of ocular surface after PPV.

REFERENCES

- 1 Shimazaki J. Definition and diagnostic criteria of dry eye disease: historical overview and future directions. *Invest Ophthalmol Vis Sci* 2018; 59(14):DES7-DES12
- 2 Yamaguchi T. Inflammatory response in dry eye. *Invest Ophthalmol Vis Sci* 2018;59(14):DES192-DES199
- 3 Shiraishi A, Sakane Y. Assessment of dry eye symptoms: current trends and issues of dry eye questionnaires in Japan. *Invest Ophthalmol Vis Sci* 2018;59(14):DES23-DES28
- 4 Bower KS, Sia RK, Ryan DS, Mines MJ, Dartt DA. Chronic dry eye in photorefractive keratectomy and laser *in situ* keratomileusis: Manifestations, incidence, and predictive factors. *J Cataract Refract Surg* 2015;41(12):2624-2634
- 5 Sutu C, Fukuoka H, Afshari NA. Mechanisms and management of dry eye in cataract surgery patients. *Curr Opin Ophthalmol* 2016;27(1):24-30
- 6 Zhong S, Zhou HZ, Chen X, Zhang WQ, Yi LQ. Influence of glaucoma surgery on the ocular surface using oculus keratograph. *Int Ophthalmol* 2019;39(4):745-752
- 7 Cox SM, Nichols KK, Nichols JJ. Agreement between automated and traditional measures of tear film breakup. *Optom Vis Sci* 2015;92(9):e257-e263
- 8 Koh S, Ikeda C, Watanabe S, Oie Y, Soma T, Watanabe H, Maeda N, Nishida K. Effect of non-invasive tear stability assessment on tear meniscus height. *Acta Ophthalmol* 2015;93(2):e135-e139
- 9 Arriola-Villalobos P, Fernández-Vigo JI, Díaz-Valle D, Peraza-Nieves JE, Fernández-Pérez C, Benítez-Del-Castillo JM. Assessment of lower tear meniscus measurements obtained with Keratograph and agreement with Fourier-domain optical coherence tomography. *Br J Ophthalmol* 2015;99(8):1120-1125
- 10 Altan-Yaycioglu R, Sizmaz S, Canan, Coban-Karatas M. Optical coherence tomography for measuring the tear film meniscus: correlation with schirmer test and tear-film breakup time. *Curr Eye Res* 2013;38(7):736-742
- 11 Xie WJ, Zhang D, Chen J, Liu J, Yu Y, Hu L. Tear menisci after laser *in situ* keratomileusis with mechanical microkeratome and femtosecond laser. *Invest Ophthalmol Vis Sci* 2014;55(9):5806-5812
- 12 Tsubota K. Short tear film breakup time - type dry eye. *Invest Ophthalmol Vis Sci* 2018;59(14):DES64-DES70
- 13 Best N, Drury L, Wolffsohn JS. Clinical evaluation of the oculus keratograph. *Cont Lens Anterior Eye* 2012;35(4):171-174
- 14 Tian L, Qu JH, Zhang XY, Sun XG. Repeatability and reproducibility of noninvasive Keratograph 5M measurements in patients with dry eye disease. *J Ophthalmol* 2016;2016:8013621
- 15 Cox SM, Nichols KK, Nichols JJ. Agreement between automated and traditional measures of tear film breakup. *Optom Vis Sci* 2015;92(9):e257-e263
- 16 Cetinkaya S, Mestan E, Acir NO, Cetinkaya YF, Dadaci Z, Yener HI. The course of dry eye after phacoemulsification surgery. *BMC Ophthalmol* 2015;15:68
- 17 Gipson IK. Goblet cells of the conjunctiva: A review of recent findings. *Prog Retin Eye Res* 2016;54:49-63
- 18 Ablamowicz AF, Nichols JJ. Ocular surface membrane-associated mucins. *Ocul Surf* 2016;14(3):331-341
- 19 Baudouin C, Rolando M, Benitez Del Castillo JM, Messmer EM, Figueiredo FC, Irkec M, Van Setten G, Labetoulle M. Reconsidering the central role of mucins in dry eye and ocular surface diseases. *Prog Retin Eye Res* 2019;71:68-87
- 20 Hori Y. Secreted mucins on the ocular surface. *Invest Ophthalmol Vis Sci* 2018;59(14):DES151-DES156
- 21 Oh T, Jung Y, Chang DJ, Kim J, Kim H. Changes in the tear film and ocular surface after cataract surgery. *Jpn J Ophthalmol* 2012;56(2):113-118
- 22 Liu W, Li HL, Lu DY, Liang J, Xing XL, Liu AH, Zhao SZ, Li XR, Ji J. The tear fluid mucin 5AC change of primary angle-closure glaucoma patients after short-term medications and phacotrabeculectomy. *Mol Vis* 2010;16:2342-2346
- 23 Heimann H, Coupland SE, Gochman R, Hellmich M, Foerster MH. Alterations in expression of mucin, tenascin-c and syndecan-1 in the conjunctiva following retinal surgery and plaque radiotherapy. *Graefes Arch Clin Exp Ophthalmol* 2001;239(7):488-495
- 24 Cho YK, Kim MS. Dry eye after cataract surgery and associated intraoperative risk factors. *Korean J Ophthalmol* 2009;23(2):65-73
- 25 Li XM, Hu LZ, Hu JP, Wang W. Investigation of dry eye disease and analysis of the pathogenic factors in patients after cataract surgery. *Cornea* 2007;26(9):S16-S20
- 26 Xie WJ. Recent advances in laser *in situ* keratomileusis-associated dry eye. *Clin Exp Optom* 2016;99(2):107-112
- 27 Datta S, Baudouin C, Brignole-Baudouin F, Denoyer A, Cortopassi GA. The eye drop preservative benzalkonium chloride potently induces mitochondrial dysfunction and preferentially affects LHON mutant CELLS. *Invest Ophthalmol Vis Sci* 2017;58(4):2406-2412
- 28 Fujita A, Uchino E, Otsuka H, Arimura N, Noda Y, Ishibashi T, Sakamoto T. Ocular surface molecule after transconjunctival vitrectomy. *Br J Ophthalmol* 2011;95(3):419-423
- 29 Macchi I, Bunya VY, Massaro-Giordano M, Stone RA, Maguire MG, Zheng YJ, Chen M, Gee J, Smith E, Daniel E. A new scale for the assessment of conjunctival bulbar redness. *Ocul Surf* 2018;16(4):436-440
- 30 Wu S, Hong J, Tian L, Cui X, Sun X, Xu J. Assessment of Bulbar redness with a newly developed Keratograph. *Optom Vis Sci* 2015;92(8):892-899