

Histological observation of RGCs and optic nerve injury in acute ocular hypertension rats

Shuang Li¹, Jia-Hua Fang², Fa-Gang Jiang¹

Foundation item: National Natural Science Foundation of China (No.81000380H1204)

¹ Department of Ophthalmology, Union Hospital, Tongji Medical College, Huazhong University of Science and Technology, Wuhan 430022, Hubei Province, China

² Department of Ophthalmology, the First People's Hospital of Jingzhou, Yangtze University, Jingzhou 434000, Hubei Province, China

Correspondence to: Fa-Gang Jiang. Department of Ophthalmology, Union Hospital, Tongji Medical College, Huazhong University of Science and Technology, Wuhan 430022, Hubei Province, China. fgjiang@hotmail.com

Received:2010-11-09

Accepted:2010-11-28

Abstract

- **AIM:** To explore the injury of retinal ganglion cells (RGCs) and optic nerves in acute ocular hypertension (OHT) rats.
- **METHODS:** We retrogradely labeled RGCs and optic nerves of Sprague-Dawley rats by injecting 20g/L fluorogold (FG) into bilateral superior colliculi. Twenty-four hours after the injection, the right eyes were performed physiological saline anterior chamber perfusion with intraocular pressure maintained at 100mmHg for 60 minutes, while the contralateral eyes were performed sham procedure as control group without elevation of the saline bottle. Retinal hematoxylin and eosin (HE) sections, retinal whole mounts and frozen sections were made 14 days later to observe the morphology and survival of RGCs. Frozen sections and transmission electron microscopy were utilized to investigate the histological manifestations of optic nerves at the same time.
- **RESULTS:** A larger number of RGCs presented in control group. It had an average density of $1995 \pm 125/\text{mm}^2$ and distributed uniformly, while RGCs in OHT eyes reduced significantly to $1505 \pm 43/\text{mm}^2$ compared with control group ($P < 0.05$). The optic nerves in control group showed stronger and more uniform fluorescence on the frozen sections, and the auxiliary fibers as well as myelin sheaths were in even and intact organization by transmission electron microscopy. However, exiguous fluorescence signals, vesicular dissociation and disintegration of myelin sheaths were found in OHT group.

• **CONCLUSION:** The present study suggested that fluorogold retrograde tracing is a feasible, convenient method for quantitative and qualitative study of neuronal populations and axonal injury in acute ocular hypertension rats.

• **KEYWORDS:** fluorogold; acute ocular hypertension; retinal ganglion cells; optic nerve injury

DOI:10.3980/j.issn.2222-3959.2010.04.08

Li S, Fang JH, Jiang FG. Histological observation of RGCs and optic nerve injury in acute ocular hypertension rats. *Int J Ophthalmol* 2010;3(4):311-315

INTRODUCTION

Retinal ganglion cells (RGCs) are central nervous system (CNS) neurons, with cell bodies located in the retina and axonal processes along the optic nerve which connects the visual center of brain. Neurodegenerative diseases which lead to irreversible loss of visual function such as glaucoma, optic nerve injury and anterior ischemic optic neuropathy are characterized by the progressive death of RGCs and their axons. The cell enumeration and histological observation of RGCs and their axons is a pivotal assessment index in morphometric analysis of those diseases. RGCs loss has been typically evaluated by retinal histological sections, retinal flat mounts or nerve fiber counting in optic nerve cross sections [1]. Among the method of retrograde labeling, fluorogold is a commonly used fluorescent dye which is administrated into bilateral superior colliculus, lateral geniculate nucleus or optic nerve stump. The fluorescent dye moves along with retrograde axonal transport of optic nerve into RGCs, and then the fluorescent signals can be observed with retinal flat mounts or frozen sections under fluorescence microscope, confocal laser scanning microscopy, or confocal scanning laser ophthalmoscopy.

The acute ocular hypertension (OHT) model of rats is a valuable and widely used paradigm which produces pathological features almost identical to glaucoma. The purpose of the present study was to investigate the neurodegenerative insults to RGCs and optic nerves in a rat model of OHT, and explore the utilization value of fluorogold.

MATERIALS AND METHODS

Materials

Reagents Fluorogold and optimal cutting temperature compound was purchased from Biotium (USA) and Sakura Finetek (Japan), respectively. Major apparatus included binocular operating microscope (Carl Zeiss, Germany), stereotactic apparatus (David Kopf, USA), cryosection machine (Leica CM3050S, Germany), fluorescence microscope (Carl Zeiss, Germany) and transmission electron microscope (Philips Electronics NV CM10, The Netherlands).

Animals All animals were treated according to the ARVO resolution on the treatment of animals in research. A total of 32 female Sprague-Dawley rats, 3-4 months old and weighing 220-250g used in the experiment were supplied by Tongji Medical College Experimental Animal Center, Huazhong University of Science and Technology, and housed in Experimental Animal Center, Union hospital, Huazhong University of Science and Technology. They were maintained in a 12 hours light/dark environment and given access to food and water ad libitum.

Methods

Backlabeling of RGCs To examine the appearance and density changes of RGCs after OHT, 16 rats were treated with fluorogold to both superior colliculi. Briefly, rats were anesthetized by intraperitoneal injection of 100g/L chloral hydrate (350mg/kg). A midline incision was made in the scalp and the head was fixed in a stereotactic apparatus. A lateral craniotomy using a dental drill was made at a point 6.8mm caudal to the bregma and 1.6mm lateral to the midline on both sides of the skull according to the Paxinos atlas^[2]. After the craniotomy, 2 μ L 20g/L fluorogold was microinjected into the right and left superior colliculus at a depth of 4mm from the surface over 10 minutes, respectively, *via* a Hamilton syringe. The wound was sutured, antibiotic ointment applied and the animal returned to its cage following recovery from anaesthesia.

Animal model Retinal ischemia was induced by high intraocular pressure (IOP) in the anterior chamber 24 hours after the labeling procedure. Animals were anesthetized by intraperitoneal injection of 100g/L chloral hydrate (350mg/kg). After conjunctival sac irrigated, corneal analgesia was achieved using topical drops of 2.5g/L dicaine. The anterior chamber of the right eye was cannulated with a 27-gauge infusion needle connected to a 500mL plastic container of sterile saline, the IOP was raised to 100mmHg (1kPa=7.5mmHg) and maintained for 60 minutes by elevating the saline reservoir to a height of 136cm^[3]. Then the saline reservoir was lowered slowly and the needle was pulled out to allow reperfusion. During the

course of infusion, care was taken not to injury the lens and the iris. Retinal ischemia was confirmed by observing whitening of the iris and loss of red reflex of the retina. The contralateral eye was used as control in which sham procedure was performed without elevation of the saline reservoir. After 0.5% erythromycin ointment applied to the eyes, animals were monitored and returned to their home cages when awake.

Quantitative analysis of RGCs Eight rats receiving high IOP insult were deeply anaesthetized using the method mentioned above and perfused through the left ventricle of the heart with 50mL of phosphate buffered saline (pH7.4) followed by 40g/L paraformaldehyde in phosphate buffered saline at 15th day after fluorogold application. Two hours after the perfusion, the eyes were enucleated and post-fixed in 40g/L paraformaldehyde for 4 hours. The retinas were detached and prepared as flattened whole mounts in paraformaldehyde (40g/L in PBS) by making incisions in it that reached from the dorsal, ventral, nasal, and temporal poles to the optic disc^[4]. After covered with 500g/L glycerol in 0.1 M PB and air dried in a dark-box, the retina specimen was observed under fluorescence microscope (magnification 200). Fluorogold labeled positive RGCs were counted from 12 distinct areas (three areas per retinal quadrant at three different eccentricities of one sixth, one half, five sixths of the retinal radius) for each animal by observers blinded to the treatment received by the rats. The surviving rate of RGCs was calculated.

Hematoxylin and eosin staining of retina Eight rats underwent OHT were sacrificed after the survival time. The eyecups were processed for routine paraffin embedded sections at 2 μ m thickness, and stained with hematoxylin and eosin (HE).

Frozen sections The eyeballs of 8 rats with attached optic nerves about 5mm length were harvested after cardiac perfusion, fixed in 40g/L paraformaldehyde for 2 hours at room temperature. The tissues were then dehydrated in 300g/L sucrose overnight at 4°C. After frozen in cutting compound with liquid nitrogen, cryostat-cut sections (10 μ m) of the eyes were picked up onto gelatin-coated glass slides and imaged with a fluorescence microscope. The optic nerves were cut longitudinally and transversely, respectively.

Transmission electron microscopy In consideration of the ultrastructural observation of the damaged optic nerve, eyes of the remaining 8 rats were quickly excised after intraperitoneal overdose injection of 100g/L chloral hydrate. Retrobulbar optic nerves about 5mm length were dissected and immersed in fixative containing 20g/L glutaraldehyde and 40g/L paraformaldehyde in 0.1 M cacodylate buffer.

Twenty-four hours later, the optic nerves were stained with 20g/L aqueous uranyl acetate, osmicated, dehydrated in ethanols and finally embedded in Epon. Ultrathin sections were performed and observed with an electron microscope and photographed.

Statistical Analysis The statistical analysis was performed by using a commercially available statistical software package (SPSS for Windows, version 15.0; SPSS, Chicago, Illinois, USA). The statistical significance of intergroup differences in the RGC densities was examined by the Student's *t*-test for unpaired samples.

RESULTS

Retinal Whole Mounts RGCs retrogradely labeled with fluorogold showed a characteristically fine-dotted pattern of flavous fluorescence in the perikarya. Prominent fluorogold positive RGCs uniformly distributed in all retinal quadrants in control eyes, whereas no cells were labeled in the retinal vessels (Figure 1A). The density of RGCs was $1995 \pm 125/\text{mm}^2$. In OHT group, fluorogold-positive RGCs only demonstrated exiguous fluorescence (Figure 1B), and the RGCs density dramatically decreased to $1505 \pm 43/\text{mm}^2$. The surviving cells accounted for about 75% of the total RGCs in control retinas ($t=10.48, P < 0.05$ vs control group, Figure 1C).

Retinal HE Sections HE stained retinas showed a marked loss of RGCs and disorganization of the neurons arrangement due to acute ocular hypertension insults. Meanwhile, the cell number and the thickness of the inner nuclear layer declined greatly compared with the control (Figures 2A and 2B).

Frozen Sections Densely packed RGCs were displayed on the cryosections in control group with the number of $33.13 \pm 4.29/\text{section}$, while massive loss of RGCs were found in OHT group with the number of $20.88 \pm 3.14/\text{section}$ ($t=6.52, P < 0.05$ vs control group, Figure 3). Neurons in inner nuclear layer and outer nuclear layer were not labeled by fluorogold in both groups, and different retinal layers could be roughly discriminated from each other. In the cross frozen sections of optic nerves, stronger and more uniform fluorescence signals were observed in control group compared with those in OHT group (Figures 4A and 4B). In the longitudinal sections of optic nerves in control group, it also showed higher intensity of setuliform fluorescence signals in the distant axons (Figures 4C and 4D).

Transmission electron microscopy Optic nerve in control eyes by electron microscopic evaluation indicated a well-shaped appearance and normal axoplasm of nerve fibers (Figure 5A), whereas it exhibited severely degenerated axons in OHT group, characterized by enormous amount of myelin debris and myelin residue, dark cytoplasm, devoid of

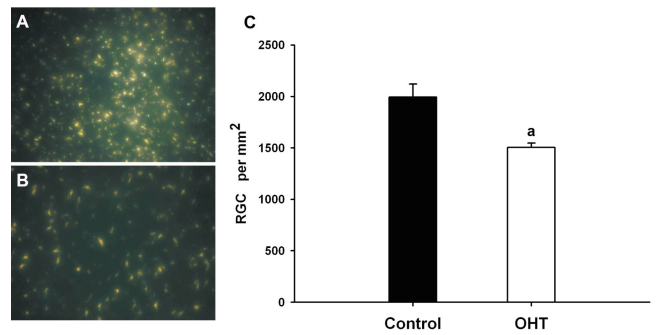


Figure 1 Retinal whole mounts (×200) A: Control group; B: OHT group; C: The density of FG-labeled RGCs in retinal whole mounts ^a*P* < 0.05 vs control group

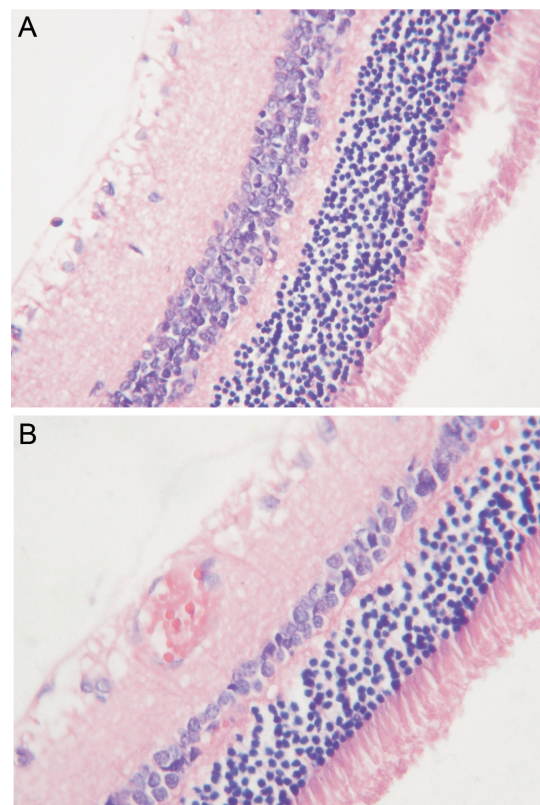


Figure 2 Retinal HE sections (×400) A: Control group; B: OHT group

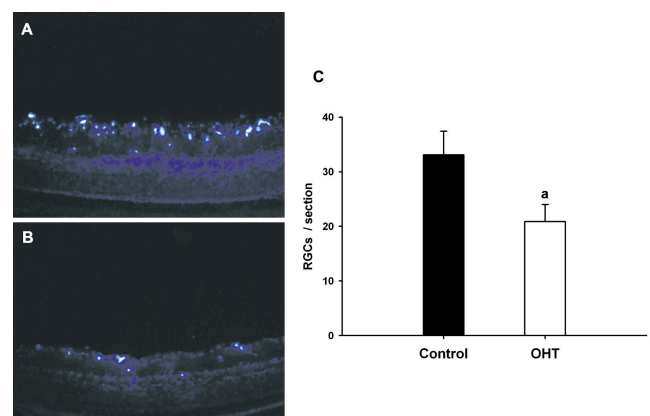


Figure 3 Retinal frozen sections (×200) A: Control group; B: OHT group; C: The density of FG-labeled RGCs in retinal frozen sections ^a*P* < 0.05 vs control group

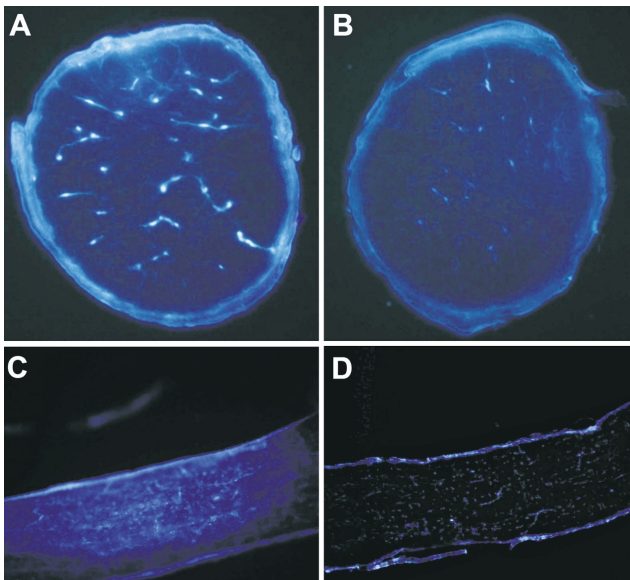


Figure 4 Frozen sections of optic nerve ($\times 200$) A: Optic nerve cross section of control group; B: Optic nerve cross section of OHT group; C: optic nerve longitudinal section of control group; D: Optic nerve longitudinal section of OHT group

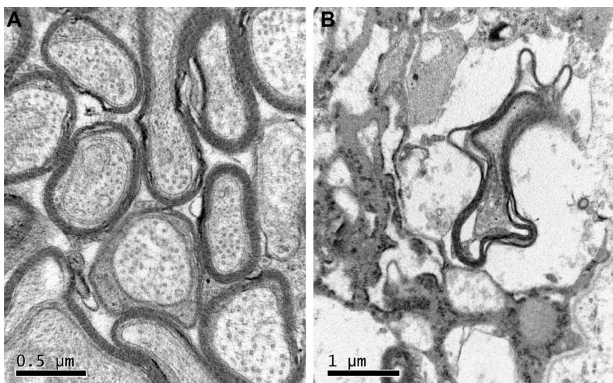


Figure 5 Optic nerve ultrastructure by transmission electron microscopy A: Control group; B: OHT group

well aligned microtubules and neurofilament. Thick intact myelin sheath structure was replaced by disintegration and vacuolization (Figure 5B).

DISCUSSION

Optic nerves which are composed of axons of RGCs are white matter fibers of brain. Retina and optic nerve injury can be classified as mechanic, ischemic, toxic, radioactive and so on according to different injury mechanisms. OHT model mimics ocular hypertensive status of glaucoma and causes ischemia-reperfusion (I/R) injury to RGCs and optic nerves which can be evaluated by backlabeling with neuronal tracer. It is also an animal model commonly used for the study of RGCs loss and leads to the initiation of caspase cascades and apoptosis of RGCs in a predictable manner. The ischemia-reperfusion model of rat in our study induced about 25% death rate of total RGCs and a certain degree of damage to their axons. The results were shown to

be in good agreement with prior studies, suggesting that fluorogold labeling was a reliable quantitation method about RGCs in response to OHT.

An ideal neuronal tracer should be stable, non-toxic, and produce optimal signal intensity with minimal fading of fluorescence. Fluorogold is a new highly sensitive fluorescence tracer for labeling RGCs somas which rarely quench once applied. It transmits through the retrograde axonal transport of optic nerves and reaches the somas of RGCs 3 days after administration. Thus the distribution and density of RGCs are most readily observed by retinal whole mounts^[5]. Besides stereotactic injection, fluorogold can be directly injected into the precise site of the superior colliculi or optic nerves, but some brain tissue should be removed in order to disclose the injection site. After the application of fluorogold labeling, retinal whole mounts as well as frozen sections serve as inexpensive and convenient qualitative approaches which display morphologic appearance and enumeration of RGCs without any manipulations of immunohistochemistry. In both methods, the fluorogold signals are predominantly demonstrated in the neuroretinal layer. Longitudinal and transverse frozen sections of optic nerves not only directly display the distribution of fluorescence in the axons fibers of RGCs, but also indirectly reflect the number of axons, the function of retrograde axoplasmic transport and the injury degree of optic nerves. Nevertheless, frozen section of optic nerve is too thick to accurately quantify auxiliary fibers. Thus, semithin section and toluidine blue staining of optic nerve which is treated in accordance with approaches of electron microscopy is a complicated but precise method. In our study, the injury of optic nerve myelin sheaths and auxiliary fibers observed by electron microscopy confirmed the results obtained by frozen sections. Large parts of all these auxiliary fibers were occupied by dense astrocytic scar tissue, implying that many axons were lost irreversibly.

Actually, apart from superior colliculi stereotactic injection, there are other options of labeling RGCs applying fluorogold tracer such as embedding and intravitreal injection. But the process of superior colliculi stereotactic injection presents many merits including less injury to the animal and less volume of use compared with embedding, which is performed by placing a small piece of Gelfoam soaked with fluorogold either onto corresponding brain tissue surface or against the proximal cut surface of optic nerve after transection^[6,7]. In retrograde tracing, other neuronal tracers such as horseradish peroxidase (HRP), fast blue (FB), and rhodamine (RITC, FITC) can be applied to identify and label RGCs. HRP participates in the metabolism of cells and can not exist in the labeled cells for a long time. After the

labeling, it needs color developing reagent to make the cells dyed. FB is also a short-term retrograde labeling marker for RGCs. Rhodamine and FB fade fast under fluorescence. It is determined that fluorogold produces higher labeling cell density and remains labeled for periods of up to 9 months without apparent leakage of the tracer to other retinal cells. Intravitreal injection with fluorogold can anterograde label RGCs and optic nerves, but it is less effective than retrograde labeling because of the relatively low metabolic rate of vitreous body and slow infiltration of fluorogold.

At present, there are a great body of labeling and quantitating approaches comprising retrograde labeling, Nissl staining and immunolabeling^[8-10]. A common limitation of these labeling techniques is that they are not non-invasive. Despite the manifold advantages and superiorities in fluorogold labeling by stereotactic injection, some drawbacks should be noted. Firstly, the performance of superior colliculi injection needs specified instruments including stereotactic atlas and brain stereotactic apparatus corresponding to different experimental animals. Furthermore, the approach of craniotomy is complicated. It causes a certain proportion of position fixing errors due to inter-individual variability of animal sizes and may compromise the survival of animals. Secondly, the debris of degenerated RGCs labeled with fluorogold dye can be taken up by gliocytes. It may lead to the staining of gliocytes as well as enumeration errors of RGCs^[11]. Hence, it needs to distinguish RGCs from microglial cells based on the cellular morphology. Thirdly, hematoxylin and eosin (HE) staining is capable of labeling both the cytoplasm and nucleus. But fluorogold only dye the cell bodies of the ganglion cells under the resolution of existing imaging techniques. Therefore, the morphological features of axonal and dendritic processes can not be visualized. Meanwhile, as backlabeling rely on the retrograde axonal transport of optic nerve^[12], the function status of axons may affect the labeling and enumeration of RGCs. In order to decrease the error of labeling, we applied fluorogold before the establishment of OHT model in our research.

In summary, this study demonstrates that fluorogold retrograde labeling is convenient and valuable for the

exploration of RGCs loss and optic nerve injury in OHT rats. Recently, retrograde labeling combined with other staining approaches has been developed by some researchers. The use of *in vivo* non-invasive imaging techniques would have the potential to expedite the research for neurodegenerative diseases^[13]. However, the labeling efficacy is controversial and many problems still remain to be resolved. Further work needs to be undertaken to study the quantitation about RGCs and their axons.

REFERENCES

- 1 Mabuchi F, Aihara M, Mackey MR, Lindsey JD, Weinreb RN. Optic nerve damage in experimental mouse ocular hypertension. *Invest Ophthalmol Vis Sci* 2003;44(10):4321-4330
- 2 Paxinos G, Watson C. The rat brain in stereotaxic coordinate. 2nd Edition. San Diego: Academic Press 1986: 54-56
- 3 Choi A, Choi JS, Yoon YJ, Kim KA, Joo CK. KR-31378, a potassium-channel opener, induces the protection of retinal ganglion cells in rat retinal ischemic models. *J Pharmacol Sci* 2009;109(4):511-517
- 4 Ma K, Xu L, Zhang H, Zhang S, Pu M, Jonas JB. Effect of brimonidine on retinal ganglion cell survival in an optic nerve crush model. *Am J Ophthalmol* 2009;147(2):326-331
- 5 Choi D, Li D, Raisman G. Fluorescent retrograde neuronal tracers that label the rat facial nucleus: a comparison of Fast Blue, Fluoro-ruby, Fluoro-emerald, Fluoro-Gold and DiI. *J Neurosci Methods* 2002;117(2):167-172
- 6 Park K, Luo JM, Hisheh S, Harvey AR, Cui Q. Cellular mechanisms associated with spontaneous and ciliary neurotrophic factor-cAMP-induced survival and axonal regeneration of adult retinal ganglion cells. *J Neurosci* 2004;24(48):10806-10815
- 7 Cheung ZH, So KF, Lu Q, Yip HK, Wu W, Shan JJ, Pang PK, Chen CF. Enhanced survival and regeneration of axotomized retinal ganglion cells by a mixture of herbal extracts. *J Neurotrauma* 2002;19(3):369-378
- 8 Leahy KM, Ormberg RL, Wang Y, Zhu Y, Gidday JM, Connor JR, Wax MB. Quantitative ex vivo detection of rodent retinal ganglion cells by immunolabeling Brn-3b. *Exp Eye Res* 2004;79(1):131-140
- 9 Moradzadeh A, Brenner MJ, Whitlock EL, Tong AY, Luciano JP, Hunter DA, Myckatyn TM, Mackinnon SE. Bipolar electrocautery: A rodent model of Sunderland third-degree nerve injury. *Arch Facial Plast Surg* 2010;12(1):40-47
- 10 Schlamp CL, Johnson EC, Li Y, Morrison JC, Nickells RW. Changes in Thy1 gene expression associated with damaged retinal ganglion cells. *Mol Vis* 2001;7(15):192-201
- 11 Maeda K, Sawada A, Matsubara M, Nakai Y, Hara A, Yamamoto T. A novel neuroprotectant against retinal ganglion cell damage in a glaucoma model and an optic nerve crush model in the rat. *Invest Ophthalmol Vis Sci* 2004;45(3):851-856
- 12 Schmued LC, Fallon JH. Fluoro-gold: a new fluorescent retrograde axonal tracer with numerous unique properties. *Brain Res* 1986;377(1):147-154
- 13 Leung CK, Weinreb RN. Experimental detection of retinal ganglion cell damage *in vivo*. *Exp Eye Res* 2009;88(4):831-836