

Clinical outcomes of amniotic membrane loaded with 5-FU PLGA nanoparticles in experimental trabeculectomy

Fang Hu, Xiang-Yun Zeng, Zhao-Lian Xie, Lin-Lin Liu, Liang Huang

Department of Ophthalmology, the First Affiliated Hospital of Gannan Medical University, Ganzhou 341000, Jiangxi Province, China

Co-first authors: Fang Hu and Xiang-Yun Zeng

Correspondence to: Liang Huang. Department of Ophthalmology, the First Affiliated Hospital of Gannan Medical University, Ganzhou 341000, Jiangxi Province, China. hliang169@163.com

Received: 2013-11-27 Accepted: 2014-12-03

Abstract

• **AIM:** To evaluate the effect of amniotic membrane loaded with 5-fluorouracil poly (lactic-co-glycolic acid) (PLGA) nanoparticles (5-FU-NPs) in the surgical outcomes of experimental trabeculectomy in rabbits.

• **METHODS:** Thirty-two New Zealand white rabbits were randomly categorized into four groups with 8 rabbits in each group. Group 1, the control group, performed traditional trabeculectomy without adjuvant treatment. While the experimental groups performed compound trabeculectomy with different implantations including amniotic membrane (group 2), 5-FU-NPs (group 3) and amniotic membrane loaded with 5-FU-NPs (group 4). Clinical evaluations including IOP measurement and filtration bleb analysis were performed in all groups postoperatively.

• **RESULTS:** There is no significant difference of mean IOP in all groups at first 7d after surgery. While at P14, mean IOPs of experimental group 2 (9.8 ± 2.1 mm Hg), groups 3 (8.9 ± 2.8 mm Hg) and group 4 (7.6 ± 2.3 mm Hg) were significantly reduced compared to control group (12.4 ± 2.6 mm Hg; $n=8$, $P<0.05$). At P21, mean IOPs of groups 3 (11.7 ± 3.2 mm Hg) and group 4 (9.9 ± 1.6 mm Hg) were significantly decreased compared to control group (17.9 ± 1.6 mm Hg) and group 2 (16.6 ± 2.8 mm Hg; $n=8$, $P<0.05$). At P28, mean IOPs of groups 3 (13.8 ± 3.3 mm Hg) and group 4 (10.6 ± 2.0 mm Hg) were also significantly reduced compared to control group (19.4 ± 2.3 mm Hg) and group 2 (18.5 ± 2.4 mm Hg; $n=8$, $P<0.05$). Meanwhile mean IOP of group 4 is significantly decreased compared to group 3 at P28 ($n=8$, $P<0.05$). Survival analysis of functional filtration blub in all groups revealed the

longest survival time in group 4 (24.9 ± 5.1 d) compared to that in group 3 (20.6 ± 4.3 d), group 2 (15.0 ± 5.2 d) and control group (10.1 ± 5.7 d).

• **CONCLUSION:** Amniotic membrane loaded with 5-FU-NPs may function as an effective anti-scarring implant and provides improved long-term surgical outcomes for experimental trabeculectomy in rabbits.

• **KEYWORDS:** 5-fluorouracil; trabeculectomy; polyactic acid nanoparticles; amniotic membrane

DOI:10.3980/j.issn.2222-3959.2015.01.05

Hu F, Zeng XY, Xie ZL, Liu LL, Huang L. Clinical outcomes of amniotic membrane loaded with 5-FU PLGA nanoparticles in experimental trabeculectomy. *Int J Ophthalmol* 2015;8(1):29-34

INTRODUCTION

Glaucoma, the second leading cause of blindness, permanently damages vision in millions of people worldwide [1,2]. Currently, glaucoma filtration surgery (GFS) remains the most effective surgical procedure for lowering intraocular pressure (IOP). However, the filtering bleb scarring that developed from conjunctival and episcleral fibrosis is the main cause of surgical failure and limits the long-term surgical success [3,4]. A number of strategies have been developed to modulate the wound-healing process after filtration surgery, such as beta radiation therapy, conjunctival flap implantation as well as application of vascular endothelial growth factor (VEGF) inhibitor and antimetabolites [5-11]. 5-fluorouracil (5-FU) and mitomycin C (MMC) are two commonly used antimetabolites that have been served in GFS for more than two decades. 5-FU, the thymidylate synthase inhibitor, is a pyrimidine analog that interferes with DNA synthesis during the S phase of cell cycle. While MMC, the antibiotic/antineoplastic compound derived from *Streptomyces caespitosus*, is a potent DNA crosslinker and is toxic to endothelium. Although 5-FU and MMC have been proved to significantly improved surgical outcomes, severe complications were also reported such as high incidence of corneal toxicity as well as bleb leaks and infection [11-16]. Currently, no standardized protocol has been setup for the application of antimetabolites in GFS.

Development of novel drug delivery systems that release and administrate antimitotics to modulate wound-healing process will greatly improve the surgical outcomes of GFS and thus becomes the focus of current research.

Amniotic membrane (AM), the innermost layer of the placenta, contains a number of precious cytokines that are responsible for the anti-inflammatory, anti-scarring, and anti-angiogenic actions [17,18]. AM is widely used as a biomedical implant in transplantation treatment for its absorbable, biocompatible and non-toxic characteristics. After first application in trabeculectomy in 1998, AM has been served in numerous refractory glaucoma cases thereafter and brought in improved surgical outcomes with reduced local infection and extended functional bleb survival [19-24]. Poly lactic-co-glycolic acid (PLGA) is biodegradable polymers that can be easily produced with minimal systemic toxicity and have been commonly used in implant, microparticle, and nanoparticle treatments [25]. PLGA has been reported previously as a 5-FU drug delivery system with satisfactory short-term results in experimental trabeculectomy in rabbits [26,27]. However, the combined effect of 5-FU, PLGA and nanoparticles in trabeculectomy remain unknown.

The purpose of this study is to investigate the clinical outcomes of a novel 5-FU delivery system, amniotic membrane loaded with 5-FU PLGA nanoparticles (5-FU-NPs), in experimental trabeculectomy in rabbits.

MATERIALS AND METHODS

Animals All animal experiments in this study were conducted according to the guidelines of the Association for Research in Vision and Ophthalmology (ARVO) Statement regarding the care and use of animals for ophthalmic and vision research and approved by the Ethics Committee of the Gannan Medical University (Ganzhou, Jiangxi, China). Thirty-two New Zealand white female rabbits (weight, 2.5-3.0 kg) were used in the study and randomly categorized into four groups with 8 rabbits in each group.

Control group: Group 1, traditional trabeculectomy without 5-FU or amniotic membrane treatment.

Experimental groups: trabeculectomy combined with following treatments: Group 2, amniotic membrane; Group 3, 5-FU-NPs; Group 4, amniotic membrane loaded with 5-FU-NPs.

Preparation of Amniotic Membrane and 5-FU-NPs Pregnant women with no systemic disease were screened to rule out the infection of viral hepatitis, AIDS, syphilis, Chlamydia, and cytomegalovirus. Fresh placentas were collected from women who chose caesarean section. The amniotic surface was washed with sterile saline water, followed by the treatment of antibiotics mixture in which containing 0.4 U/L penicillin and 0.4 U/L streptomycin. After bluntly dissected chorion on a sterile platform, amnion membrane was put on a nitrocellulose filter paper with

epithelial side up and cut into 4 × 4-cm² size. Clipped amnion membranes were dried in vacuum lyophilizer for five hours then sealed at room temperature. 5-FU-NPs were prepared as previously described from water-in-oil-in-water (w/o/w) emulsions [28,29].

Preparation of Amniotic Membrane Loaded with 5-FU-NPs Amniotic membranes were fully rehydrated in saline water. 5-FU-NPs were spread evenly on the basal surface of amniotic membrane and then folded into a "sandwich" like structure, followed by the freeze-drying for 24h then packaged under vacuum at room temperature and sterilized by gamma 60 ray.

Glaucoma Filtration Surgery Trabeculectomy was performed by the same professional surgeon in both eyes of each animal. Briefly, a mixture of ketamine (50 mg/kg) and Toluene thiazide (15 mg/kg) was used for general anesthesia, while 0.5% tetracaine was used for subconjunctival anesthesia in experimental animals. Corneal traction suture was placed to fix the eye and expose the surgical site. A fornix-based conjunctival flap was incised on the superior lateral quadrant of the eye. A half-thickness, trapezoidal, 6 × 5 mm scleral flap was dissected followed by the corneal paracentesis. A 1.5 mm sclerectomy was performed 1 mm before trailing edge of the corneal limbus, followed by the peripheral iridectomy. Amniotic membrane, 5-FU-NPs and amniotic membrane loaded with 5-FU-NPs were spread on the scleral flap and below the conjunctival flap in group 2, 3 and 4 respectively. The scleral flap was closed with three 10-0 nylon sutures and one drop of chloromycetin eye drops was installed in both eyes.

Clinical Evaluation Clinical evaluations including measurements of IOP and analysis of the filtration bleb were performed both preoperatively (5min before the surgery) and postoperatively (1, 7, 14, 21 and 28d after surgery; P1, P7, P14, P21 and P28).

Intraocular Pressure Measurement IOP was determined by Tono-pen tonometer (Tono-Pen XL, Mentor, USA). Two sets of three measurements of IOP were performed, yielding an average value for both series. All determinations were performed by the same observer and at the same time of the day.

Filtration Bleb Analysis The characteristics of the filtering bleb were analyzed in a blinded way as previously described [30].

Statistical Analysis Statistics analysis was performed using SPSS 16.0 software. IOP values were analyzed using Student's *t*-test and one-way ANOVA, survival analysis of functional IOP and bleb were using Kaplan-Meier method. A *P* value <0.05 was considered to be statistically significant.

RESULTS

Intraocular Pressure Measurements In order to confirm the animal surgical model represents a reliable wound healing process after trabeculectomy, we documented the

Table 1 Evolution of IOPs over times in all study groups

Experimental groups	Postoperative IOPs (mm Hg)				
	P1	P7	P14	P21	P28
Group 1	6.5±2.8	9.3±3.1	12.4±2.6	17.9±1.6	19.4±2.3
Group 2	6.6±2.2	8.5±3.2	9.8±2.1 ^a	16.6±2.8	18.5±2.4
Group 3	5.9±2.3	7.8±2.5	8.9±2.8 ^a	11.7±3.2 ^{a,c}	13.8±3.3 ^{a,c}
Group 4	5.2±3.4	7.0±2.6	7.6±2.3 ^{a,c}	9.9±1.6 ^{a,c}	10.6±2.0 ^{a,c,e}

Data presented as mean±SD, Paired Student's *t*-test, *n*=8. ^a*P*<0.05 with respect to the Group 1; ^c*P*<0.05 with respect to the Group 2; ^e*P*<0.05 with respect to the Group 3.

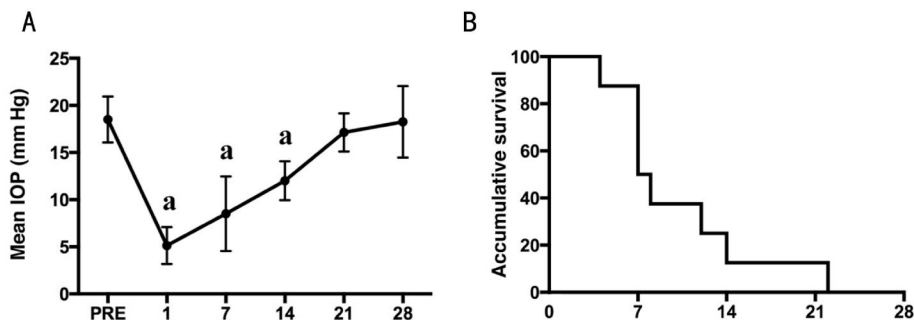


Figure 1 Variation of mean IOP and survival analysis of functional IOP over time in control group A: Mean IOP of control group at 5min before surgery and at 1, 7, 14, 21 and 28d postsurgery were recorded. ^aStatistically significant differences with respect to presurgical IOP (PRE); B: Survival analysis of functional IOP in the control group over time after surgery.

IOP variations in control group with no adjunctive treatment. Using IOP five minutes before surgery as a control, the postoperative IOP in control group dramatically reduced at P1, P7 and P14 (Table 1, Figure 1). Afterwards, IOP keeps elevating and there is no statistical difference between basal and postoperative IOP by P21 (Figure 1). The mean survival of functional IOP in control group was 10.1 (5.7d, Figure 2). Thus our rabbit trabeculectomy model represents a successful surgical performance and a wound healing process.

In experimental groups, the postoperative IOP decreased in a similar manner as control group and there is no significant difference among four groups until P14 (Table 1, Figure 2). At P14, all experimental groups revealed remarkable lower IOP than the control group, as well as an apparent reduction in group 4 by comparison to group 2 (Table 1, Figure 2C). At P21, there is no significant difference of mean IOP between group 2 and control group, while the mean IOP of groups 3 and 4 were significantly reduced compare to the control group and group 2 (Table 1, Figure 2D). At P28, the mean IOP of group 3 and 4 were significantly reduced compare to the control group and group 2, as well as a significant difference between groups 3 and 4 (Table 1, Figure 2E). The survival analysis and one-way ANOVA comparison of functional IOP among all groups demonstrated a longer mean survival time in group 4 (22.6±5.32d) compare to groups 1 (10.1±5.74d), 2 (15.3±5.78d) and 3 (21.5±4.75d) (Figure 3).

Filtration Bleb Analysis The filtration blebs were photographed and analyzed by the same observer. There is no significant difference among groups in the first week after trabeculectomy. At P14 and P28, functional filtration blebs

were only observed in groups 3 and 4 (Figure 4). Survival analysis of the functional filtration bleb revealed the longest survival time in group 4 (24.9±5.22d) among all groups, followed by the group 3 (20.6±4.3d), group 2 (15.2±5.2d) and group 1 (9.9±5.7d) (Figure 5).

DISCUSSION

In this study, we investigated the surgical outcomes of an improved 5-FU delivery system, which employed amniotic membrane as the substrate and the PLGA nanoparticles as the sustained release carrier of 5-FU in experimental trabeculectomy in rabbits. To date, the consensus for an ideal drug delivery system is biocompatible and biodegradable without local or systemic toxicity. Although numerous materials have been developed for antimicrobials application to modulate wound-healing process in GFS, individual limitations still exist. For example, polyanhydrides and collagen are both biodegradable and have been used as drug delivery system for the release of 5-FU and MMC in GFS. However, they are associated with wound dehiscence and implant extrusion as well as local inflammatory phenomena^[31]. Poly (ortho esters), the biodegradable polymers have been reported to prolong GFS survival in rabbits, have their own limitation of unreliable release kinetics^[32]. Poly (hydroxy esters), including polylactic acid (PLA), polycaprolactone (PLC) and PLGA are biodegradable polymers, while only PLGA has been suggested as an excellent drug delivery system for its minimal toxicity and shorter degradation half-life compare to PLA^[26,33-35]. In our study, 5-FU-NPs, which made from PLGA nanoparticles, significantly prolonged the survival of functional filtering bleb and desired

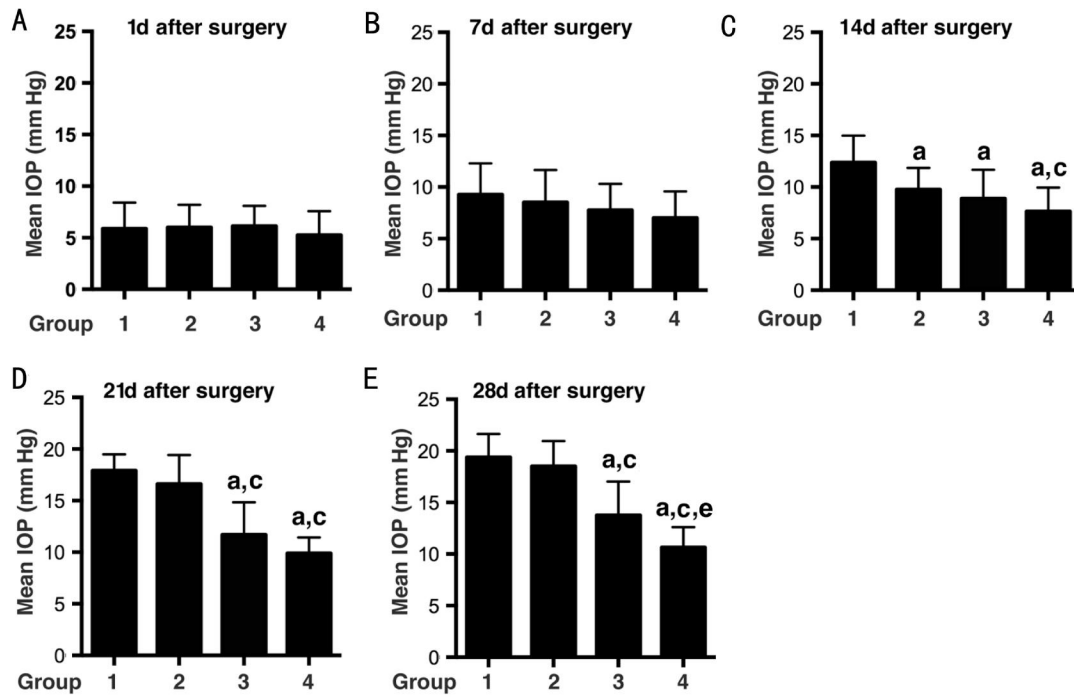


Figure 2 Comparison of the mean IOP values over time after surgery Mean IOP values of each group was recorded at P1 (A), P7 (B), P14 (C), P21 (D) and P28 (E) respectively. A-B: No statistical difference among four groups at P1 and P7; C: At P14, statistically significant differences observed between experiment group and control group (^a $P < 0.05$), as well as between group 2 and group 4 (^c $P < 0.05$); D: At P21, the mean IOP of group 3 and group 4 were significantly decreased compared to group 1 (^a $P < 0.05$) and group 2 (^c $P < 0.05$); E: At P28, same statistically significant differences observed between groups 3, 4 and group 1 (^a $P < 0.05$) and group 2 (^b $P < 0.05$). Meanwhile, there is a significant difference between group 3 and group 4 (^e $P < 0.05$).

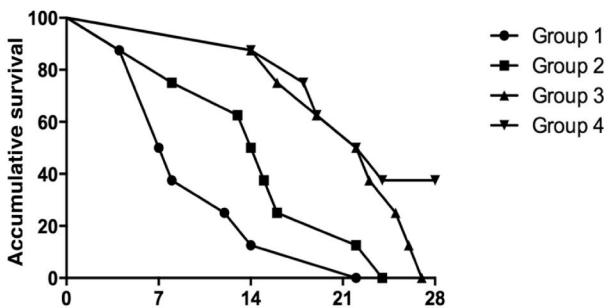


Figure 3 Survival analysis of functional IOP over time after surgery Survival analysis among groups revealed a longest survival time of functional IOP in group 4.

IOP control compare to the use of amniotic membrane and traditional trabeculectomy (Figures 3, 5).

Amniotic membrane, which locates at the innermost layer of the placenta with no blood or lymphatic vessels, is an excellent biodegradable biological membrane with low degree of immunogenicity. Amniotic membrane has played an important role in ocular surface reconstruction for decades [36-38]. Meanwhile it also inhibited local inflammation as well as scar formation after GFS [39,40]. In our study, trabeculectomy applied with amniotic membrane transplantation demonstrated a longer desirable IOP control (Figure 3) as well as longer survival time of the functional bleb after surgery compare to the control group (Figure 5).

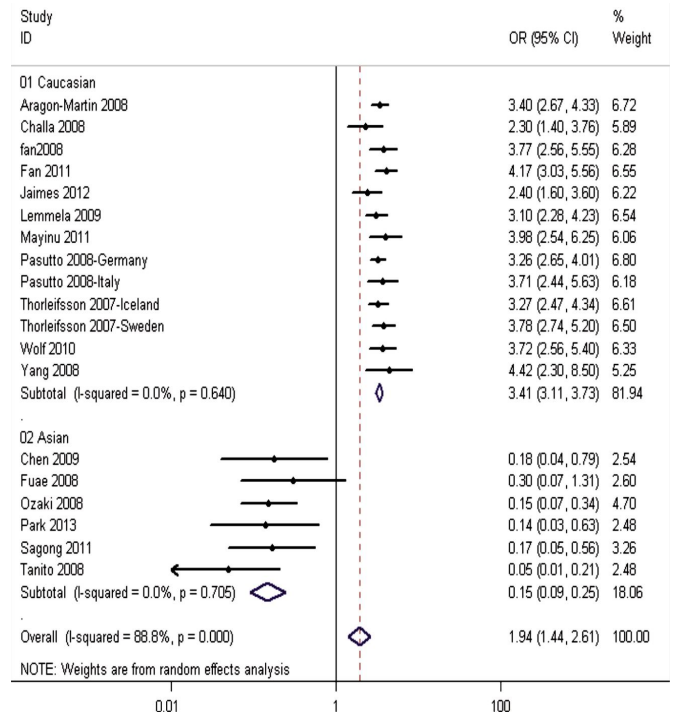


Figure 4 Morphology of filtration blebs at 14 and 28d after surgery Filtration blebs at P14 (A-D) and P28 (E-H) were analyzed. Functional filtration blebs were only observed in groups 3 and 4 in P14 and P28.

However, the anti-scarring role of amniotic membrane was restricted in the early postsurgical periods. From P21,

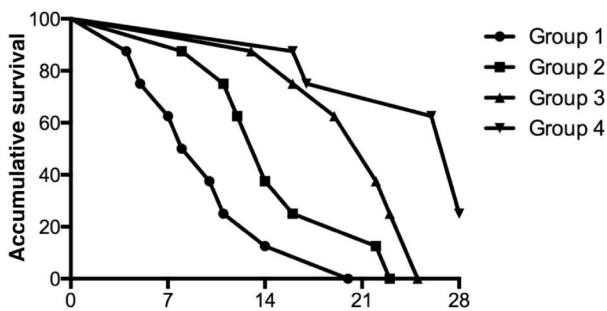


Figure 5 Survival analysis of functional filtration bleb after surgery Survival analysis over time after surgery revealed a longest survival time of functional filtration bleb in group 4.

amniotic membrane appears less effective than 5-FU-NPs in maintaining desired IOP (Figures 2, 3) and the functional bleb (Figures 4, 5).

Although PLGA and amniotic membrane each provides better surgical outcome of trabeculectomy, the combined effect of these two biological materials remains unknown. In our study, we developed a novel drug delivery system combined amniotic membrane with 5-FU loaded PLGA nanoparticles. As we expected, this combined delivery system exhibit the advantages of both two materials. Trabeculectomy combined with implantation of amniotic membrane loaded with 5-FU-NPs revealed better surgical outcomes than any other experimental groups, including significantly reduced IOP with long-term desired IOP control and prolonged survival of functional filtration bleb.

In conclusion, our findings revealed that surgical outcomes of experimental trabeculectomy could be significantly improved by the application of amniotic membrane loaded with 5-FU-NPs, which significantly prolonged the survival of functional filtration bleb and desired IOP control. However, the mechanism though which the system works remains unknown. The scarring process and local inflammation after application of amniotic membrane loaded with 5-FU-NPs should be investigated in future. This novel 5-FU delivery system exhibits its potential to be severed as an effective implantation in GFS to provide improved long-term surgical outcomes for glaucoma patients.

ACKNOWLEDGEMENTS

Foundations: Supported by National Natural Science Foundation of China (No.81060081, 81241124 and 81360155); Jiangxi Provincial Natural Science Foundation (No.2008GZY00123, 2010GZY0089, 20114BAB205068 and 20114BAB215006).

Conflicts of Interest: Hu F, None; Zeng XY, None; Xie ZL, None; Liu LL, None; Huang L, None.

REFERENCES

1 Resnikoff S, Pascolini D, Etya'ale D, Kocur I, Pararajasegaram R, Pokharel GP, Mariotti SP. Global data on visual impairment in the year 2002. *Bull World Health Organ* 2004;82(11):844-851

2 Kingman S. Glaucoma is second leading cause of blindness globally. *Bull World Health Organ* 2004;82(11):887-888

3 Hitchings RA, Grierson I. Clinico pathological correlation in eyes with failed fistulizing surgery. *Trans Ophthalm Soc UK* 1983;103 (Pt 1):84-88

4 Skuta GL, Parrish RK 2nd. Wound healing in glaucoma filtering surgery. *Surv Ophthalmol* 1987;32(3):149-170

5 Kirwan JF, Rennie C, Evans JR. Beta radiation for glaucoma surgery. *Cochrane Database Syst Rev* 2012;6:CD003433

6 Fendi LI, Arruda GV, Costa VP, Paula JS. Meta-analysis of beta radiation augmentation for trabeculectomy - results in distinct ethnic groups. *Arq Bras Oftalmol* 2011;74(4):300-305

7 Christakis PG, Tsai JC, Kalenak JW, Zurakowski D, Cantor LB, Kammer JA, Ahmed II. The ahmed versus baerveldt study: three-year treatment outcomes. *Ophthalmology* 2013;120(11):2232-2240

8 Gedde SJ, Panarelli JF, Banitt MR, Lee RK. Evidenced-based comparison of aqueous shunts. *Curr Opin Ophthalmol* 2013;24(2):87-95

9 Van Bergen T, Jonckx B, Hollanders K, Sijnave D, Van de Velde S, Vandewalle E, Moons L, Stassen JM, Stalmans I. Inhibition of placental growth factor improves surgical outcome of glaucoma surgery. *J Cell Mol Med* 2013;17(12):1632-1643

10 Paula JS, Ribeiro VR, Chahud F, Cannellini R, Monteiro TC, Gomes EC, Reinach PS, Rodrigues Mde L, Silva-Cunha A. Bevacizumab-loaded polyurethane subconjunctival implants: effects on experimental glaucoma filtration surgery. *J Ocul Pharmacol Ther* 2013;29(6):566-573

11 Lockwood A, Brocchini S, Khaw PT. New developments in the pharmacological modulation of wound healing after glaucoma filtration surgery. *Curr Opin Pharmacol* 2013;13(1):65-71

12 Zarbin MA. Combination therapy to reduce conjunctival scarring after glaucoma surgery. *JAMA Ophthalmol* 2013;131(9):1123

13 Matlach J, Panidou E, Grehn F, Klink T. Large-area versus small-area application of mitomycin C during trabeculectomy. *Eur J Ophthalmol* 2013; 23(5):670-677

14 Chawla A, Mercieca K, Fenerty C, Jones NP. Outcomes and complications of trabeculectomy enhanced with 5-Fluorouracil in adults with glaucoma secondary to uveitis. *J Glaucoma* 2013;22(8):663-666

15 Wong MH, Husain R, Ang BC, Gazzard G, Foster PJ, Htoon HM, Wong TT, Oen FT, Khaw PT, Seah SK, Aung T. The Singapore 5-fluorouracil trial: intraocular pressure outcomes at 8 years. *Ophthalmology* 2013;120 (6):1127-1134

16 Salim S. Current variations of glaucoma filtration surgery. *Curr Opin Ophthalmol* 2012;23(2):89-95

17 Burman S, Tejwani S, Vemuganti GK, Gopinathan U, Sangwan VS. Ophthalmic applications of preserved human amniotic membrane: a review of current indications. *Cell Tissue Bank* 2004;5(3):161-175

18 Sippel KC, Ma JJ, Foster CS. Amniotic membrane surgery. *Curr Opin Ophthalmol* 2001;12(4):269-281

19 Fujishima H, Shimazaki J, Shinozaki N, Tsubota K. Trabeculectomy with the use of amniotic membrane for uncontrollable glaucoma. *Ophthalmic Surg Lasers* 1998;29(5):428-431

20 Tawara A, Miyamoto N, Ishibashi S, Nagata T, Harada Y, Tou N, Kondo H. Reconstruction of a nonfunctional trabeculectomy bleb using an amniotic membrane-wrapped silicone sponge to treat refractory glaucoma. *Graefes Arch Clin Exp Ophthalmol* 2013;251(8):2013-2018

21 Ji QS, Qi B, Liu L, Lao W, Yang ZH, Wang GF, Yu GC, Zhong JX. Comparison of trabeculectomy and trabeculectomy with amniotic membrane transplantation in the same patient with bilateral glaucoma. *Int J Ophthalmol* 2013;6(4):448-451

- 22 Stavrakas P, Georgopoulos G, Milia M, Papaconstantinou D, Bafa M, Stavrakas E, Moschos M. The use of amniotic membrane in trabeculectomy for the treatment of primary open-angle glaucoma: a prospective study. *Clin Ophthalmol* 2012;6:205–212
- 23 Nakamura M, Naka M, Tatsumi Y, Nagai-Kusuhara A, Kanamori A, Yamada Y, Negi A. Filtering bleb structure associated with long-term intraocular pressure control after amniotic membrane-assisted trabeculectomy. *Curr Eye Res* 2012;37(3):239–250
- 24 Okada H, Tawara A, Kubota T, Nagumo H. Amniotic Membrane Transplantation for Repair of Leaking Glaucoma Filtering Blebs with Scleral Perforation. *Ophthalmic Surg Lasers Imaging* 2010;1–4
- 25 Athanasiou KA, Niederauer GG, Agrawal CM. Sterilization, toxicity, biocompatibility and clinical applications of polylactic acid/polyglycolic acid copolymers. *Biomaterials* 1996;17(2):93–102
- 26 Gould L, Trope G, Cheng YL, Heathcote JG, Sheardown H, Rootman D, Liu GS, Menon IA. Fifty:fifty poly (DL glycolic acid–lactic acid) copolymer as a drug delivery system for 5-fluorouracil: a histopathological evaluation. *Can J Ophthalmol* 1994;29(4):168–171
- 27 Trope GE, Cheng YL, Sheardown H, Liu GS, Menon IA, Heathcote JG, Rootman DS, Chiu WJ, Gould L. Depot drug delivery system for 5-fluorouracil after filtration surgery in the rabbit. *Can J Ophthalmol* 1994;29(6):263–267
- 28 Guan XP, Quan DP, Liao KR, Tao W, Peng X, Mai KC. Preparation and characterization of cationic chitosan-modified poly (D,L-lactide-co-glycolide) copolymer nanospheres as DNA carriers. *J Biomater Appl* 2008;22(4):353–371
- 29 Gavini E, Chetoni P, Cossu M, Alvarez MG, Sattone MF, Giunchedi P. PLGA microspheres for the ocular delivery of a peptide drug, vancomycin using emulsification/spray-drying as the preparation method: in vitro/in vivo studies. *Eur J Pharm Biopharm* 2004;57(2):207–212
- 30 Xin C, Wang NL, Qiao LY. Clinical observation on glaucoma filtering blebs *in vivo*. *Zhonghua Yan Ke Za Zhi* 2008;44(5):461–464
- 31 Rodriguez-Agirretxe I, Vega SC, Rezola R, Vecino E, Mendicuti J, Suarez-Cortes T, Acera A. The PLGA implant as an antimetabolic delivery system after experimental trabeculectomy. *Invest Ophthalmol Vis Sci* 2013;54(8):5227–5235
- 32 Einmahl S, Behar-Cohen F, D'Hermies F, Rudaz S, Tabatabay C, Renard G, Gurny R. A new poly (ortho ester)-based drug delivery system as an adjunct treatment in filtering surgery. *Invest Ophthalmol Vis Sci* 2001;42(3):695–700
- 33 Cui LJ, Sun NX, Li XH, Huang J, Yang JG. Subconjunctival sustained release 5-fluorouracil for glaucoma filtration surgery. *Acta Pharmacol Sin* 2008;29(9):1021–1028
- 34 Lu DW, Chang CJ, Chiang CH, Yeh MK, Chou PI. Wound modulation after trabeculectomy by different formulations of antimetabolites in rabbits. *J Ocul Pharmacol Ther* 2000;16(6):529–538
- 35 Chiang CH, Tung SM, Lu DW, Yeh MK. *In vitro* and *in vivo* evaluation of an ocular delivery system of 5-fluorouracil microspheres. *J Ocul Pharmacol Ther* 2001;17(6):545–553
- 36 Meller D, Pires RT, Mack RJ, Figueiredo F, Heiligenhaus A, Park WC, Prabhasawat P, John T, McLeod SD, Steuhl KP, Tseng SC. Amniotic membrane transplantation for acute chemical or thermal burns. *Ophthalmology* 2000;107(5):980–989
- 37 Yoon KC, Im SK, Kim JC, Yoon KW, Choi SK. Prognosis of paraquat-induced ocular surface injury: therapeutic effect of amniotic membrane transplantation. *Cornea* 2009;28(5):520–523
- 38 Nakamura T, Yoshitani M, Rigby H, Fullwood NJ, Ito W, Inatomi T, Sotozono C, Nakamura T, Shimizu Y, Kinoshita S. Sterilized, freeze-dried amniotic membrane: a useful substrate for ocular surface reconstruction. *Invest Ophthalmol Vis Sci* 2004;45(1):93–99
- 39 Shaunak S, Thomas S, Gianasi E, Godwin A, Jones E, Teo I, Mireskandari K, Luthert P, Duncan R, Patterson S, Khaw P, Brocchini S. Polyvalent dendrimer glucosamine conjugates prevent scar tissue formation. *Nat Biotechnol* 2004;22(8):977–984
- 40 Nakamura T, Sekiyama E, Takaoka M, Bentley AJ, Yokoi N, Fullwood NJ, Kinoshita S. The use of trehalose-treated freeze-dried amniotic membrane for ocular surface reconstruction. *Biomaterials* 2008;29 (27): 3729–3737