

# Androgen and meibomian gland dysfunction: from basic molecular biology to clinical applications

Li-Xiang Wang, Ying-Ping Deng

Department of Ophthalmology, West China Hospital of Sichuan University, Chengdu 610041, Sichuan Province, China

**Correspondence to:** Ying-Ping Deng. Department of Ophthalmology, West China Hospital of Sichuan University, No.37 Guoxue Alley, Wuhou District, Chengdu 610041, Sichuan Province, China. ypd\_wch@163.com

Received: 2020-05-12 Accepted: 2020-07-20

## Abstract

• Meibomian gland, the largest sebaceous gland of the body, is responsible for the biosynthesis of lipid layer of the tear film to prevent excessive evaporation. The loss of normal functions of meibomian gland, known as meibomian gland dysfunction (MGD), is a chronic disease and is the leading cause of dry eye symptoms in the clinics. Studies have found sex hormones, especially androgen, play vital roles in the regulation of the functions of meibomian gland. Recently, androgen has also been preliminarily applied in clinics for the treatment of MGD and showed promising results, especially in people with endogenous androgen deficiency. This review summarized the mechanisms of the function of androgen on meibomian gland based on molecular, animal, and clinical studies, and proposed evidence-based views about its potential applications for the treatment of MGD.

• **KEYWORDS:** meibomian gland dysfunction; androgen; dry eye disease

**DOI:**10.18240/ijo.2021.06.18

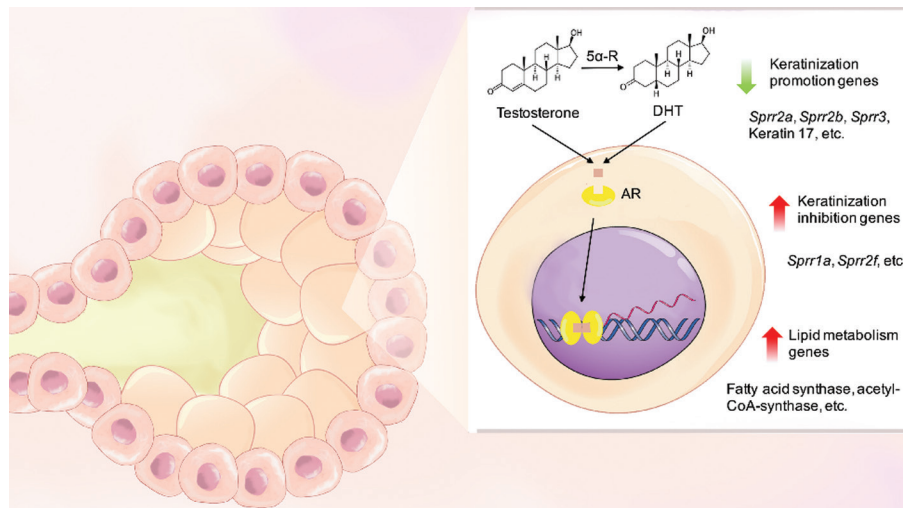
**Citation:** Wang LX, Deng YP. Androgen and meibomian gland dysfunction: from basic molecular biology to clinical applications. *Int J Ophthalmol* 2021;14(6):915-922

## INTRODUCTION

**M**eibomian gland, first described by German anatomist Meibom Heinrich in 1666, plays important roles in the secretion of lipid and maintenance of tear film stability. The series of glands are located within the upper and lower eye lids and arranged vertically to the lid margin. The terminal ducts connect all acini with the main ducts, and their orifices can

be clearly observed at the lid margin. The meibomian glands in the upper eye lids are greater in quantity and length, and store twice the amount of lipid of the lower eye lids<sup>[1]</sup>. The lipid secreted by meibomian gland is called meibum, which is a complicated mixture of various kinds of lipid molecules. Meibum is critical to the tear film because it covers the surface of the aqueous layer and prevents excessive evaporation<sup>[2]</sup>. Meibum also has the function of protecting the eye surface from microorganism invasion, assisting tight closure of lid margin during night sleep and regulating the tension force of the tear film<sup>[3]</sup>. The role of meibomian gland is so important that the impairment of its normal function can lead to serious problems. Meibomian gland dysfunction (MGD) is commonly characterized by a chronic, diffuse abnormality of meibomian gland structures, terminal duct obstruction, and qualitative or quantitative changes of lipid secretion. MGD is found to be the leading cause of dry eye disease in clinics, accounting for approximately 40%-60% of dry eye symptoms<sup>[4-7]</sup>. Patients often suffer from prolonged dryness, burning and foreign body sensation and may experience impaired quality of life<sup>[8]</sup>. There are many studies that dig into the pathophysiology of MGD and many factors are believed to play a role in the pathological process of the disease, including congenital abnormalities, decreased blink frequency, chronic inflammation of eye surfaces and hormonal disturbance<sup>[9-13]</sup>. However, the pathogenesis of MGD is still poorly understood. Currently, the fundamental therapy for MGD is physical therapy to remove the blockage of gland openings. Many novel therapies are under investigation, including androgen replacement therapy (ART) to be discussed in this review. A thorough understanding of the biological actions of sex hormones on meibomian gland is the cornerstone for their further applications in clinics.

Sex hormones, especially androgen, have been found to be a key regulator of the functions of meibomian gland<sup>[9]</sup>. The expression of a variety of genes associated with the biosynthesis, secretion, differentiation and proliferation processes of meibomian gland have been found to be regulated by androgen<sup>[14-15]</sup>. Patients with androgen deficiency are more likely to suffer from MGD than normal people<sup>[16]</sup>. Many studies found an increased prevalence of MGD in aged people with endogenous androgen deficiency, such as postmenopausal



**Figure 1** Schematic diagram of the action of androgen on gene expressions of meibomian gland acinar cells Testosterone can be converted to the more active DHT by local 5 $\alpha$ -reductase (5 $\alpha$ -R) in meibomian gland acinar cells. Both forms of androgen are able to activate AR located in the cytoplasm. The ligand-activated ARs then form dimers and recognize specific regions of DNA after entering the cell nucleus to regulate gene expressions. Genes associated with lipid metabolism and cell keratinization processes are found to be key responders among >1000 genes found to be regulated by androgen in meibomian gland.

women<sup>[17-18]</sup>. Recently, androgen has been applied for the treatment of MGD and dry eye disease and demonstrated promising results. This review will summarize currently available findings about androgen and MGD and discuss its clinical practical values.

**EXPRESSION OF ANDROGEN RECEPTORS ON MEIBOMIAN GLAND**

The research of meibomian gland has gained increasing attention in recent years by ophthalmologists, physiologists, and endocrinologists. Many of the methodologies and hypotheses come from previous findings on sebaceous glands. Before the discovery of the expression of androgen receptors (AR) on meibomian gland, the action of androgen on the function of meibomian gland has been observed in several studies<sup>[19-20]</sup>. Previous studies on sebaceous glands have demonstrated that androgen could regulate their function through AR in acinar cells<sup>[21]</sup>. In 2000, Rocha *et al*<sup>[22]</sup> used immunoperoxidase technique and discovered the presence of AR in human meibomian gland acinar cells and confirmed that meibomian gland was also the target organ of androgen. In addition, Rocha *et al*<sup>[22]</sup> also discovered the presence of type 1 and type 2 5 $\alpha$ -reductase mRNAs in the meibomian glands cells. These enzymes could transform testosterone into the more active form of dihydrotestosterone (DHT)<sup>[22]</sup> (Figure 1). Wickham *et al*<sup>[23]</sup> discovered AR mRNA in the meibomian gland cells by RT-PCR. These studies established the foundations for further researches on the role of androgen on meibomian gland.

**ANDROGEN AND KERATINIZATION**

Hyperkeratinization of ductal cells is believed to be one of the

mechanisms behind the pathogenesis of MGD<sup>[24]</sup>. Ohnishi and Kohno<sup>[25]</sup> first described hyperkeratinization and dilation of ducts in the polychlorinated biphenyl (PCB) induced monkey MGD model in 1979. These pathologic changes have also been observed in various other MGD animal models, including adrenaline-induced rabbit model<sup>[26]</sup>, rhino mouse model<sup>[27]</sup>, low lipid diet-induced hairless mice model<sup>[28]</sup> as well as on patients suffering from MGD<sup>[29]</sup>. Hyperkeratinization of ductal cells can block the meibomian gland orifices by debris of keratinized cells and lead to secondary atrophy of acini. It is generally considered that hyperkeratinization tends to be one of the primary initiation factors of obstructive MGD. However, the mechanism behind hyperkeratinization of meibomian gland orifices is still poorly understood, and currently few therapies of MGD directly target the keratinization process.

*In vitro* experiments demonstrated that androgen could regulate the expressions of genes associated with the keratinization process of meibomian gland. AR is a kind of ligand-activated transcriptional factor which can modulate gene expressions after activated by the ligand<sup>[30]</sup> (Figure 1). Schirra *et al*<sup>[31]</sup> examined mRNA profiles of meibomian gland cells of orchietomized mice *via* microarray hybridization method. Compared with mice fed with placebo, those treated with systemic testosterone for 2wk showed significant alterations on the expressions of numerous genes, especially those involved in keratinization process. Genes that promoted epidemic cell differentiation and formation of keratin, such as small proline-rich protein 2a (*Sprr2a*), *Sprr2b*, *Sprr3*, keratin6a, keratin17 and periplakin were significantly down-regulated and genes encoding proteins that hampered epidermal

keratinization process, such as *Sprr1a* and *Sprr2f* were up-regulated by testosterone. In general, androgen could reduce the level of keratinization of meibomian gland. Sullivan *et al*<sup>[32]</sup> conducted similar experiments on ovariectomized mice and treated them with testosterone or placebo for 2wk before sacrifice. Among the 1009 genes found to be regulated by testosterone in meibomian gland, those associated with keratinization were found to be most prominently influenced by androgen ( $z$  score=10.2). Genes such as *sprr2a*, *Sprr2b*, *Sprr3*, cornifelin and keratin17 were significantly down-regulated in the androgen group. Khandelwal *et al*<sup>[15]</sup> tested the influence of DHT on gene expressions of immortalized human meibomian gland cells. The expression of over 3000 genes were found to be altered by DHT and most of the genes were involved lipogenesis pathways. However, the most prominent alteration was the 40 fold-decrease of mRNA level of *Sprr2a* gene. These studies confirmed that androgen could down-regulate keratinization process in human meibomian gland cells. As the meibomian gland ductal epithelial cells are going through constant renewal and turnover, application of androgen may have potential effects to reduce hyperkeratinization of duct openings from newly differentiated epithelial cells in the long term based on the findings of gene expression studies. However, these studies only provide evidence from molecular level. Gap still exists on the knowledge about whether androgen is able to ameliorate or even reverse hyperkeratinization of meibomian gland ducts in the gross model. Furthermore, physical therapies such as as meibomian gland massage and probing are widely used and able to eliminate meibomian gland blockage by mechanical removal of keratinized cell debris. These methods don't target the pathologic processes of keratinization and generally achieved transient relief of symptoms. Whether androgen can display superior effects on eliminating meibomian gland block compared with physical therapy need to be demonstrated by clinical studies.

#### ANDROGEN AND LIPID BIOSYNTHESIS

Meibum, the secretion of meibomian gland, is essential for maintaining the proper function of tear film<sup>[1]</sup>. Meibum is the complex mixture of multiple kinds of lipids produced by meibomian gland acinar cells. The nonpolar lipids lie at the outer surface of the lipid droplets, providing water-tight cover to prevent excessive evaporation of the aqueous layer and outflow of tear beyond the lid margin. While polar lipids are generally found at the core and pull nonpolar lipid molecules to maintain the intact structure of lipid droplets<sup>[33]</sup>. Wax ester (WE) and cholesterol ester (CE) compose the majority (60%-90%) of nonpolar lipids of meibum. Other nonpolar lipids include triacylglyceride (TAG) and free fatty acid (FFA). (O-acyl)- $\omega$ -hydroxy fatty acid (OAHFA), glycerophospholipid and

sphingolipid are the major types of polar lipids of meibum<sup>[34-37]</sup>. Joffre *et al*<sup>[38]</sup> found that approximately 25% of meibum fatty acids were saturated, and chained fatty acids made up another 20%. The composition of fatty acid and lipid profile contributes dramatically to the stability, fluidity and melting point of meibum<sup>[39-40]</sup>. However, the high complexity of meibum composition is the major barrier of investigating the link between changes of lipid composition and the pathogenesis of meibomian gland. With the help of more accurate lipid testing equipment, including high-pressure liquid chromatography, time-of-flight mass spectrometry and gas chromatography, the lipid composition between MGD patients and healthy individuals have been compared and the major differences have been illuminated.

Various studies have demonstrated the difference of the lipid compositions of meibum between MGD patients and healthy individuals. The most notable change is the increase of the proportion of FFA and chained unsaturated fatty acid. Sullivan *et al*<sup>[41]</sup> collected meibomian gland secretion samples from patients on anti-androgen medication, complete androgen insensitivity syndrome (CAIS) and healthy individuals. A significant difference in lipid species and compositions between groups under mass spectrometry was found. Nicolaidis *et al*<sup>[42]</sup> compared the meibum of rabbits with MGD induced by topical epinephrine with healthy controls and found an 8-fold increase of a cluster of FFA which was found to be the hydrolytic product of sterol esters. The increase of FFA composition of meibum was toxic to the epidermis *via* saponification process and could induce inflammatory reactions of eye surfaces and interrupt the stability of tear film<sup>[43]</sup>. Joffre *et al*<sup>[38]</sup> compared the meibomian extract of patients suffering from MGD with healthy individuals and found a significant difference of chained fatty acid composition (29.8% vs 20.2%). The author inferred that the proportion of WE and CE increased in patients of MGD because WE and CE were the predominant compositions of chained fatty acids of meibum. It has been found that the increase of WE and CE levels would rise the viscosity and phase transition temperature of meibum and make it more likely to block the orifices<sup>[44]</sup>. Another notable change was the increase of the composition of unsaturated fatty acid. Lam *et al*<sup>[45]</sup> studied the lipid compositions of meibum in Asian MGD patients and found an increase in the unsaturation of hydrocarbon chains in MGD patients, particularly in severe cases. This result was consistent with Borchman *et al*'s<sup>[46]</sup> findings. Many studies illuminated the influence of changes of chain saturation on physiological properties of meibum, especially the aspects of fluidity and acyl chain-melting phase transition temperature<sup>[47-50]</sup>. The raise of the unsaturation levels of meibum would make it more likely to solidify and block the orifices of meibomian gland<sup>[51]</sup>.

Overall, these studies demonstrate the quality of meibomian gland secretions is as important as the quantity of meibum. The altered lipid composition of patients suffering from MGD is associated with decreased fluidity, increased viscosity, and irritation to eye surfaces. Factors to restore the normal composition of meibum are beneficial for patients with MGD. With the help of microarray technique, many studies illustrated the effects of androgen on genes associated with lipid metabolism of meibomian gland *in vitro* (Figure 1). Schirra *et al*<sup>[31]</sup> found that androgen regulated the expressions of numerous genes associated with lipogenesis, lipid transport and lipolysis pathways in mouse meibomian gland. Fatty acid synthase was the key enzyme involved in the biosynthesis of fatty acid and was found to be up regulated by androgen. The genes involved in the synthesis of long- and very-long-chain fatty acids, such as fatty acid transport protein 4, was up-regulated in the androgen group. This was consistent with the findings of Shine and McCulley<sup>[52]</sup> that the length of hydrocarbon chains of WE and CE was significantly shorter in MGD patients with androgen deficiency. Genes associated with intracellular and extracellular transport of phospholipid and cholesterol, such as *Abc1*, *Abcd3*, sterol carrier protein 2 and phosphatidylcholine transfer protein were also found to be regulated by androgen. Shirra *et al*<sup>[53]</sup> found that androgen could facilitate the biosynthesis of both cholesterol and fatty acids by up-regulating genes encoding key enzymes such as ATP-citrate lyase, acetyl-CoA-synthase, acetyl-CoA-carboxylase, acetoacetyl-CoA-synthase and HMG-CoA synthase 1. Sullivan *et al*<sup>[32]</sup> compared the action of androgen on female and male mice and found similar regulation patterns of lipid-related pathways in meibomian gland. This indicated that androgen played similar roles in the lipid biosynthesis of meibomian gland on both genders. These effects of androgen are consistent with the findings on sebaceous gland. As the meibomian gland is a special type of sebaceous gland and serves similar functions, they also share similar hormonal regulation patterns. Androgen is one of the critical regulatory factors of lipid production of sebaceous gland and androgen deficiency is associated with decreased sebum production and skin dryness. However, high androgen level is also associated with pathogenic excessive sebum secretion and seborrheic dermatitis. In the case of MGD, according to the quantity of meibomian gland secretion, it can be divided into the low delivery and high delivery subtypes<sup>[1]</sup>. The majority of patients with MGD belongs to the low delivery subtype, and most of the previous studies investigating meibomian gland secretions only focus on this subtype. It is generally believed that androgen deficiency is associated with the low delivery subtype of MGD. However, it is not clear whether high androgen level is the risk factor of the high delivery subtype.

Furthermore, whether excessive stimulation of meibum secretion by androgen is associated with abnormal lipid composition and how it is linked to MGD need to be studied in the future. Appropriate level of ART and monitor of androgen levels should be investigated to avoid supra-therapeutic effects.

### INTERACTION OF ANDROGEN AND OTHER HORMONES

Besides androgen, meibomian gland has also been found to be regulated by a variety of other hormones, including estrogen, progesterone and insulin<sup>[10,54-55]</sup>. Studies found androgen not only regulated the function of meibomian gland through AR, but also interacted with other hormones and modified their functions<sup>[56]</sup>. First, androgen was found to antagonize the activity of estrogen on meibomian gland. Estrogen basically inhibited lipid production and secretion in sebaceous glands and was considered to be the antagonism of androgen on lipid metabolism<sup>[57]</sup>. Androgen blocked the activity of estrogen by up-regulating the expression of estrogen inhibitory receptor 2 $\beta$  and down-regulating the expression of estrogen activating receptor 1 $\alpha$ <sup>[58]</sup>. Second, androgen also enhanced the local synthesis of androgen itself from adrenal precursors in meibomian glands by up-regulating the cellular level of 17 $\beta$ -hydroxysteroid dehydrogenase 7. This enzyme could convert 17-ketosteroids to their corresponding 17 $\beta$ -hydroxysteroids, the precursors of androgen<sup>[56]</sup>. Third, androgen enhanced the activity of insulin-like growth factor 1 (IGF-1) by protecting the stability of its mRNA. IGF-1 was found to regulate steroidogenesis, lipid accumulation and cell proliferation in immortalized human meibomian epithelial cells *via* phosphoinositol 3-kinase/Akt and forkhead box O1 pathways<sup>[59]</sup>. Ding *et al*<sup>[55]</sup> found insulin could also regulate the function of meibomian gland through IGF-1 receptors. Patients of diabetes mellitus with insulin deficiency or insensitivity were found to be more likely to suffer from MGD than people with normal blood glucose levels<sup>[60]</sup>. The central connection role of androgen with other hormones make it the principle hormonal regulatory factor of the functions of meibomian gland. However, compared with androgen, the regulation function of other hormones on meibomian gland are relatively poorly understood. Particular, the actions of estrogen and progesterone on meibomian gland are largely inferred from studies on sebaceous glands. This gap of knowledge will limit the application of androgen as hormonal replacement therapy for post-menopausal women, because estrogen is primarily used to ameliorate menopausal symptoms and reduce risk of cardiovascular events. How androgen should be used in combination with estrogen replacement therapy to improve the function of meibomian gland and treat dry eye disease in this group of patients should be investigated based on evidence from animal and clinical data in the future studies.

**Table 1 Detailed summary of the efficacy studies of androgen to treat MGD**

Species	Age and gender	Basic conditions	Interventions	Dose and frequency	Duration	Outcomes of meibomian gland evaluation	Outcomes of dry eye evaluation	Ref.
Albino rats	Adult, all male, n=24	MGD induced by topical isotretinoin	DHEA eye drops	1% DHEA, twice daily	3mo	Minimal ductal keratinization and acinar atrophy in androgen group compared with control	None	[61]
Dogs	2-11 years old, n=4	Chronic bilateral conjunctivitis	DHEA eye drops	1.5% DHEA, 3 times a day	7wk	Increased total volume and phospholipid composition of meibomian gland secretions	Decreased ocular surface inflammation	[62]
Human	A 52-year-old woman	Dry eye disease	DHEA eye drops	1.5% DHEA, 3 times a day	3wk	Profuse lipid visible at meibomian gland openings under slit lamp	Increased TBUT	[62]
Rabbit	A female rabbit, 3 years old	Normal eye examination	DHEA eye drops	1.5% DHEA, once daily	1mo	Acinar cells showed lighter staining nuclei and hazy cytoplasm in histology study	None	[62]
Human	A 54-year-old man	Dry eye disease, androgen deficiency	T cream	3% T applied 3 times a day to eyelids	6mo	Increased TFLL thickness	Improvement of dry eye symptoms; Increased TBUT; increased Schirmer's test	[64]
Human	All female, 18-30 years old, n=5	Klinefelter's syndrome, 3 had SS, 2 had SLE	T undecanoate oral tablets	120 mg daily, divided into 2 doses	60d	Increased TFLL thickness compared with baseline and placebo control	Increased Schirmer's test; decreased corneal staining	[65]
Human	All female, mean age=65.2 years old, n=11	Post-menopausal women with dry eye disease	esterified estrogen and MT (combined therapy)	N.A.	Mean 12.2mo (SD=6.2mo)	Improved clinical examination of dry eye and meibomian gland	Improved subjective evaluation of dry eye; increased Schirmer's test	[66]
Human	All female, mean age=63.9 years old, n=40	Post-menopausal women with dry eye disease	T cream solely or in combination with oestradiol cream	0.5 mL 1% T cream, 1 g 1 mg/g oestradiol, once a day	8wk	No change of meibomian gland signs compared with baseline and placebo control	No change of OSDI score, tear osmolarity, NITBUT, Schirmer's test and corneal staining	[67]
Human	n=179	MGD	T eye drops	0.01%, 0.03% and 0.1% T eye drops	6mo	Improve meibomian gland secretion quality	Improve subjective feelings of ocular discomfort	[68]

DEHA: Dehydroepiandrosterone; T: Testosterone; TFLL: Tear film lipid layer; TBUT: Tear breakup time; NITBUT: Non-invasive tear breakup time; SS: Sjögren's syndrome; SLE: Systemic lupus erythematosus; MT: Methyltestosterone; OSDI: Ocular surface disease index.

### APPLICATIONS OF ANDROGEN TO TREAT MGD

As androgen has been found to regulate the functions of meibomian gland, it was applied on animal models and patients to treat MGD and showed promising results (Table 1). Ibrahim and Elwan<sup>[61]</sup> applied 1% dehydroepiandrosterone (DHEA, a precursor of androgen) topically twice a day for 3mo to isotretinoin-induced MGD albino rat models. Compared with the control group, rats given topical DHEA showed minimal keratinization of ductal epithelium and degeneration of acinar cells. This indicated that DHEA is beneficial in the treatment of MGD. Zeligs and Gordon<sup>[62]</sup> administered eye drops containing 0.5%-1.5% DHEA on rabbits, Pekingese dogs and human suffering from MGD and found an increase of tear film breakup time (BUT) and lipid production of meibomian gland. Sullivan *et al*<sup>[63]</sup> conducted experiments on orchietomized rabbits and showed topical and systemic applications of 19-nortestosterone for 2wk significantly altered the lipid species of meibomian gland secretions and restored the normal compositions of meibum. In patients with endogenous androgen

deficiency, such as postmenopausal women and people with Klinefelter's syndrome or Sjögren's syndrome, androgen was found to relieve dry eye symptoms and increase lipid film thickness<sup>[64-66]</sup>. There are also some randomized clinical trials to study the efficacy of androgen on MGD, but the results are controversial. Golebiowski *et al*<sup>[67]</sup> conducted a randomized double-blind placebo-controlled trial on 40 postmenopausal women with dry eye disease. Patients were divided in groups given transdermal placebo, testosterone, oestradiol or both hormones for 8wk. No significant improvement of symptoms or the function of meibomian gland were observed between groups. However, tear stability was improved in the testosterone group and its improvement was correlated with serum testosterone level. Schiffman *et al*<sup>[68]</sup> conducted a multi-center, randomized, double-masked, vehicle-controlled study on 179 patients suffering from MGD. Topical testosterone solutions with different concentrations were administered for up to 6mo. The study demonstrated that 0.03% testosterone eye drop demonstrated most beneficial effects on aspects of

symptom relief and lipid quality improvement. No significant difference of adverse effects was observed between the control group and test group. Overall, these animal and clinical studies demonstrated potential but still controversial effects of androgen therapy for the treatment of MGD. Currently very few high-quality clinical studies with large cohorts to demonstrate the efficacy and safety of androgen to treat MGD are available. In the future, clinical studies may need to address the following aspects. First, MGD is most prevalent in aged males. However, most of previous studies investigated the effect of androgen on post-menopausal women, probably due to their endogenous androgen deficiency states and higher prevalence of dry eye disease. In the future, studies to include more male patients as well as younger participants are needed to illuminate and compare the age and sex associated therapeutic effects. Second, long term application of androgen is associated with definite adverse effects, including seborrheic dermatitis, alopecia, cardiovascular complications, elevated risk of prostate cancer *etc*<sup>[69]</sup>. The major androgen formulations to treat MGD include ophthalmic solutions and skin creams and are associated with different grades of bioavailability and systemic absorption. As MGD is a chronic disorder, long term therapy is essential and adverse effects are inevitable. Thus, safety studies to investigate the adverse effects associated with different formulations and treatment periods of androgen therapy on different ages and sex groups of patients with MGD should be conducted before it can be broadly used in clinics.

## CONCLUSION

The importance of androgen on the normal functions of meibomian gland has been illustrated by various studies. Androgen demonstrates extensive actions on lipid biosynthesis, epithelial keratinization, and regulation of the activities of other hormones on meibomian gland. Androgen has been applied in clinics to treat MGD and showed potential results. However, much is unknown about the optimal formulations of androgen (eye drops, creams, or tablets) and subgroups of people with greatest responses (age and gender). More studies are needed to further demonstrate the efficacy and safety of the androgen for patients with MGD.

## ACKNOWLEDGEMENTS

**Foundation:** Supported by West China Hospital of Sichuan University (No.2020HXBH044).

**Conflicts of Interest:** Wang LX, None; Deng YP, None.

## REFERENCES

- 1 Nelson JD, Shimazaki J, Benitez-del-Castillo JM, Craig JP, McCulley JP, Den S, Foulks GN. The international workshop on meibomian gland dysfunction: report of the definition and classification subcommittee. *Invest Ophthalmol Vis Sci* 2011;52(4):1930-1937.
- 2 Chhadva P, Goldhardt R, Galor A. Meibomian gland disease: the role of gland dysfunction in dry eye disease. *Ophthalmology*

- 2017;124(11S):S20-S26.
- 3 Butovich IA. Meibomian glands, meibum, and meibogenesis. *Exp Eye Res* 2017;163:2-16.
- 4 Wang MTM, Vidal-Rohr M, Muntz A, Diprose WK, Ormonde SE, Wolffsohn JS, Craig JP. Systemic risk factors of dry eye disease subtypes: a New Zealand cross-sectional study. *Ocul Surf* 2020;18(3):374-380.
- 5 Villarreal-Gonzalez AJ, Jocelyn Rivera-Alvarado I, Rodriguez-Gutierrez LA, Rodriguez-Garcia A. Analysis of ocular surface damage and visual impact in patients with primary and secondary Sjögren syndrome. *Rheumatol Int* 2020;40(8):1249-1257.
- 6 Chan TCY, Chow SSW, Wan KHN, Yuen HKL. Update on the association between dry eye disease and meibomian gland dysfunction. *Xianggang Yi Xue Za Zhi* 2019;25(1):38-47.
- 7 Asiedu K, Dzasimatu SK, Kyei S. Clinical subtypes of dry eye in youthful clinical sample in Ghana. *Cont Lens Anterior Eye* 2019;42(2):206-211.
- 8 Guo OD LW, Akpek E. The negative effects of dry eye disease on quality of life and visual function. *Turk J Med Sci* 2020;50(SI-2): 1611-1615.
- 9 Hampel U, Garreis F. The human meibomian gland epithelial cell line as a model to study meibomian gland dysfunction. *Exp Eye Res* 2017;163:46-52.
- 10 Schröder A, Abrar DB, Hampel U, Schicht M, Paulsen F, Garreis F. *In vitro* effects of sex hormones in human meibomian gland epithelial cells. *Exp Eye Res* 2016;151:190-202.
- 11 Bu JH, Wu Y, Cai XX, Jiang N, Jeyalatha MV, Yu JW, He X, He H, Guo YL, Zhang MJ, Quantock AJ, Liu ZG, Li W. Hyperlipidemia induces meibomian gland dysfunction. *Ocul Surf* 2019;17(4):777-786.
- 12 Sandra Johanna GP, Antonio LA, Andrés GS. Correlation between type 2 diabetes, dry eye and Meibomian glands dysfunction. *J Optom* 2019;12(4):256-262.
- 13 Qazi Y, Kheirkhah A, Blackie C, Trinidad M, Williams C, Cruzat A, Korb DR, Hamrah P. Clinically relevant immune-cellular metrics of inflammation in meibomian gland dysfunction. *Invest Ophthalmol Vis Sci* 2018;59(15):6111-6123.
- 14 Sahin A, Liu Y, Kam WR, Darabad RR, Sullivan DA. Dihydrotestosterone suppression of proinflammatory gene expression in human meibomian gland epithelial cells. *Ocul Surf* 2020;18(2):199-205.
- 15 Khandelwal P, Liu S, Sullivan DA. Androgen regulation of gene expression in human meibomian gland and conjunctival epithelial cells. *Mol Vis* 2012;18:1055-1067.
- 16 Sullivan DA, Sullivan BD, Ullman MD, Rocha EM, Krenzer KL, Cermak JM, Toda I, Doane MG, Evans JE, Wickham LA. Androgen influence on the meibomian gland. *Invest Ophthalmol Vis Sci* 2000;41(12):3732-3742.
- 17 Azcarate PM, Venincasa VD, Feuer W, Stanczyk F, Schally AV, Galor A. Androgen deficiency and dry eye syndrome in the aging male. *Invest Ophthalmol Vis Sci* 2014;55(8):5046-5053.

- 18 Sriprasert I, Warren DW, Mircheff AK, Stanczyk FZ. Dry eye in postmenopausal women: a hormonal disorder. *Menopause* 2016;23(3):343-351.
- 19 Imperato-McGinley J, Gautier T, Cai LQ, Yee B, Epstein J, Pochi P. The androgen control of sebum production. Studies of subjects with dihydrotestosterone deficiency and complete androgen insensitivity. *J Clin Endocrinol Metab* 1993;76(2):524-528.
- 20 Thody AJ, Shuster S. Control and function of sebaceous glands. *Physiol Rev* 1989;69(2):383-416.
- 21 Miyake K, Ciletti N, Liao S, Rosenfield RL. Androgen receptor expression in the preputial gland and its sebocytes. *J Invest Dermatol* 1994;103(5):721-725.
- 22 Rocha EM, Wickham LA, da Silveira LA, Krenzer KL, Yu FS, Toda I, Sullivan BD, Sullivan DA. Identification of androgen receptor protein and 5alpha-reductase mRNA in human ocular tissues. *Br J Ophthalmol* 2000;84(1):76-84.
- 23 Wickham LA, Gao J, Toda I, Rocha EM, Ono M, Sullivan DA. Identification of androgen, estrogen and progesterone receptor mRNAs in the eye. *Acta Ophthalmol Scand* 2000;78(2):146-153.
- 24 Geerling G, Baudouin C, Aragona P, Rolando M, Boboridis KG, Benítez-Del-Castillo JM, Akova YA, Merayo-Llodes J, Labetoulle M, Steinhoff M, Messmer EM. Emerging strategies for the diagnosis and treatment of meibomian gland dysfunction: proceedings of the OCEAN group meeting. *Ocul Surf* 2017;15(2):179-192.
- 25 Ohnishi Y, Kohno T. Polychlorinated biphenyls poisoning in monkey eye. *Invest Ophthalmol Vis Sci* 1979;18(9):981-984.
- 26 Jester JV, Nicolaides N, Kiss-Palvolgyi I, Smith RE. Meibomian gland dysfunction. II. The role of keratinization in a rabbit model of MGD. *Invest Ophthalmol Vis Sci* 1989;30(5):936-945.
- 27 Jester JV, Rajagopalan S, Rodrigues M. Meibomian gland changes in the rhino (hrrhhrrh) mouse. *Invest Ophthalmol Vis Sci* 1988;29(7):1190-1194.
- 28 Miyake H, Oda T, Katsuta O, Seno M, Nakamura M. Meibomian gland dysfunction model in hairless mice fed a special diet with limited lipid content. *Invest Ophthalmol Vis Sci* 2016;57(7):3268-3275.
- 29 Korb DR, Henriquez AS. Meibomian gland dysfunction and contact lens intolerance. *J Am Optom Assoc* 1980;51(3):243-251.
- 30 Sakkiah S, Ng HW, Tong WD, Hong HX. Structures of androgen receptor bound with ligands: advancing understanding of biological functions and drug discovery. *Expert Opin Ther Targets* 2016;20(10):1267-1282.
- 31 Schirra F, Gatzoufias Z, Scheidt J, Seitz B. Testosterone reduces the expression of keratinization-promoting genes in murine Meibomian glands. *Ophthalmologie* 2013;110(3):230-238.
- 32 Sullivan DA, Jensen RV, Suzuki T, Richards SM. Do sex steroids exert sex-specific and/or opposite effects on gene expression in lacrimal and meibomian glands? *Mol Vis* 2009;15:1553-1572.
- 33 Patterson M, Vogel HJ, Prenner EJ. The effect of repeated lateral compression and expansions mimicking blinking on selected tear film polar lipid monofilms. *Biochim Biophys Acta Biomembr* 2017;1859(3):319-330.
- 34 Butovich IA, Bhat N, Wojtowicz JC. Comparative transcriptomic and lipidomic analyses of human male and female meibomian glands reveal common signature genes of meibogenesis. *Int J Mol Sci* 2019;20(18):E4539.
- 35 Borchman D, Ramakrishnan V, Henry C, Ramasubramanian A. Differences in meibum and tear lipid composition and conformation. *Cornea* 2020;39(1):122-128.
- 36 Borchman D, Ramasubramanian A, Foulks GN. Human meibum cholesteryl and wax ester variability with age, sex, and meibomian gland dysfunction. *Invest Ophthalmol Vis Sci* 2019;60(6):2286-2293.
- 37 Chen JZ, Green KB, Nichols KK. Compositional analysis of wax esters in human meibomian gland secretions by direct infusion electrospray ionization mass spectrometry. *Lipids* 2016;51(11):1269-1287.
- 38 Joffe C, Souchier M, Grégoire S, Viau S, Bretillon L, Acar N, Bron AM, Creuzot-Garcher C. Differences in meibomian fatty acid composition in patients with meibomian gland dysfunction and aqueous-deficient dry eye. *Br J Ophthalmol* 2008;92(1):116-119.
- 39 Butovich IA, Lu H, McMahon A, Ketelson H, Senchyna M, Meadows D, Campbell E, Molai, Linsenbardt E. Biophysical and morphological evaluation of human normal and dry eye meibum using hot stage polarized light microscopy. *Invest Ophthalmol Vis Sci* 2014;55(1):87-101.
- 40 Rantamäki AH, Wiedmer SK, Holopainen JM. Melting points—the key to the anti-evaporative effect of the tear film wax esters. *Invest Ophthalmol Vis Sci* 2013;54(8):5211-5217.
- 41 Sullivan BD, Evans JE, Dana MR, Sullivan DA. Impact of androgen deficiency on the lipid profiles in human meibomian gland secretions. *Adv Exp Med Biol* 2002;506(Pt A):449-458.
- 42 Nicolaides N, Santos EC, Smith RE, Jester JV. Meibomian gland dysfunction. III. Meibomian gland lipids. *Invest Ophthalmol Vis Sci* 1989;30(5):946-951.
- 43 Driver PJ, Lemp MA. Meibomian gland dysfunction. *Surv Ophthalmol* 1996;40(5):343-367.
- 44 Bron AJ, Tiffany JM. The contribution of meibomian disease to dry eye. *Ocul Surf* 2004;2(2):149-165.
- 45 Lam SM, Tong L, Yong SS, Li B, Chaurasia SS, Shui G, Wenk MR. Meibum lipid composition in Asians with dry eye disease. *PLoS One* 2011;6(10):e24339.
- 46 Borchman D, Yappert MC, Foulks GN. Changes in human meibum lipid with meibomian gland dysfunction using principal component analysis. *Exp Eye Res* 2010;91(2):246-256.
- 47 Shrestha RK, Borchman D, Foulks GN, Yappert MC, Milliner SE. Analysis of the composition of lipid in human meibum from normal infants, children, adolescents, adults, and adults with meibomian gland dysfunction using <sup>1</sup>H-NMR spectroscopy. *Invest Ophthalmol Vis Sci* 2011;52(10):7350-7358.
- 48 Sledge S, Henry C, Borchman D, Yappert MC, Bhola R, Ramasubramanian A, Blackburn R, Austin J, Massey K, Sayied S, Williams A, Georgiev G, Schikler KN. Human meibum age, lipid-lipid interactions and lipid saturation in meibum from infants. *Int J Mol Sci* 2017;18(9):E1862.

- 49 Borchman D, Foulks GN, Yappert MC, Kakar S, Podoll N, Rychwalski P, Schwietz E. Physical changes in human meibum with age as measured by infrared spectroscopy. *Ophthalmic Res* 2010;44(1):34-42.
- 50 Borchman D, Yappert MC. Lipids and the ocular lens. *J Lipid Res* 2010;51(9):2473-2488.
- 51 Baudouin C, Messmer EM, Aragona P, Geerling G, Akova YA, Benítez-del-Castillo J, Boboridis KG, Merayo-Llodes J, Rolando M, Labetoulle M. Revisiting the vicious circle of dry eye disease: a focus on the pathophysiology of meibomian gland dysfunction. *Br J Ophthalmol* 2016;100(3):300-306.
- 52 Shine WE, McCulley JP. Association of meibum oleic acid with meibomian seborrhea. *Cornea* 2000;19(1):72-74.
- 53 Schirra F, Richards SM, Liu M, Suzuki T, Yamagami H, Sullivan DA. Androgen regulation of lipogenic pathways in the mouse meibomian gland. *Exp Eye Res* 2006;83(2):291-296.
- 54 Truong S, Cole N, Stapleton F, Golebiowski B. Sex hormones and the dry eye. *Clin Exp Optom* 2014;97(4):324-336.
- 55 Ding J, Liu Y, Sullivan DA. Effects of insulin and high glucose on human meibomian gland epithelial cells. *Invest Ophthalmol Vis Sci* 2015;56(13):7814-7820.
- 56 Schirra F, Suzuki T, Richards SM, Jensen RV, Liu M, Lombardi MJ, Rowley P, Treister NS, Sullivan DA. Androgen control of gene expression in the mouse meibomian gland. *Invest Ophthalmol Vis Sci* 2005;46(10):3666-3675.
- 57 Pochi PE, Strauss JS. Endocrinologic control of the development and activity of the human sebaceous gland. *J Invest Dermatol* 1974;62(3):191-201.
- 58 Hall JM, McDonnell DP. The estrogen receptor beta-isoform (ERbeta) of the human estrogen receptor modulates ERalpha transcriptional activity and is a key regulator of the cellular response to estrogens and antiestrogens. *Endocrinology* 1999;140(12):5566-5578.
- 59 Ding J, Sullivan DA. The effects of insulin-like growth factor 1 and growth hormone on human meibomian gland epithelial cells. *JAMA Ophthalmol* 2014;132(5):593-599.
- 60 Viso E, Rodríguez-Ares MT, Abelenda D, Oubiña B, Gude F. Prevalence of asymptomatic and symptomatic meibomian gland dysfunction in the general population of Spain. *Invest Ophthalmol Vis Sci* 2012;53(6):2601-2606.
- 61 Ibrahim MAA, Elwan WM. Role of topical dehydroepiandrosterone in ameliorating isotretinoin-induced meibomian gland dysfunction in adult male albino rat. *Anat Anzeiger: Off Organ Anat Gesellschaft* 2017;211:78-87.
- 62 Zeligs M, Gordon K. Dehydroepiandrosterone therapy for the treatment of dry eye disorders. WIPO Patent Application WO 1994:004155.
- 63 Sullivan DA, Rocha EM, Ullman MD, Krenzer KL, Gao J, Toda I, Dana MR, Bazzinotti D, da Silveira LA, Wickham LA. Androgen regulation of the meibomian gland. *Adv Exp Med Biol* 1998;438:327-331.
- 64 Worda C, Nepp J, Huber JC, Sator MO. Treatment of keratoconjunctivitis sicca with topical androgen. *Maturitas* 2001;37(3):209-212.
- 65 Bizzarro A, Valentini G, Di Martino G, DaPonte A, De Bellis A, Iacono G. Influence of testosterone therapy on clinical and immunological features of autoimmune diseases associated with Klinefelter's syndrome. *J Clin Endocrinol Metab* 1987;64(1):32-36.
- 66 Scott G, Yiu SC, Wasilewski D, Song J, Smith RE. Combined esterified estrogen and methyltestosterone treatment for dry eye syndrome in postmenopausal women. *Am J Ophthalmol* 2005;139(6):1109-1110.
- 67 Golebiowski B, Badarudin N, Eden J, Gerrand L, Robinson J, Liu JZ, Hampel U, You JJ, Stapleton F. The effects of transdermal testosterone and oestrogen therapy on dry eye in postmenopausal women: a randomised, placebo-controlled, pilot study. *Br J Ophthalmol* 2017;101(7):926-932.
- 68 Schiffman R, Bradford R, Bunnell B, Lai F, Bernstein P, Whitcup SW. A multi-center, double-masked, randomized, vehicle-controlled, parallel group study to evaluate the safety and efficacy of testosterone ophthalmic solution in patients with meibomian gland dysfunction. *Invest Ophthalmol Vis Sci* 2006;47(13):5608.
- 69 Goldman A, Basaria S. Adverse health effects of androgen use. *Mol Cell Endocrinol* 2018;464:46-55.