

Macular Bruch's membrane defects and other myopic lesions in high myopia

Li-Hui Meng^{1,2}, Ming-Zhen Yuan³, Xin-Yu Zhao^{1,2}, You-Xin Chen^{1,2}

¹Department of Ophthalmology, Peking Union Medical College Hospital, Chinese Academy of Medical Sciences, Beijing 100730, China

²Key Laboratory of Ocular Fundus Diseases, Chinese Academy of Medical Sciences & Peking Union Medical College, Beijing 100730, China

³Beijing Tongren Eye Center, Beijing Tongren Hospital, Capital Medical University, Beijing Ophthalmology and Visual Sciences Key Laboratory, Beijing 100730, China

Co-first authors: Li-Hui Meng and Ming-Zhen Yuan

Correspondence to: You-Xin Chen. Department of Ophthalmology, Peking Union Medical College Hospital, Beijing 100730, China. chenyx@pumch.cn

Received: 2020-09-05 Accepted: 2021-03-25

Abstract

• **AIM:** To compare the ocular fundus features of highly myopic eyes with and without macular Bruch's membrane (BM) defects and investigate the associations between macular BM defects and other myopic lesions.

• **METHODS:** This retrospective, observational case series included 262 eyes (139 patients) with high myopia (HM) refractive error ≥ -6.0 diopters (D) or axial length ≥ 26.5 mm from March 2019 to December 2019. The patients underwent a comprehensive ophthalmic examination, including swept-source optical coherence tomography (SS-OCT). The features of macular BM defects and other ocular fundus lesions were examined in OCT images.

• **RESULTS:** Totally 51 eyes (19.5%) were detected with macular BM defects, which were characterized by a lack of BM, retinal pigment epithelium (RPE), and an almost complete loss of photoreceptors or choriocapillaris. Eyes with macular BM defects had worse best-corrected visual acuity (BCVA) than those without ($P < 0.001$). Dome-shaped macula (DSM, $P = 0.042$), retinal cysts ($P = 0.006$), choroidal neovascularization (CNV, $P < 0.001$), choroidal defects and abnormality ($P = 0.003$), scleral defects ($P = 0.015$), scleral deformation ($P = 0.005$), posterior staphyloma ($P = 0.011$), and perforating vessels ($P < 0.001$) occurred more frequently in eyes with macular BM defects. In multivariate analysis, the presence of macular BM defects remained the significant

association with presence of DSM ($P = 0.013$), scleral defects ($P = 0.015$), posterior staphyloma ($P = 0.001$), perforating vessels ($P < 0.001$) and CNV ($P = 0.004$).

• **CONCLUSION:** Macular BM defects has a prevalence of approximately 20% in HM and it has tight association with other myopic fundus lesions. BM might be crucial in the pathogenesis of myopic fundus lesions due to its biomechanical function. A comprehensive understanding of BM's role is useful for further researches about myopic lesions.

• **KEYWORDS:** Bruch's membrane; high myopia; swept source optical coherence tomography

DOI:10.18240/ijo.2022.03.15

Citation: Meng LH, Yuan MZ, Zhao XY, Chen YX. Macular Bruch's membrane defects and other myopic lesions in high myopia. *Int J Ophthalmol* 2022;15(3):466-473

INTRODUCTION

Bruch's membrane (BM) is the barrier between the retinal pigment epithelium (RPE) and choriocapillaris, which may have biomechanical functions for supporting the form and shape of the globe in addition to the role of its spatial separation between retinal and choroidal compartment. In eyes with myopia, it is proposed that the axial elongation might occur by BM production in the retro-equatorial region^[1]. The prevalence of macular BM defects in highly myopic eyes were reported to be approximately 10%, and they may have tight associations with other chorioretinopathies^[2].

Several clinical or histological reports have concentrated on the associations between macular BM defects and other myopic lesions. For example, it is reported that the presence of macular BM defects was strongly associated with axial length and indirectly with BM opening around the optic nerve head^[3]. One histological study revealed the corrugation of BM in some eyes with extremely long axial length^[4]. In the aspect of chorioretinopathy, researchers have found that macular BM defects might be a hallmark in patchy atrophy or myopic-choroidal neovascularization (CNV) related foveal atrophy^[5-6]. The presence of dome-shaped macula (DSM) might be significantly associated with macular BM defects. Posterior scleral relaxation may no longer be pushed outward by the

expanded BM, but allows partial inward expansion to form DSM^[7]. Therefore, some ophthalmologists proposed the BM defects should be considered as a kind of feature in myopic retinopathy^[8].

BM defects might be caused by increased tension within BM^[1]. However, the exact mechanism behind has remained unclear by far. The myopization process and the pathogenesis of ocular fundus lesions in highly myopic eyes were elusive. Because no publications available have focused on the associations between macular BM defects and myopic fundus lesions from a comprehensive perspective by far, we used swept source optical coherence tomography (SS-OCT) comparing ocular fundus features in high myopia (HM) eyes with and without BM defects and investigate the associations between macular BM defects and other myopic related lesions. In recent years, SS-OCT has greatly enhanced our ability to observe the fine structures of vitreous, delineate the choroid and investigate the entire scleral thickness^[9]. We took the advantage of SS-OCT to explore the associations between BM defects and other HM-related lesions, hopefully providing a clue for researches in the future that is to illustrate the pathogenesis of lesions occurred in HM.

SUBJECTS AND METHODS

Ethical Approval This retrospective observational study was compliant with the tenets of the Declaration of Helsinki. The protocol got approval from the Ethics Committee (S-K631). This study included patients with HM who had consecutively been examined by SS-OCT in Ophthalmology Department of the Peking Union Medical College Hospital from March 2019 to December 2019.

Patients who met the following criteria were included: 1) confirmation of HM on the basis of myopic refractive error (spherical equivalent) ≥ -6.0 diopters (D) or axial length ≥ 26.5 mm; 2) receiving SS-OCT examination; 3) with detailed medical records and comprehensive ophthalmic examination. Patients with unclear OCT images due to opacities of the optic media and a history of vitreoretinal surgery, or those without sufficient medical data were excluded.

Comprehensive Ophthalmic Examination The participants underwent a comprehensive ophthalmologic examination, including best-corrected visual acuity (BCVA), intraocular pressure, slit-lamp examination, color fundus photograph and measurements of refractive errors. Myopic maculopathy was identified based on the META-PM classification system, including no myopic retinal lesions (category 0), tessellated fundus (category 1); diffuse chorioretinal atrophy (category 2); patchy chorioretinal atrophy (category 3); macular atrophy (category 4)^[8]. SS-OCT images were obtained with a prototype of an SS-OCT (VG200, Svision Imaging, Ltd., Luoyang, China), which owns an A-scan repetition rate of 200 000 Hz

and a tunable laser centered at 1050 nm as the light source. Its scanned line length was 16 mm. The scan depth was 2.7 mm. The real-time eye-tracking system was used to create a multi-averaged single image by averaging the 200 single images. Each participant acquired bilaterally SS-OCT images. Single line high definition mode, radial scan mode, multiple parallel line scan mode, and 3D stereo scan mode were used. For BCVA > 0.05 of the inspected eye, internal or central fixation was used. Elsewhere, external or non-central fixation was used.

Images Evaluation BM defects in the accessible range was evaluated by two examiners (Yuan MZ and Meng LH). Disagreements have been solved by consultation. The associations between the presence of macular BM defects and other lesions in the retina, choroid and sclera were analyzed. The retinoschisis was graded based on the location and the size as suggested by Shimada *et al*^[10]: in the extrafoveal region (S1); a foveal retinoschisis (S2); affected the foveal region, but not entire macula (S3); the entire macular region (S4). The posterior staphyloma was categorized into 6 types: wide macular staphyloma (type I); narrow macular staphyloma (type II); peripapillary staphyloma (type III); nasal staphyloma (type IV); inferior staphyloma (type V); staphylomas other than type I to V (others).

Statistical Analysis Statistical analyses were performed using SPSS software version 25.0 (SPSS, Inc). The BCVA was converted to the logarithm of the minimum angle of resolution (logMAR). First, the Mann-Whitney *U* test, the Chi-square test, or the Fisher exact test in a univariate analysis were used to compare the assessed parameters between two groups. In the second step, a binary Logistic regression analysis was performed, in which the dependent variable was presence of macular BM defects, and all those parameters that were significantly associated with the presence of macular BM defects were independent variables by stepwise method (Forward: LR). $P < 0.05$ was considered to have statistical significance.

RESULTS

Clinical Characteristics In total, 279 eyes (154 patients) with HM received SS-OCT examination from March 2019 to December 2019. Of these, 17 eyes (15 patients) were excluded, 6 eyes (6 patients) were due to a history of vitreoretinal surgery and 11 eyes (9 patients) were because of the poor-quality of OCT images resulting from media opacities. Eventually, 262 eyes of 139 patients were studied, including 102 women and 37 men. The mean age was 49.0 ± 16.2 y and ranged from 15 to 85y. The mean refractive error (spherical equivalent) was -10.9 ± 3.32 D and ranged from -6.0 to -22.0 D). The mean BCVA (logMAR) was 0.57 ± 0.48 and ranged from -0.08 to 2.00. The mean central retinal thickness (CRT), central choroidal thickness (CCT) and central scleral thickness (CST) was 205 ± 120 , 92.8 ± 75.8 and 395 ± 123 μ m, respectively.

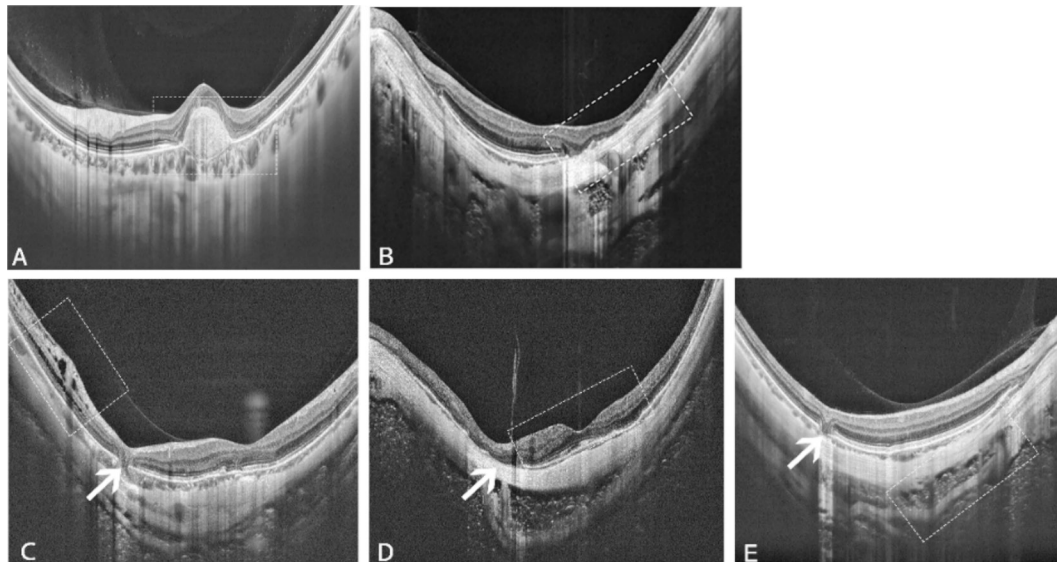


Figure 1 SS-OCT images of ocular fundus lesions (boxes) in high myopia with macular Bruch's membrane defects (arrows) A: Choroid neovascularization (CNV); B: Choroidal defects or atrophy; C: Retinoschisis; D: Oblique oval-shaped dome-shaped macula (DSM); E: Scleral splitting.

51 of 262 eyes (19.5%) were detected with macular BM defects, defined with a lack of BM, RPE, and almost complete loss of photoreceptors or choriocapillaris in some cases (Figure 1). The eyes with macular BM defects had significantly worse (0.787 ± 0.071) BCVA than those without BM defects (0.513 ± 0.032 , $P < 0.001$). There were no significant differences in age, refractive error, CRT, CCT or CST between eyes with and without macular BM defects (Table 1). According to META-PM classification, 119 eyes were category 1, 98 eyes were category 2, 29 eyes were category 3 and 16 eyes were category 4. Moreover, only 2 eyes in category 1 and 4 eyes in category 2 were detected with BM defects, while all eyes in category 3 and 4 have BM defects due to the atrophy (Figure 2). We found that four META-PM groups showed significant differences in the presence of BM defects ($P < 0.001$; Table 1). Additionally, the pairwise comparison suggested that except eyes between category 1 and 2 or eyes between category 3 and 4, all other pairs showed significant differences in the presence of BM defects ($P < 0.001$; Table 2).

Retinal Lesions In 51 eyes with macular BM defects, 12 eyes (23.5%) showed the presence of DSM with the mean macular height of $176.3 \pm 32.1 \mu\text{m}$. While in 211 eyes without macular BM defects, 24 eyes (11.4%) showed the presence of DSM with the mean macular height of $142.7 \pm 17.9 \mu\text{m}$. Twenty-three eyes (45.1%) with vitreomacular traction (VMT) were detected in those with macular BM defects, and 86 eyes (40.8%) were detected in those without BM defects. Twenty-five (49.0%) eyes were detected with retinoschisis in HM eyes with macular BM defects, whereas in those without, 85 eyes (40.3%) were detected. Retinal cysts were detected in 23 eyes (54.9%) with macular BM defects and 72 eyes (34.1%) of those without macular BM defects. Epiretinal membranes (ERM) were

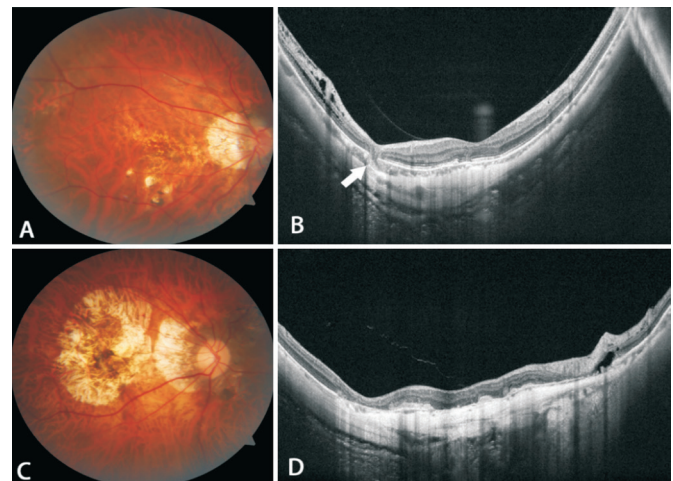


Figure 2 Bruch's membrane defects in different META-PM groups were demonstrated by color fundus photographs and SS-OCT images A-B: BM defects (arrow) in highly myopic eyes of category 2; C-D: Macular atrophy and diffuse macular BM defects in highly myopic eyes of category 4.

observed in 10 eyes (19.6%) with macular BM defects and 20 eyes (9.5%) without macular BM defects. Besides, three eyes (8.0%) with macular BM defects were detected with parapaillary retinal cavitation and 18 eyes (8.5%) without macular BM defects were detected. DSM ($P = 0.042$) and retinal cysts ($P = 0.006$) had significant association with macular BM defects presence. Other assessed parameters, including DSM macular height, the presence of VMT, retinoschisis, ERM and parapaillary retinal cavitation had no significant differences between each other. The specific information of DSM types and retinoschisis grading and other important values were demonstrated in Table 3.

Choroidal Lesions Totally 40 eyes (78.4%) with macular BM defects were accompanied with CNV, of which 29 (56.9%) were

Table 1 Clinical features of highly myopic eyes with and without macular BM defects

Characteristics	Macular BM defects		P	
	Present	Absent	Univariate ^a	Multivariate
No. of eyes (%)	51 (19.5)	211 (80.5)	-	-
Age (y)				
Mean±SD	48.9±2.25	48.8±1.12	0.993	-
Range	19-76	15-85		
BCVA (logMAR)				
Mean±SD	0.787±0.071	0.513±0.032	<0.001	0.347
Range	-0.08-1.70	-0.08-2.00		
Refractive error (D)				
Mean±SD	12.0±0.441	10.9±0.231	0.655	-
Range	6.00-18.0	6.00-22.0		
CRT				
Mean±SD	249±25.5	194±6.66	0.144	-
Range	0-795	0-722		
CCT				
Mean±SD	87.2±77.6	93.5±5.21	0.579	-
Range	0-376	0-497		
CST				
Mean±SD	417±15.7	389±8.62	0.117	-
Range	171-715	150-792		
META-PM classification (%)			<0.001 ^b	-
Category 1	2 (3.9)	117 (55.5)		
Category 2	4 (7.8)	94 (44.5)		
Category 3	29 (56.9)	0		
Category 4	16 (31.4)	0		

BCVA: Best corrected visual acuity; BM: Bruch's membrane; CRT: Central retinal thickness; CCT: Central choroidal thickness; CST: Central scleral thickness; D: Diopter; logMAR: Logarithm of the minimum angle of resolution; SD: Standard deviation. ^aMann-Whitney U test; ^bFisher exact test.

Table 2 Pairwise comparison of BM defects in different META-PM groups of high myopia eyes

META-PM groups	P
Category 1 vs 2 ^b	0.413
Category 1 vs 3 ^a	<0.001
Category 1 vs 4 ^b	<0.001
Category 2 vs 3 ^a	<0.001
Category 2 vs 4 ^b	<0.001
Category 3 vs 4	-

^aChi-square test; ^bFisher exact test.

at active phase, 4 (7.8%) were at scar phase, and 7 (13.7%) were at atrophic phase. And 21 eyes (10.0%) without macular BM defects were accompanied with CNV, of which 11 (5.2%) were at active phase, 7 (3.3%) were at scar phase and 3 (1.4%) were at atrophic phase. Five eyes (9.8%) with macular BM defects were detected with intrachoroidal cavitation (ICC), whereas 9 eyes (4.3%) without macular BM defects were detected. Choroidal defects or abnormality of choroidal vasculature were detected in 8 eyes (15.7%) with macular BM defects and 7 eyes (3.3%) without macular BM defects respectively. Presence of CNV and choroidal defects/abnormality had significant association with macular BM defects ($P<0.001$ and $P=0.003$ respectively).

However, there were no significant differences about the presence of ICC between each other (Table 4).

Scleral Lesions Ten eyes (19.6%) with macular BM defects were detected with scleral splitting and 25 (11.8%) were detected in eyes without macular BM defects. Four eyes (9.8%) with macular BM defects were accompanied with scleral defects and 3 eyes (1.4%) without macular BM defects. The abnormal shape of sclera was detected in 13 eyes (25.5%) with macular BM defects and 22 eyes (10.4%) without macular BM defects, in which scleral depression was observed in 12 eyes (23.5%) with macular BM defects and 14 eyes (6.6%) without macular BM defects, as well as scleral uneven thickness was observed in 12 eyes (23.5%) with macular BM defects and 15 eyes (7.1%) without macular BM defects. Posterior staphylomas were observed in 11 eyes (21.6%) and 19 eyes, besides, intrascleral vessels were observed in 33 eyes (64.7%) with macular BM defects and 2 eyes (0.9%) without macular BM defects. The presence of scleral defects, posterior staphyloma and scleral perforating vessels had significant association with macular BM defects ($P=0.015$, 0.011 , and <0.001 respectively). Also, the scleral abnormal shape was significantly more common in eyes with macular BM defects

Table 3 Retinal features in highly myopic eyes with and without macular BM defects n (%)

Characteristics	Macular BM defects		P	
	Absent	Present	Univariate	multivariate
No. of eyes	211	51	-	-
DSM	24 (11.4)	12 (23.5)	0.042 ^b	0.013
DSM macular height (µm)				
Mean±SD	142.7±17.9	176±32.1	0.240 ^a	-
Range	59.0-416	65.7-485		
DSM types				
Round	5 (2.4)	4 (7.8)	0.075 ^c	-
Horizontal	13 (6.2)	4 (7.8)	0.751 ^c	-
Vertical	5 (2.4)	3 (5.9)	0.189 ^c	-
Oblique/others	1 (0.5)	1 (2)	0.352 ^c	-
VMT	86 (40.8)	23 (45.1)	0.573 ^b	-
Retinoschisis	85 (40.3)	25 (49.0)	0.257 ^b	-
S1	31 (14.7)	6 (11.8)	0.590 ^b	-
S2	8 (3.8)	3 (5.9)	0.452 ^c	-
S3	35 (16.6)	14 (27.5)	0.074 ^b	-
S4	11 (5.2)	2 (3.9)	1 ^c	-
Retinal cysts	72 (34.1)	23 (54.9)	0.006 ^b	0.284
ERM	20 (9.5)	10 (19.6)	0.073 ^b	-
Paprapapillary retinal cavitation	18 (8.5)	3 (8.0)	0.774 ^c	-

BM: Bruch's membrane; DSM: Dome shaped macula; ERM: Epiretinal membrane; SD: Standard deviation; S1-S4: Grades of retinoschisis; VMT: Vitreomacular traction. ^aMann-Whitney U test; ^bChi-square test; ^cFisher test.

Table 4 Choroidal and scleral features in eyes with and without myopic BM defects n (%)

Characteristics	Myopic BM defects		P	
	Absent	Present	Univariate	Multivariate
No. of eyes	211	51	-	-
CNV	21 (10.0)	40 (78.4%)	<0.001 ^a	0.004
Active	11 (5.2)	29 (56.9)	<0.001 ^a	-
Scar	7 (3.3)	4 (7.8)	0.233 ^b	-
Atrophic	3 (1.4)	7 (13.7)	0.001 ^b	-
ICC	9 (4.3)	5 (9.8)	0.157 ^b	-
Choroidal defects/abnormality	7 (3.3)	8 (15.7)	0.003 ^b	0.171
Scleral splitting	25 (11.8)	10 (19.6)	0.144 ^a	-
Scleral defect	3 (1.4)	4 (9.8)	0.015 ^b	0.015
Scleral abnormal shape	22 (10.4)	13 (25.5)	0.005 ^a	0.264
Depression	14 (6.6)	12 (23.5)	<0.001 ^a	-
Uneven thickness	15 (7.1)	12 (23.5)	0.001 ^a	-
Posterior staphyloma	19 (9.0)	11 (21.6)	0.011 ^a	0.001
Type 1	2 (0.9)	3 (5.9)	-	-
Type 2	15 (7.1)	7 (13.7)	-	-
Type 3	0	0	-	-
Type 4	1 (0.5)	0	-	-
Type 5	0	0	-	-
Others	1 (0.5)	1 (2.0)	-	-
Scleral perforating vessels	2 (0.9)	33 (64.7)	<0.001 ^a	<0.001

BML: Bruch's membrane; CNV: Choroidal neovascularization; ICC: Intrachoroidal cavitation. ^aChi-square test; ^bFisher test.

($P=0.005$), as well as the subgroups (depression and uneven thickness, $P=0.001$ and 0.011 respectively). Scleral splitting was more common in those with macular BM defects, but there was no significant difference (Table 4).

Other Accompanying Lesions Totally 41 (80.4%) of 51 with macular BM defects were accompanied by BM depression. While in those without macular BM defects, only one eye was accompanied with BM depression. In those 41 had both

macular BM defects and depression, 38 eyes (92.7%) were accompanied with CNV.

Results of the Multivariate Binary Regression Analysis

The results of multivariable binary regression analysis revealed that the presence of macular BM defects was remained to be significantly associated with presence of a DSM ($P=0.013$), scleral defects ($P=0.015$), posterior staphyloma ($P=0.001$), scleral perforating vessels ($P<0.001$), the presence of CNV ($P=0.004$). And the other variables including logMAR ($P=0.347$), retinal cysts ($P=0.284$), choroidal defects and abnormality of vasculature ($P=0.171$) and scleral deformation ($P=0.264$) had no significant associations with macular BM defects in stepwise multivariate regression analysis (Tables 1, 3, and 4).

DISCUSSION

This retrospective observation study compared features of HM eyes with and without macular BM defects, suggesting that there might be close relationships between macular BM defects and other myopic lesions. BM is composed of five layers, including the basal membrane of the RPE on its inner side, inner collagenous layer, elastic layer, outer collagenous layer and the basal membrane of the choriocapillaris on its outer side. The unique localization, structure and molecular composition of BM makes it responsible for diffusion regulation, physical support for RPE and division barrier which restricted choroidal and retinal cellular migration^[11]. These special characteristics of BM might determine its crucial role in pathogenesis of ocular fundus lesions in HM.

In our study, macular BM defects had significant association with the presence of DSM, scleral defects, posterior staphyloma, scleral perforating vessels and CNV in multivariate analysis. DSM, which demonstrated as an inward protrusion of the macula, has unclear pathogenesis by far^[12]. Some researchers proposed the DSM was due to the local thickening of the subfoveal sclera^[13]. While another study reported that macular BM defects might be an element of the formation of DSM. BM has elastin and collagenous components, which could bring some biomechanical properties on the basis of strength in stress and strain. The central area might be released from biomechanical forces then causing slightly bulging inward. Because of its continuity of BM, defects in any place of the posterior pole, may release the forces of the ocular ball, thus changing the macular shape^[7]. Our study observed the significant associations between the presence of macular BM defects and DSM, strengthening the hypothesis of important role of macular BM defects in the pathogenesis of DSM formation.

Posterior staphyloma, characterized by an outpouching of the posterior wall with a curvature radius smaller than that of surrounding wall, is a hallmark of pathologic myopia (PM)^[14].

However, the etiology of posterior staphyloma is unclear. It is assumed that local choroidal factors and a locally decreased biomechanical resistance of the sclera against a posteriorly expanding BM might be the pathogenic parameters^[15]. One hypothesis proposed that, BM, but not the sclera, is the major structure which elongates the globe. This could be an explanation for the obviously choroidal thinning in particular at the posterior pole because of the posteriorly expanding BM. Local reduction of scleral biomechanical resistance might be associated with the disarrangement of the scleral collagen fibers and other factors. BM is an extracellular matrix, which predominantly has collagenous component. Therefore, BM defects might be related to collagenous abnormality, the same with the disarrangement of the scleral collagen fibers. Besides, significant associations between scleral and BM defects also indicated the possible function of BM in the scleral remodeling mechanism.

CNV is a process whereby new vessels sprout from the choroid and penetrate into BM. One previous study reported that macular BM defects occurred less frequently after intravitreal injections' therapy^[6]. The results of significant associations between BM defects and the presence of CNV in our study were consistent with this former conclusion. One of the substantial PM features is the utmost thinning of the choroid, and even almost complete absence with several large vessels left sporadically in some cases. Thus, it is intriguing that why CNV could develop from such kind of choroid tissue. One study suggested that in some myopic eyes intrascleral vessels and CNV seemed continuous *via* BM defects^[16]. Our results showed the significant association between the presence of macular BM defects and CNV/perforating scleral vessels respectively. This finding confirmed the previous deduction from another perspective. All these findings indicate that the myopic CNV could originate from deeply situated scleral vessels at least in some cases, especially in those with extreme thin choroid.

In our study, macular BM defects have indirect association with lower BCVA, retinal cysts, choroidal defects or abnormality of choroidal vasculature, and scleral deformity. First, eyes with macular BM defects had much worse BCVA, which was consistent with the previous results^[2]. The marked reduction in central visual acuity might be due to the loss of RPE and choriocapillaris in that region. Second, there was a higher prevalence of retinal cysts in those with macular BM defects. Retinal cysts are similar to retinoschisis in clinical manifestations and pathology, but the specific mechanisms were unknown and might be due to the age, trauma, vitreoretinal traction and retinal detachment. In our results, the higher prevalence of retinal cysts in highly myopic eyes with macular BM defects, made one infer that BM might participate

in the pathogenesis of the retinal cysts. Third, choroidal defects and abnormal vasculature were more frequently to be observed in highly myopic eyes with macular BM defects. As is known, the choroid is of paramount importance to retinal and visual function because it supplies nutrients to RPE cells and the outer retina. In our results, choroidal circulation was much more compromised in highly myopic eyes with macular BM defects, which might account for the reason why eyes with macular BM defects had more retinal lesions such as cysts and terrible visual acuity. The association between BM defects and choroidal defects or abnormal vasculature might be due to the structural connections. The outset layer of BM comprises the basal membrane of choriocapillaris. Therefore, BM seems to be more inclined to be damaged in the case of choroidal defects or abnormal vasculature. In addition, scleral deformation was more common in highly myopic eyes with macular BM defects. In some cases with HM, the curvature of the posterior eye segment was totally irregular and not spherical at all^[17]. And it was reported that patients with irregular curvature had significantly longer axial lengths and more myopic fundus lesions^[18]. This might be tightly associated with the dysregulation of sclera, which has been thought as the mainstay of the normal global shape. However, in recent years, evidences have showed the marked changes of BM in highly myopic eyes might play an important role in the pathogenesis of axial elongation due to its potential biomechanical functions^[1]. Thus, the associations between macular BM defects and scleral deformity, including posterior staphyloma according to our results, suggested that the mechanism of myopization was a process by multiple factors and the biomechanical changes might matter a lot to the pathogenesis of ocular fundus lesions.

However, we did not find significant associations between the presence of BM defects and VMT, retinoschisis, ERM, parapapillary retinal cavitation, ICC and scleral splitting. The occurrence of myopic traction maculopathy, including VMT, retinoschisis, ERM, is greatly influenced by the status of posterior vitreous. Therefore, the associations between BM and these lesions might be loose. ICC was a schisis within the choroid, which appeared as deep hyporeflectivity in the OCT and separated the RPE from the sclera^[19-20]. The development of ICC might facilitate the mechanic dissociation of the retinal tissue in those areas where the attachment between inner retina and outer sclera is considered to be weak^[21]. Also, intra retinal cavitation and scleral splitting were mechanic dissociations. Despite these negative results, BM defects might be still an important factor that was associated with the biomechanical maintenance of the posterior ocular wall, in addition to other factors like size and chorioretinal atrophy's location, biomechanical parameters of the sclera, intraocular

asymmetries in axial elongation and orbital pressure changes. Noteworthy, we found that 41 (80.4%) of 51 eyes with BM defects were accompanied with BM depression. And 38 (92.7%) of them were accompanied with the presence of CNV. We inferred that in cases with CNV, the depression of BM defects might be due to the press produced by the new vessels above the BM. And in another three cases, the depression might be due to the interruption to the tension and strength as a result of the defects. This phenomenon might make an attempt to be correlated with the corrugation of BM in a histologic study^[4]. However, whether this connection could be built still needs experimental studies.

There are several limitations in this study. First, the axial length which is greatly important to myopia-related study, was not obtained in all participants, consequently restricting us to conduct further statistical analysis. Second, all the participants came from a tertiary, multi-specialty referral hospital. Therefore our results might not reflect the tendency in the general HM population. Third, though this prototype OCT had increased scan width and depth of this prototype OCT, extreme large staphylomas extending even deeper than 2.7 mm may not have been detected. Therefore, staphylomas might be overlooked in some eyes. Last, the sample size was relative small when investigating the differences of some lesions, such as ICC, between eyes with and without BM defects, thus limiting the interpretation of our results. To further explore the complex pathophysiologic mechanisms of these lesions and their associations with BM defects, studies with large sample size or prospective nature are needed.

In conclusion, this study demonstrated that BM defects had a prevalence of approximately 20% in HM and might be tightly associated with other myopic fundus lesions, including DSM, scleral defects, posterior staphyloma, scleral perforating vessels and CNV. The exact role of BM in the pathogenesis of myopia and related lesions should be valued and the findings in our study need more in-depth researches to validate.

ACKNOWLEDGEMENTS

Conflicts of Interest: Meng LH, None; Yuan MZ, None; Zhao XY, None; Chen YX, None.

REFERENCES

- Jonas JB, Ohno-Matsui K, Jiang WJ, Panda-Jonas S. Bruch membrane and the mechanism of myopization: a new theory. *Retina* 2017;37(8):1428-1440.
- You QS, Peng XY, Xu L, Chen CX, Wei WB, Wang YX, Jonas JB. Macular bruch membrane defects in highly myopic eyes: the Beijing eye study. *Retina* 2016;36(3):517-523.
- Jonas JB, Ohno-Matsui K, Spaide RF, Holbach L, Panda-Jonas S. Macular bruch's membrane defects and axial length: association with gamma zone and delta zone in peripapillary region. *Invest Ophthalmol Vis Sci* 2013;54(2):1295.

- 4 Jonas JB, Jonas RA, Ohno-Matsui K, Holbach L, Panda-Jonas S. Corrugated Bruch's membrane in high myopia. *Acta Ophthalmol* 2018;96(2):e147-e151.
- 5 Ohno-Matsui K, Jonas JB, Spaide RF. Macular bruch membrane holes in highly myopic patchy chorioretinal atrophy. *Am J Ophthalmol* 2016;166:22-28.
- 6 Ohno-Matsui K, Jonas JB, Spaide RF. Macular bruch membrane holes in choroidal neovascularization-related myopic macular atrophy by swept-source optical coherence tomography. *Am J Ophthalmol* 2016;162:133-139.e1.
- 7 Fang YX, Jonas JB, Yokoi T, Cao KJ, Shinohara K, Ohno-Matsui K. Macular Bruch's membrane defect and dome-shaped macula in high myopia. *PLoS One* 2017;12(6):e0178998.
- 8 Ohno-Matsui K, Kawasaki R, Jonas JB, et al. International photographic classification and grading system for myopic maculopathy. *Am J Ophthalmol* 2015;159(5):877-883.e7.
- 9 Ng DSC, Cheung CYL, Luk FO, Mohamed S, Brelen ME, Yam JCS, Tsang CW, Lai TYY. Advances of optical coherence tomography in myopia and pathologic myopia. *Eye (Lond)* 2016;30(7):901-916.
- 10 Shimada N, Tanaka Y, Tokoro T, Ohno-Matsui K. Natural course of myopic traction maculopathy and factors associated with progression or resolution. *Am J Ophthalmol* 2013;156(5):948-957.e1.
- 11 Booi JC, Baas DC, Beisekeeva J, Gorgels TGMF, Bergen AAB. The dynamic nature of Bruch's membrane. *Prog Retin Eye Res* 2010;29(1):1-18.
- 12 Caillaux V, Gaucher D, Gualino V, Massin P, Tadayoni R, Gaudric A. Morphologic characterization of dome-shaped macula in myopic eyes with serous macular detachment. *Am J Ophthalmol* 2013;156(5):958-967.e1.
- 13 Imamura Y, Iida T, Maruko I, Zweifel SA, Spaide RF. Enhanced depth imaging optical coherence tomography of the sclera in dome-shaped macula. *Am J Ophthalmol* 2011;151(2):297-302.
- 14 Shinohara K, Shimada N, Moriyama M, Yoshida T, Jonas JB, Yoshimura N, Ohno-Matsui K. Posterior staphylomas in pathologic myopia imaged by widefield optical coherence tomography. *Invest Ophthalmol Vis Sci* 2017;58(9):3750-3758.
- 15 Ohno-Matsui K, Jonas JB. Posterior staphyloma in pathologic myopia. *Prog Retin Eye Res* 2019;70:99-109.
- 16 Ishida T, Watanabe T, Yokoi T, Shinohara K, Ohno-Matsui K. Possible connection of short posterior ciliary arteries to choroidal neovascularisations in eyes with pathologic myopia. *Br J Ophthalmol* 2019;103(4):457-462.
- 17 Ohno-Matsui K. Complicated mechanism for axial elongation in eyes with pathologic myopia accompanying scleral thinning and deformity. *Graefes Arch Exp Clin Ophthalmol* 2013;251(9):2279.
- 18 Ohno-Matsui K, Akiba M, Modegi T, Tomita M, Ishibashi T, Tokoro T, Moriyama M. Association between shape of sclera and myopic retinochoroidal lesions in patients with pathologic myopia. *Invest Ophthalmol Vis Sci* 2012;53(10):6046-6061.
- 19 Spaide RF, Akiba M, Ohno-Matsui K. Evaluation of peripapillary intrachoroidal cavitation with swept source and enhanced depth imaging optical coherence tomography. *Retina* 2012;32(6):1037-1044.
- 20 Ohno-Matsui K, Shimada N, Akiba M, Moriyama M, Ishibashi T, Tokoro T. Characteristics of intrachoroidal cavitation located temporal to optic disc in highly myopic eyes. *Eye (Lond)* 2013;27(5):630-638.
- 21 Ohno-Matsui K, Akiba M, Moriyama M, Ishibashi T, Hirakata A, Tokoro T. Intrachoroidal cavitation in macular area of eyes with pathologic myopia. *Am J Ophthalmol* 2012;154(2):382-393.