

Various phenotypes of autosomal dominant cone-rod dystrophy with cone-rod homeobox mutation in two Chinese families

Hui Cui¹, Xin Jin¹, Qing-Hua Yang¹, Ling-Hui Qu², Bao-Ke Hou¹, Zhao-Hui Li¹, Hou-Bin Huang^{1,3}

¹Senior Department of Ophthalmology, the Third Medical Center of PLA General Hospital, Beijing 100853, China

²Department of Ophthalmology, the 74th Army Group Hospital, Guangzhou 510318, Guangdong Province, China

³Department of Ophthalmology, Hainan Hospital of Chinese PLA General Hospital, Sanya 572000, Hainan Province, China

Co-first authors: Hui Cui, Xin Jin, and Qing-Hua Yang

Correspondence to: Hou-Bin Huang. Senior Department of Ophthalmology, the Third Medical Center of PLA General Hospital, Beijing 100853, China. 536273642@qq.com; huanghoubin@hotmail.com

Received: 2022-02-17 Accepted: 2022-09-13

Abstract

• **AIM:** To present the clinical manifestations of 5 autosomal dominant cone-rod dystrophy (adCORD) patients from two Chinese families with cone-rod homeobox (CRX) mutation (p.R41W), and to explore the clinical heterogeneity of adCORD with CRX mutation (p.R41W).

• **METHODS:** Interrogation and ophthalmological examinations were undertaken in all patients and unaffected members. Analysis of clinical features was performed by visual acuity, slit lamp examination, visual field examination, funduscopy, autofluorescence and spectral domain optical coherence tomography. Targeted next-generation sequencing was applied as a useful tool to identify the causative mutation of CORD genes.

• **RESULTS:** A CRX missense mutation c.121C>T was identified in all patients, resulting in an amino acid change from arginine acid to tryptophan (p.R41W). The patients presented with early onset, progressive and different severities with CORD.

• **CONCLUSION:** This is the first report of the clinical phenotype of CRX mutation (p.R41W) in Chinese families, and the mutation can lead to a wide range of various retinal phenotypes.

• **KEYWORDS:** cone-rod homeobox; cone-rod dystrophy; mutation

DOI:10.18240/ijo.2022.12.04

Citation: Cui H, Jin X, Yang QH, Qu LH, Hou BK, Li ZH, Huang HB. Various phenotypes of autosomal dominant cone-rod dystrophy with cone-rod homeobox mutation in two Chinese families. *Int J Ophthalmol* 2022;15(12):1915-1923

INTRODUCTION

Cone-rod dystrophy (CORD) is a rare inherited retinal degenerative disease, that affects approximately 1:30 000-1:40 000 individuals^[1]. The main clinical symptoms include photophobia, central vision failure and color vision disturbance caused by the initial degeneration of cone photoreceptors with progressive rod involvement. The macular impairment in CORD varies from normal to either a bull's eye lesion or total atrophy, and the corresponding visual function is also very different. However, the devastating professional and social implications of legal blindness in CORD patients of working age can be ignored. The inheritance pattern of CORD includes autosomal recessive (ar), autosomal dominant (ad) and X-linked (xl). Approximately 2/3 reveal autosomal recessive inheritance and the remaining 1/3 are close to autosomal dominantly inherited, as X-linked inheritance is rare^[2]. To date, more than 30 causative genes have been found, and several genes have been reported to be associated with autosomal dominant CORD (CORD2)^[3]. (RetNet: <https://sph.uth.edu/RetNet/> Last updated January 7, 2022).

The cone-rod homeobox (CRX) gene (602225) was first mapped and identified to cause CORD in 1994^[4]. It was identified and termed the "cone-rod homeobox-containing gene" in 1997^[5]. The CRX gene was expressed richly in photoreceptors of the postmitotic developing and mature stage, but poorly in retinal bipolar cells and pinealocytes^[6]. There were over 90 variants associated with different phenotypes of inherited retinal dystrophies. A heterozygous mutation in the CRX gene causing CORD is labelled the CORD2 (120070), which is inherited through autosomal display patterns^[7]. Heterozygous or homozygous mutation of the CRX gene resulting in Leber congenital amaurosis was labelled Leber congenital amaurosis 7 (LCA7, 613829). In rare cases, the CRX gene is involved in autosomal-dominant

retinitis pigmentosa (RP)^[8]. Although the three diseases are phenotypically and genetically heterogeneous, CRX is the only gene involved in all three, suggesting its crucial role in the integrity of rod and cone photoreceptors.

Here, we report the clinical phenotypes of five patients with CORD2 in two Chinese families. All patients had the heterozygous mutation CRX c.121C>T p.Arg41Trp, which was identified by targeted next-generation sequencing (NGS). Our findings first demonstrated the clinical features of CRX (p.R41W) in Chinese patients, which might indicate the prognosis of Chinese patients with the same genotype.

SUBJECTS AND METHODS

Ethical Approval The study was performed in adherence with the Declaration of Helsinki. Institutional review board approval and patients' informed consent were obtained.

Patients Our study included 5 patients who were investigated at the Department of Ophthalmology, General Hospital of the Chinese People's Liberation Army. Patient 1, patient 2 and patient 3 were from family 1 and patient 4 and patient 5 were from family 2. After clinical diagnosis of CORD, molecular screening was performed. All members underwent family history assessment and other associated genetic counselling, including the asymptomatic relatives of index patients. Incest marriage was not found in either family.

Image Acquisition and Functional Testing The assessment of ophthalmology included best corrected visual acuity (BCVA), slit lamp inspection of the anterior segment and fundus examination after pupil dilation in cases. Image acquisition mainly included spectral domain optical coherence tomography (SD-OCT; Carl Zeiss Meditec, Dublin, CA, USA), fundus autofluorescence (FAF) imaging (Spectralis HRA; Heidelberg Engineering, Heidelberg, Germany), and fundus photography (KOWA VX-20, Kowa Company, Chofu Factory, Japan).

Molecular Genetic Analysis Genomic DNA was extracted from blood lymphocytes according to a standard procedure. NGS was carried out for 463 ophthalmic disease-associated genes (designed by MyGenostics, Baltimore, MD), which covered 37 CORD associated genes (AIPL1, CRX, GUCA1A, GUCY2D, PITPNM3, PROM1, PRPH2, RIMS1, SEMA4A, UNC119, ABCA4, ADAM9, ATF6, C21orf2, C8orf37, CACNA2D4, CDHR1, CERKL, CNGA3, CNGB3, CNNM4, GNAT2, KCNV2, PDE6C, PDE6H, POC1B, RAB28, RAX2, RDH5, RPGRIP1, TTLL5, CACNA1F, RPGR, CEP78, DYNC2I2, IFT81, SLC4A7). The processes of specific high-throughput sequencing were described in some published literatures^[9-11]. The variation detected by NGS was validated by Sanger sequencing.

RESULTS

Ocular, Medical, and Family Histories Five affected patients from two Chinese families with a clinical diagnosis of CORD

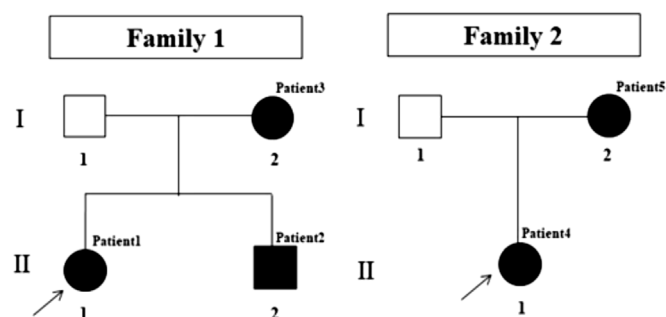


Figure 1 Identification of the heterozygous mutation c.121C>T (p.R41W) in CRX in two Chinese families with adCORD. Squares indicate males and circles indicate females. Empty symbols and filled symbols represent the normal and affected individuals, respectively. The black arrow indicates the proband. CXR: Cone-rod homeobox; adCORD: Autosomal dominant cone-rod dystrophy.

and the same mutation in CRX were identified in our study. The detailed demographic information is provided in Table 1, and the pedigrees of the two families are shown in Figure 1.

Patient 1 was diagnosed with CORD when she felt mild nyctalopia with no vision sharp one year ago. She found it difficult to ride on a bicycle at night and was once diagnosed with macular abnormalities in a local hospital. Then she came to our hospital and was inspected for color vision disturbance. Patient 2 was the younger brother of patient 1, and patient 3 was the mother of patient 1 and patient 2 (from family 1), both of whom reported no visual complaints. Although there was poor vision, patient 3 did not think it affected her daily life and had no eye consultation until her daughter was diagnosed with CORD. Her parents and brothers had no vision complaints, and no family history of ocular or visual problems.

Both patient 4 and patient 5 came from family 2, and patient 4 was the daughter of patient 5. The 14-year-old girl was found to have poor vision acuity during a school vision screening since two years ago and her poor eyesight had never been completely correctable with glasses reported. Her mother initially had ignored it until the little girl kept complaining she could not see the blackboard clearly. Night blindness was not noted at the time of clinical visit or in the ocular history. Patient 5 had never felt any vision problems, and her other family members were noncontributory. Undilated direct ophthalmoscopy was performed on both fathers from two families and no abnormalities were found.

Clinical Examination As the proband of family 1, patient 1 started her night blindness one year ago, and maintained normal BCVA at present. Her color fundus photographs revealed normal macular and optic nerves without apparent vessel attenuation and parapapillary atrophy, as shown in Figure 2A. However, in the SD-OCT demonstrated in Figure 3A, we found an irregular loss of the external limiting membrane (ELM), inner segment ellipsoid (ISE) and

Table 1 Demographics and detected variants in 5 Chinese patients from 2 families with CRX-associated CORD

Family No.	Patient No.	Sex	Age (at latest examination)	Onset	Chief complaint	Refractive errors		BCVA		Phenotype subgroup	Molecularly raised inheritance	CRX variants
						RE (dioptre)	LE (dioptre)	RE	LE			
1	Patient 1 (1-II:1)	F	23	22	Mild night blindness	-1.00 DS/-0.50 DC×5	-0.75 DS/-0.50 DC×180	1.0	1.0	CORD	AD	c.121C>T, p.R41W
1	Patient 2 (1-II:2)	M	19	19	No symptoms	-2.75 DS/-2.50 DC×180	-1.25 DS/-5.00 DC×180	0.4	0.5	CORD	AD	c.121C>T, p.R41W
1	Patient 3 (1-I:2)	F	46	NA	Reduced visual acuity	0	0	0.06	0.06	CORD	AD	c.121C>T, p.R41W
2	Patient 4 (2-II:1)	F	14	12	Reduced visual acuity	NA	NA	0.1	0.1	CORD	AD	c.121C>T, p.R41W
2	Patient 5 (2-I:2)	F	43	43	No symptoms	0	0	1.0	1.0	CORD	AD	c.121C>T, p.R41W

CRX: Cone-rod homeobox; AD: Autosomal dominant; BCVA: Best-corrected visual acuity; CORD: Cone-rod dystrophy; F: Female; M: Male; NA: Not available; RE: Right eye.

interdigitation zone (IZ). Corresponding to the visual field, patient 1 presented central scotoma and paracentral scotoma in Octopus (G Standard/White/White/4000/III TOP program; OCTOPUS 900), which was obtained from another hospital (Figure 4).

Patient 2 had moderate vision loss with serious astigmatism in both eyes, with BCVA hovering over 0.4-0.5, as described in Table 1. Similar to his sister, he had a roughly normal fundus with no obvious macular lesions on fundus photograph (Figure 2B). However, in SD-OCT, we found irregular loss of the outer retina, including the ELM, ISe, and IZ. The choroid layer was thinner than that of patient 1, which might be partly related to his refractive errors (Figure 3B).

Patient 3 had lived with poor eyesight for a long time, and was almost blind (0.06 in both eyes). Her fundus symptoms were quite typical, with evident atrophic lesions of an oval shape in the fovea (Figure 2C). Figure 5 shows the color fundus photographs, FAF and SD-OCT of both eyes from patient 3. Similar to the fundus photograph, the macular lesion surrounding the obvious boundary is symmetric in FAF, with the boundary considered as a band: the outside line of the band was slightly higher than the normal fluorescence (hyper-AF) approaching the vascular arc. The inside line of the band was the low fluorescence (hypo-AF) lesion, and there was an extremely hypo-AF lesion in the center of the fovea. In the cross section, the severe macular lesion on SD-OCT (Figures 3C and 5C) was more intuitive, with the almost total loss of ELM, ISe, and IZ and the markedly atrophied retinal pigment epithelium (RPE) and choroid, which was consistent with her poor vision. Unfortunately, patient 3 did not complete visual field testing because of poor vision and fixation instability.

Patient 4 was the proband of family 2, remaining at 0.1 at present with a gradual loss of eyesight for two years. We found a few small drusenoid lesions in her fundus through the enlarged image on the display screen, which was mild and indistinct surrounding the fovea (Figure 2D). The SD-OCT of macular central fovea presented an abnormal deficit of ISe and IZ, but a nearly intact ELM (Figure 3D). More details on different horizontal SD-OCT b-scans are shown in Figure 6. By careful comparison and analysis, we discovered that the transition zone of retinal function from abnormal inside to normal outside was roughly consistent with the scattered distribution of small drusenoid lesions in fundus photograph.

Patient 5 was the luckiest among the five patients with normal vision and no symptoms. Her fundus revealed no apparent abnormalities *via* a dilated fundus examination. Abnormality was found only at one horizontal level of SD-OCT with a slightly high reflex in the center of the macular fovea (Figure 3E), which may have no effect on vision quality, as she possessed normal vision and a normal visual field.

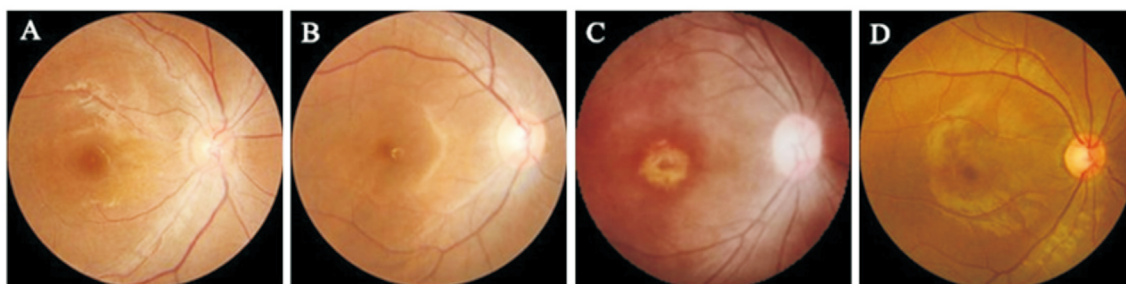


Figure 2 Color fundus photographs of the right eye in patient 1 (A), patient 2 (B), patient 3 (C), and patient 4 (D) A horizontally oval margin of atrophic lesions was evident in patient 3, and a few drusenoid deposits were dimly seen in the macula of patient 4.

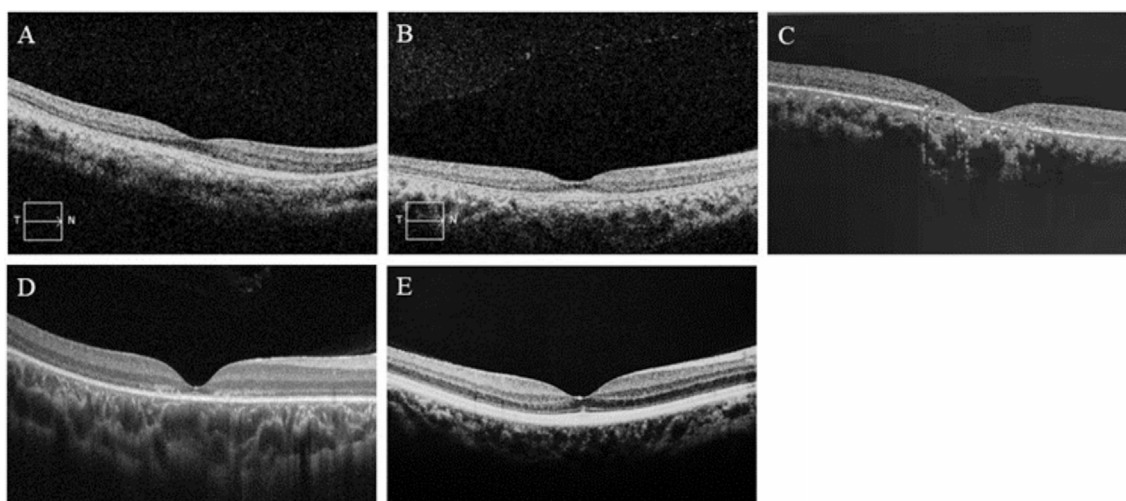


Figure 3 A horizontal SD-OCT b-scan was obtained in the right eye of each patient Patients 1, 2, and 3 (A, B, C) presented an irregular loss of ELM, ISe bands and IZ in the fovea. Patient 4 (D) presented an irregular loss of ISe and IZ, with a nearly intact ELM. Patient 5 (E) presented a lightly high reflex in the macular fovea. SD-OCT: Spectral domain optical coherence tomography; ELM: External limiting membrane; ISe: Inner segment ellipsoid; IZ: Interdigitation zone.

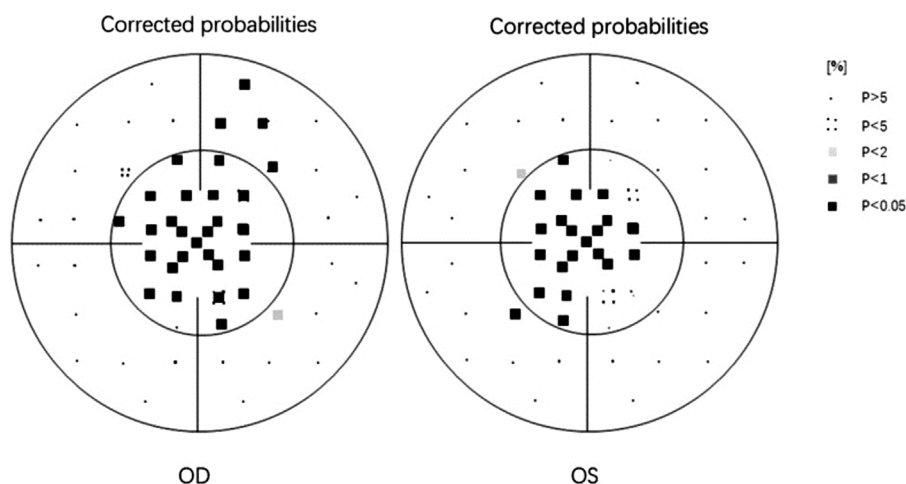


Figure 4 Visual field testing of patient 1 in the Octopus, presenting central scotomas and paracentral scotomas of both eyes OD: Right eye; OS: Left eye.

Genetic Analysis Genetic testing for the two families showed a heterozygous missense mutation (c.121C>T, p.R41W) in exon 3 of the CRX gene (Figure 7). For patient 1, the variant was subsequently verified in her affected mother (patient 3) and younger brother (patient 2). Patient 4 was verified in her affected mother (patient 5). Both families showed an obvious autosomal dominant inheritance pattern.

DISCUSSION

Distinct from RP clinically, the loss of central visual acuity and color vision in CORD patients occurs early following peripheral vision impairment gradually, meaning that their initial abnormalities arise from the macula rather than the midperipheral retina, and the loss of cone photoreceptor function precedes that of rod photoreceptors. Among the three

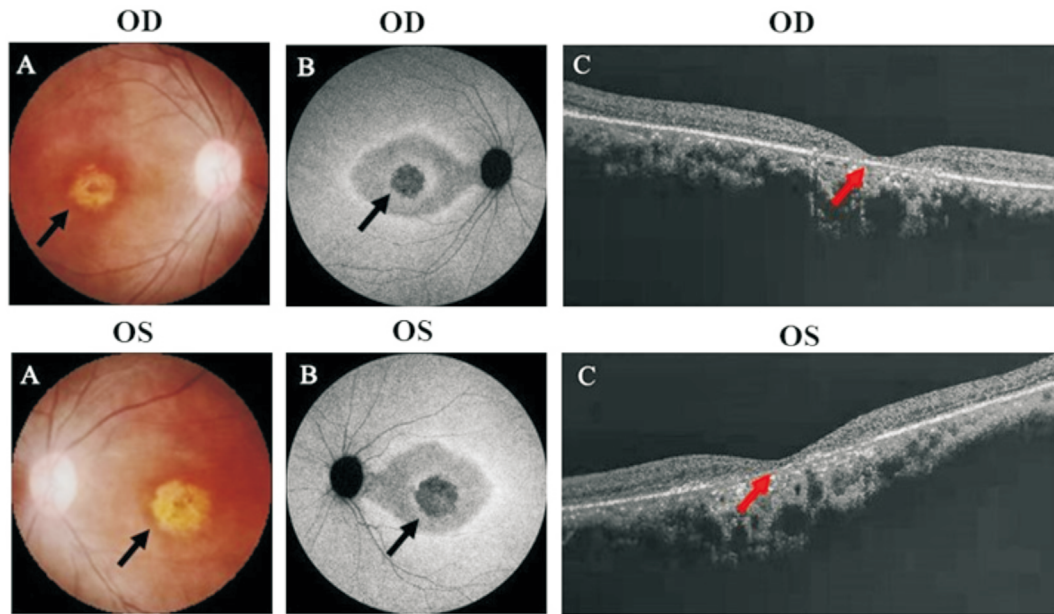


Figure 5 Color fundus photographs (A), FAF (B) and SD-OCT (C) of both eyes in patient 3 The FAF showed the evident extremely low fluorescence oval of foveal lesions with an abnormal hypo-AF line inside and a hyper-AF ring approaching the vascular arc outside. The SD-OCT presented almost total loss of the ELM, ISe and IZ from the inside out. The black arrows show the lesions of the macular area. The red arrows indicate the structure of fovea of the macula. FAF: Fundus autofluorescence; SD-OCT: Spectral domain optical coherence tomography; OD: Right eye; OS: Left eye; ELM: External limiting membrane; ISe: Inner segment ellipsoid; IZ: Interdigitation zone.

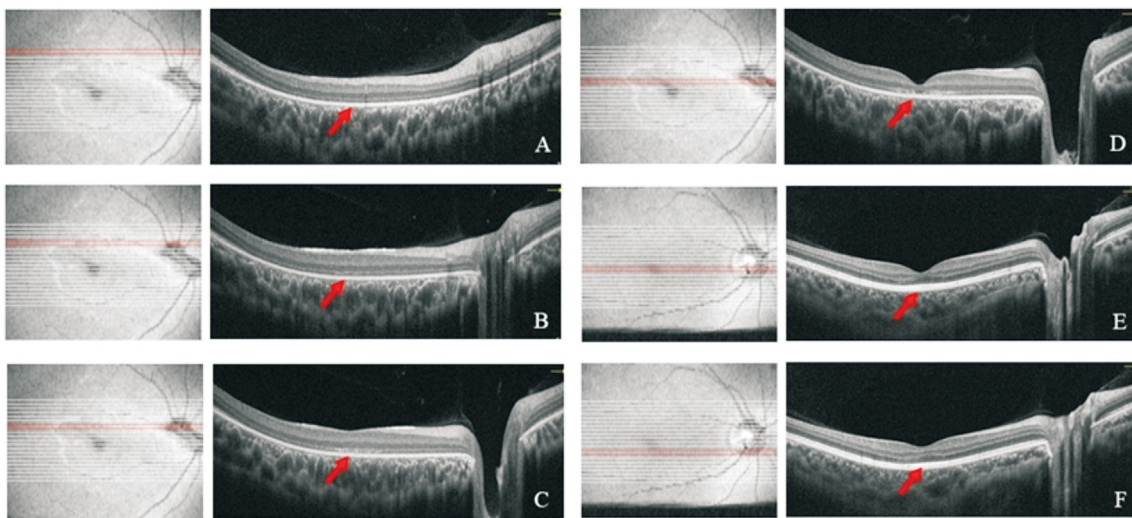


Figure 6 A different horizontal SD-OCT b-scan was shown in patient 4, presenting the transition zone between abnormal and normal retinal function, which was consistent with the foveal lesion in the fundus photograph The red arrows indicate the structure of the macula. SD-OCT: Spectral domain optical coherence tomography.

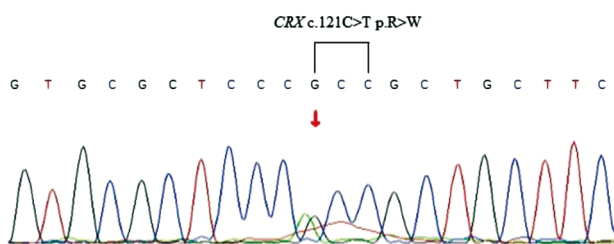


Figure 7 Sequence chromatograms showing the CRX c.121C>T mutation identified in this study The red arrow indicates the site of the mutation. CRX: Cone-rod homeobox.

inheritance patterns, autosomal dominance generally involves an earlier onset macular lesion and a more severe clinical course, usually leading to legal blindness before 50 years of age^[12]. However, in terms of some specific disease-causing genes, adCORD is not known to be consistent with systemic or partial manifestations^[13].

The CRX gene, located on 19q13.33, is a highly conserved homology to the OTX family and therefore defined as a cone-rod homeobox-containing gene (OMIM: 602225)^[5]. It often translates into a homeodomain transcription factor containing

299 amino acids encoded by four exons and has been proven to exert a significant role on the differentiation and maintenance of photoreceptor cells^[14]. To date, reported mutations of the CRX gene are composed of frameshift indel (57.6%), missense (22.4%), nonsense (17.6%) and splicing defects (2.4%), but each individual mutation rarely occurs^[15]. Through many analyses and summaries of the phenotypic and functional changes of each individual mutation, Tran *et al*^[16] discovered two dominant classes of human CRX mutations that cause retinal diseases: frameshift mutations and missense mutations, with the former mostly in the transactivation domains and the latter mostly in the binding homeodomain of DNA. The frameshift mutations mainly contain p.E168d1, p.E168d2, p.A196d4 and p.G217d1, which could produce truncated CRX proteins with the reduced transactivation ability of the target rhodopsin gene *in vitro*. However, the CRX target binding activity is retained normally since the activation domain CRX 1-107 is complete^[17]. It has been reported that these truncated CRX proteins can cause several stronger dominant retinal phenotypes clinically. For example, p.E168d1, p.E168d2, p.G217d1 are prone to cause adCORD or adLCA with early onset before 20y while p.A196d4 was related to adult onset adCORD^[16]. The p.R41W, p.R41Q, p.R90W and p.K88N are missense mutations, namely amino acid substitution mutations, which are predicted to play some similar roles in the function of the CRX protein. The first three converted the negatively-charged glutamates into either the positively-charged or neutral amino acids, which were predicted to possess hypomorphic activity representing either less severe dominant or recessive with late onset of adCORD (fourth-sixth decade)^[18], while p.K88N possessed the antimorphic activity and was expected to bring a stronger phenotype associated with adLCA^[19]. A small number of missense mutations, such as p.Q256X, can prematurely terminate protein translation and block the dimerization of the CRX molecule with the neural retina leucine zipper^[20]. Therefore the mainstream view at present is that both classes are pathogenic as they would produce mutant CRX protein. However, with further insight into CRX variants, some Chinese researchers found that some heterozygous truncated variants and approximately half of the heterozygous missense variants were likely benign through a series of analyses and comparisons in multiple aspects^[15]. There is no doubt that these uncertain findings still need additional studies, such as more cases and normal controls as well as functional studies. In our study, genetic testing showed an identical heterozygous missense CRX mutation (p.R41W) in five patients.

Among more than 90 CRX variants, the allele frequencies of p.R41W causing adCORD is pretty higher in the East Asian population^[14], especially in Japan, which has been reported

in several cases^[21-23]. By systematic literature search and retrospective analysis, we summarized the common clinical manifestations of adCORD with human CRX mutations (p.R41W) in Table 2. The reported Japanese patients had late onset (40-year-old) and decades of slow visual impairment progression compared to other genes of CORD^[14,21-22,24]. However, this is not quite the same as what we have got. However, that is not quite the same as what we have got. Patient 4 in our study developed symptoms at an early age (12-year-old), and her binocular vision had a sharp loss from 0.7 to 0.1 within 2y. The median age of onset in our cohort was in the second decade, varying from adolescence to the 4th decade, which is relatively earlier compared to Japanese patients. Moreover, hyperopia is frequently associated with CRX gene mutations, particularly among patients with LCA^[25]. However, we did not find hyperopia in our five patients, as shown in Table 1. In addition to vision and onset, other objective checks are equally important. The main abnormalities of clinical examinations in patients with adCORD (p.R41W) are listed in Table 2. To our knowledge, the diagnostic accuracy of inherited retinal dystrophies has been greatly improved by a wide variety of fundus imaging methods. Funduscopy, although one of the most commonly used ophthalmic examinations, may lead to misdiagnosis in some later diseases at first. For example, it seems to be a normal fundus or only a small loss of foveal reflex at the early stage of Stargardt disease or CORD. Diagnosis and treatment can therefore be delayed or mistaken until high sensitivity tests, such as FAF or OCT imaging, are promised^[26-27]. Through collecting related data, Kanda *et al*^[28] discovered a close connection between abnormalities in FAF and functional damage in CORD patients. Commonly, the small, circular areas of hypo-AF lesions in FAF were not notable on funduscopy, with the hypo-AF lesions likely representing the RPE dysfunction of increased metabolic load due to photoreceptor apoptosis^[26]. Reinforcing the discovery is the FAF of patient 3 (Figure 5). The hyper-AF arc reflects a transition zone of retinal function from the inside abnormal to outside normal; thus, function is relatively normal outside of the ring. The low autofluorescence inside the ring was relatively abnormal, and there was an extremely low fluorescence lesion in the center of the fovea, suggesting severely impaired macular function. With the progression of the disease, the hyper-AF macular ring was observed to increase in size according to some reports^[29]. Correspondingly, in the SD-OCT scan, the edge of the hyper-AF ring indicates the disorganization zone between the ELM and the ellipsoid portion^[29]. It is well known that common retinal features include three highly reflective parallel bands representing the ELM, ISe and IZ in the outer retina from the inside out, which are used as markers of photoreceptor integrity. Any disruption or deficit will cause central retinal

Table 2 Summary of the common clinical manifestations of autosomal dominant cone-rod dystrophy with human CRX mutations (p.R41W) in published literature

Literature (PMID)	Year of publication	Country	Family number	Total patient number	Affected (p.R41W) number	Onset	Macular degeneration	OCT	ERG	FAF
32112665 ^[24]	2020	Japan	14	21	12	Adult	+	The thinning and loss of ellipsoid zone	Electronegative	Macular lesion of hypo-autofluorescence
32533067 ^[14]	2020	Japan	13	18	3	NA-60y	+	Outer retinal disruption; the remained photoreceptor ellipsoid zone in one patient	Decreased dark-adapted responses and light-adapted responses; electronegative wave in one patient	Macular lesion of hypo-autofluorescence
31626798 ^[15]	2019	China	37	55	1	47y	+	NA	NA	NA
31203166 ^[34]	2019	France	0	1	1	NA	NA	NA	NA	NA
26957898 ^[21]	2016	Japan	11	43	1	43y	+	Outer retinal disruption	Subnormal cone wave and flicker wave, with normal rod wave	Macular lesion of hypo-autofluorescence
12819982 ^[22]	2003	Japan	NA	42	3	23-40y	+	NA	Electronegative	Macular lesion of hypo-autofluorescence
9427255 ^[35]	1997	USA	1	19	7	35-50y	+	NA	Electronegative	NA

CRX: Cone-rod homeobox; PMID: PubMed unique identifier; OCT: Optical coherence tomography; ERG: Electroretinogram; FAF: Fundus autofluorescence; NA: Not available.

functional disorders. Some researchers found an early loss of IZ in CORD patients, which represents an interaction band of apical processes between the RPE and the photoreceptor outer segment^[3]. However, it is not clear whether the early change in the IZ is specific to CORD, because it is sensitive to photoreceptor impairment and is vulnerable to disruption in most macular diseases on OCT^[30]. Another notable disruption and loss occurs on the ISe, corresponding to the gradually destroyed ellipsoid portion of the photoreceptor inner segment^[31-32], which is observed on SD-OCT of some patients^[33]. In advanced stages, such as patient 3 in our study, outer retinal structures, including the ELM, ISe and IZ have atrophied, even including the RPE and choroid. However, in the early stage, there are some different performances catching our attention. Patient 1 and patient 5 with the same age and visual acuity, however, express quite different manifestations in SD-OCT and visual field. The former presents an irregular loss of ELM, ISe bands and IZ in the fovea, as well as the central scotoma and paracentral scotoma in Octopus. The latter presents a nearly intact retina and visual field. Moreover, patient 1 had mild nyctalopia and color vision disturbance, while patient 5 had no eye complaints. Predicting SD-OCT and visual field testing may be useful tools to reveal the progression of the disease. Therefore, we speculate that the genotype-phenotype correlation may be associated with clinical symptoms.

Our study has a few limitations. The main limitation is the relatively small number of patients due to the low incidence of CORD. Another limitation is the absence of ERG in patients, although it is the gold standard for diagnosing CORD. It has been reported that most patients, especially Japanese patients, show a negative bright flash in ERG (Table 2)^[14-15,21-22,24,34-35], which is marked by a large downwards a-wave with a small upward b-wave under dark adaptation^[4]. However, due to the small number of cases, the phenotype of ERG has not yet been considered a consensus. Regardless of how, we need to persuade the patients to have a follow-up examination especially patients with good visual acuity, which will be shown in our future studies. Although a CORD patient with the CRX gene mutation (p.R41W) in China was reported in 2019, this is the first report in two Chinese families with an apparent autosomal dominant pattern. Our five patients exhibited some different clinical symptoms from other patients in East Asia, including earlier onset and more severe clinical features through fundus photography, FAF and SD-OCT, suggesting the genotype-phenotype polymorphism of the CRX gene.

ACKNOWLEDGEMENTS

The authors are grateful to all the patients and their family, as well as to the normal volunteers for their participation in this study. The authors would like to thank Dr. Bing Chen for ophthalmic examination.

Conflicts of Interest: Cui H, None; Jin X, None; Yang QH, None; Qu LH, None; Hou BK, None; Li ZH, None; Huang HB, None.

REFERENCES

- 1 Tsang SH, Sharma T. Progressive cone dystrophy and cone-rod dystrophy (XL, AD, and AR). *Advances in Experimental Medicine and Biology*. Cham: Springer International Publishing, 2018:53-60.
- 2 Garafalo AV, Sheplock R, Sumaroka A, Roman AJ, Cideciyan AV, Jacobson SG. Childhood-onset genetic cone-rod photoreceptor diseases and underlying pathobiology. *EBioMedicine* 2021;63:103200.
- 3 Gill JS, Georgiou M, Kalitzeos A, Moore AT, Michaelides M. Progressive cone and cone-rod dystrophies: clinical features, molecular genetics and prospects for therapy. *Br J Ophthalmol* 2019;103(5):711-720.
- 4 Evans K, Fryer A, Inglehearn C, Duvall-Young J, Whittaker JL, Gregory CY, Butler R, Ebenezer N, Hunt DM, Bhattacharya S. Genetic linkage of cone-rod retinal dystrophy to chromosome 19q and evidence for segregation distortion. *Nat Genet* 1994;6(2):210-213.
- 5 Freund CL, Gregory-Evans CY, Furukawa T, Papaioannou M, Looser J, Ploder L, Bellingham J, Ng D, Herbrick JAS, Duncan A, Scherer SW, Tsui LC, Loutradis-Anagnostou A, Jacobson SG, Cepko CL, Bhattacharya SS, McInnes RR. Cone-rod dystrophy due to mutations in a novel photoreceptor-specific homeobox gene (*CRX*) essential for maintenance of the photoreceptor. *Cell* 1997;91(4):543-553.
- 6 Rohde K, Hertz H, Rath MF. Homeobox genes in melatonin-producing pinealocytes: *Otx2* and *Crx* act to promote hormone synthesis in the mature rat pineal gland. *J Pineal Res* 2019;66(4):e12567.
- 7 Chapi M, Sabbaghi H, Suri F, Alehabib E, Rahimi-Aliabadi S, Jamali F, Jamshidi J, Emamalizadeh B, Darvish H, Mirrahimi M, Ahmadi H, Daftarian N. Incomplete penetrance of *CRX* gene for autosomal dominant form of cone-rod dystrophy. *Ophthalmic Genet* 2019;40(3):259-266.
- 8 Koyanagi Y, Akiyama M, Nishiguchi KM, *et al.* Genetic characteristics of retinitis pigmentosa in 1204 Japanese patients. *J Med Genet* 2019;56(10):662-670.
- 9 Jin X, Liu W, Qu LH, Huang HB. A novel variant in *PAX6* as the cause of aniridia in a Chinese family. *BMC Ophthalmol* 2021;21(1):225.
- 10 Jin X, Chen LL, Wang DJ, Zhang YX, Chen ZH, Huang HB. Novel compound heterozygous mutation in the *POC1B* gene underlie peripheral cone dystrophy in a Chinese family. *Ophthalmic Genet* 2018;39(3):300-306.
- 11 Jin X, Qu LH, Hou BK, Xu HW, Meng XH, Pang CP, Yin ZQ. Novel compound heterozygous mutation in the *CNGA1* gene underlie autosomal recessive retinitis pigmentosa in a Chinese family. *Biosci Rep* 2016;36(1):e00289.
- 12 Evans K, Duvall-Young J, Fitzke FW, Arden GB, Bhattacharya SS, Bird AC. Chromosome 19q cone-rod retinal dystrophy. ocular phenotype. *Arch Ophthalmol* 1995;113(2):195-201.
- 13 Birtel J, Eisenberger T, Gliem M, Müller PL, Herrmann P, Betz C, Zahnleiter D, Neuhaus C, Lenzner S, Holz FG, Mangold E, Bolz HJ, Charbel Issa P. Clinical and genetic characteristics of 251 consecutive patients with macular and cone/cone-rod dystrophy. *Sci Rep* 2018;8:4824.
- 14 Fujinami-Yokokawa Y, Fujinami K, Kuniyoshi K, *et al.* Clinical and genetic characteristics of 18 patients from 13 Japanese families with *CRX*-associated retinal disorder: identification of genotype-phenotype association. *Sci Rep* 2020;10:9531.
- 15 Yi Z, Xiao XS, Li SQ, Sun WM, Zhang QJ. Pathogenicity discrimination and genetic test reference for *CRX* variants based on genotype-phenotype analysis. *Exp Eye Res* 2019;189:107846.
- 16 Tran NM, Zhang AL, Zhang XD, Huecker JB, Hennig AK, Chen SM. Mechanistically distinct mouse models for *CRX*-associated retinopathy. *PLoS Genet* 2014;10(2):e1004111.
- 17 Chau KY, Chen S, Zack DJ, Ono SJ. Functional domains of the cone-rod homeobox (*CRX*) transcription factor. *J Biol Chem* 2000;275(47):37264-37270.
- 18 Huang L, Xiao X, Li S, Jia X, Wang P, Guo X, Zhang Q. *CRX* variants in cone-rod dystrophy and mutation overview. *Biochem Biophys Res Commun* 2012;426(4):498-503.
- 19 Nichols LL 2nd, Alur RP, Boobalan E, Sergeev YV, Caruso RC, Stone EM, Swaroop A, Johnson MA, Brooks BP. Two novel *CRX* mutant proteins causing autosomal dominant Leber congenital amaurosis interact differently with *NRL*. *Hum Mutat* 2010;31(6):E1472-E1483.
- 20 Lu QK, Zhao N, Lv YS, Gong WK, Wang HY, Tong QH, Lai XM, Liu RR, Fang MY, Zhang JG, Du ZF, Zhang XN. A novel *CRX* mutation by whole-exome sequencing in an autosomal dominant cone-rod dystrophy pedigree. *Int J Ophthalmol* 2015;8(6):1112-1117.
- 21 Oishi M, Oishi A, Gotoh N, Ogino K, Higasa K, Iida K, Makiyama Y, Morooka S, Matsuda F, Yoshimura N. Next-generation sequencing-based comprehensive molecular analysis of 43 Japanese patients with cone and cone-rod dystrophies. *Mol Vis* 2016;22:150-160.
- 22 Itabashi T, Wada Y, Sato H, Kunikata H, Kawamura M, Tamai M. Ocular findings in a Japanese family with an Arg41Trp mutation of the *CRX* gene. *Graefes Arch Clin Exp Ophthalmol* 2003;241(7):535-540.
- 23 Zhang QJ, Li SQ, Guo XM, Guo L, Xiao XS, Jia XY, Kuang ZH. Screening for *CRX* gene mutations in Chinese patients with Leber congenital amaurosis and mutational phenotype. *Ophthalmic Genet* 2001;22(2):89-96.
- 24 Nishiguchi KM, Kunikata H, Fujita K, Hashimoto K, Koyanagi Y, Akiyama M, Ikeda Y, Momozawa Y, Sonoda KH, Murakami A, Wada Y, Nakazawa T. Association of *CRX* genotypes and retinal phenotypes confounded by variable expressivity and electronegative electroretinogram. *Clin Exp Ophthalmol* 2020;48(5):644-657.
- 25 Hanein S, Perrault I, Gerber S, Tanguy G, Rozet JM, Kaplan J. Leber congenital amaurosis: survey of the genetic heterogeneity, refinement of the clinical definition and phenotype-genotype correlations as a strategy for molecular diagnosis. Clinical and molecular survey in LCA. *Adv Exp Med Biol* 2006;572:15-20.
- 26 Pichi F, Abboud EB, Ghazi NG, Khan AO. Fundus autofluorescence imaging in hereditary retinal diseases. *Acta Ophthalmol* 2018;96(5):e549-e561.

- 27 Guduru A, Lupidi M, Gupta A, Jalali S, Chhablani J. Comparative analysis of autofluorescence and OCT angiography in Stargardt disease. *Br J Ophthalmol* 2018;102(9):1204-1207.
- 28 Kanda S, Hara T, Fujino R, Azuma K, Soga H, Asaoka R, Obata R, Inoue T. Correlation between fundus autofluorescence and visual function in patients with cone-rod dystrophy. *Sci Rep* 2021;11(1):1911.
- 29 Lima LH, Zett C, Kniggendorf V, Marianelli B, de Carvalho RAP, Farah ME, Sallum JMF. Progressive expansion of the hyperautofluorescent ring in cone-rod dystrophy patients. *Ophthalmic Genet* 2018;39(4):492-499.
- 30 Fernandes TF, Sousa K, Azevedo I, Gouveia P, Calvão-Santos G, Gomes N, Falcão M. Baseline visual acuity and interdigitation zone as predictors in idiopathic epiretinal membranes: a retrospective cohort study. *Eur J Ophthalmol* 2021;31(3):1291-1298.
- 31 Inui E, Oishi A, Oishi M, Ogino K, Makiyama Y, Gotoh N, Kurimoto M, Yoshimura N. Tomographic comparison of cone-rod and rod-cone retinal dystrophies. *Graefes Arch Clin Exp Ophthalmol* 2014;252(7):1065-1069.
- 32 Lima LH, Sallum JMF, Spaide RF. Outer retina analysis by optical coherence tomography in cone-rod dystrophy patients. *Retina* 2013;33(9):1877-1880.
- 33 Yokochi M, Li DJ, Horiguchi M, Kishi S. Inverse pattern of photoreceptor abnormalities in retinitis pigmentosa and cone-rod dystrophy. *Documenta Ophthalmol* 2012;125(3):211-218.
- 34 Erkilic N, Sanjurjo-Soriano C, Diakatou M, Manes G, Dubois G, Hamel CP, Meunier I, Kalatzis V. Generation of a human iPSC line, INMi003-A, with a missense mutation in CRX associated with autosomal dominant cone-rod dystrophy. *Stem Cell Res* 2019;38:101478.
- 35 Swain PK, Chen SM, Wang QL, Affatigato LM, Coats CL, Brady KD, Fishman GA, Jacobson SG, Swaroop A, Stone E, Sieving PA, Zack DJ. Mutations in the cone-rod homeobox gene are associated with the cone-rod dystrophy photoreceptor degeneration. *Neuron* 1997;19(6):1329-1336.