

# Efficacy of scleral-fixated 3-looped haptics intraocular lens implantation for surgical management of microspherophakia

Xue-Wen Yu<sup>1,2</sup>, Xian Ge<sup>1,3</sup>, Wei-Jie Chen<sup>1</sup>, Shuang Ni<sup>1</sup>, Xue-Qi Lin<sup>1</sup>, Si-Ting Sheng<sup>1</sup>, Dan Chen<sup>1</sup>, Wen Xu<sup>1</sup>

<sup>1</sup>Eye Center of the Second Affiliated Hospital, Zhejiang University School of Medicine, Hangzhou 310000, Zhejiang Province, China

<sup>2</sup>Department of Ophthalmology, the First People's Hospital of Xiaoshan District, Xiaoshan Affiliated Hospital of Wenzhou Medical University, Hangzhou 311200, Zhejiang Province, China

<sup>3</sup>Jiayang Eye Hospital of Jianhu County, Yancheng 224700, Jiangsu Province, China

**Correspondence to:** Wen Xu. Eye Center of the Second Affiliated Hospital, Zhejiang University School of Medicine, Hangzhou 310000, Zhejiang Province, China. xuwen2003@zju.edu.cn

Received: 2022-01-17 Accepted: 2022-10-21

## Abstract

• **AIM:** To evaluate the safety and efficacy of scleral-fixated 3-looped haptics intraocular lens (IOL) implantation for surgical management of microspherophakia.

• **METHODS:** A retrospective case series include 10 microspherophakic patients (15 eyes) who underwent lens removal plus a modified surgical treatment of scleral-fixated 3-looped haptics IOL implantation. The primary outcomes involved visual acuity, intraocular pressure (IOP). Secondary outcomes were spherical equivalent (SE), anterior chamber depth (ACD), corneal endothelial cell density and postoperative complications.

• **RESULTS:** After a postoperative follow-up of 17.60±15.44mo, improved visual outcomes can be observed. The uncorrected distance visual acuity (UCVA) logMAR improved from 1.54±0.59 preoperatively to 0.51±0.35 postoperatively ( $P=0.001$ ), and best corrected visual acuity (BCVA) logMAR improved from 0.97±0.91 preoperatively to 0.24±0.23 postoperatively ( $P=0.003$ ). Moreover, the SE decreased from -9.58±7.47D preoperatively to -0.65±2.21 D postoperatively ( $P<0.001$ ). In terms of safety profile, the average IOP decreased from 21.10±12.94 mm Hg preoperatively to 14.03±3.57 mm Hg postoperatively ( $P=0.044$ ), and the previously elevated IOP of three eyes decreased to the

normal range. The ACD increased from 2.25±1.45 mm preoperatively to 3.35±0.39 mm postoperatively ( $P=0.017$ ). The density of corneal endothelial cells did not change significantly after surgery ( $P=0.140$ ). The posterior chamber IOLs were well centered and no severe complications were found.

• **CONCLUSION:** Lens removal plus the modified surgical treatment of scleral-fixated 3-looped haptics IOL implantation can help in improvement of visual acuity, which can be regarded as a relative safe method for the surgical management of microspherophakia.

• **KEYWORDS:** microspherophakia; transscleral suture fixation; 3-looped haptics intraocular lens

**DOI:10.18240/ijo.2022.12.08**

**Citation:** Yu XW, Ge X, Chen WJ, Ni S, Lin XQ, Sheng ST, Chen D, Xu W. Efficacy of scleral-fixated 3-looped haptics intraocular lens implantation for surgical management of microspherophakia. *Int J Ophthalmol* 2022;15(12):1944-1950

## INTRODUCTION

Microspherophakia is a rare lenticular abnormality due to congenital dysplasia, commonly seen in Weill-Marchesani syndrome<sup>[1-2]</sup>. The crystalline lens of microspherophakia shows a spherical shape with an increased anteroposterior distance and a reduced equatorial diameter (ED)<sup>[1,3-7]</sup>. After pupil dilation, the entire lens equator and abnormally loose zonules are visible. The common complications include lens dislocation, glaucoma and high myopia<sup>[6,8-11]</sup>. Special lens morphology and complicated complications make the treatment of these microspherophakic patients difficult.

Microspherophakia requires surgical treatment if it is accompanied with cataract, and/or lens dislocation, and/or secondary glaucoma<sup>[11]</sup>. After lens removal, intraocular lens (IOL) implantations are required to rehabilitate the vision. The surgical methods of microspherophakia are varied in different cases, including scleral-fixated IOL (SF-IOL) implantation<sup>[4,12-14]</sup>,

posterior chamber IOL (PC-IOL) implantation with capsular tension ring (CTR)<sup>[4,15-16]</sup>, and anterior chamber IOL (AC-IOL) implantation<sup>[8,17]</sup>. However, there is no consensus for the management of microspherophakia. Patients with microspherophakia are at high risk of corneal endothelial cell loss<sup>[8,11]</sup>, while AC-IOL implantation may further damage the corneal endothelial cells<sup>[18]</sup>. Due to the reduced ED of the lens in microspherophakia, it is difficult to implant normal-sized CTR and PC-IOL. With gradual progress of the loose zonules, PC-IOL with CTR may not be centered and even fall into the vitreous cavity<sup>[4,15]</sup>. Recently, SF-IOL has become a surgical option that is increasingly adopted by surgeons in microspherophakia<sup>[4,12-14]</sup>.

Several studies related to surgical treatment of microspherophakia are available in the existing literature<sup>[4,8,12-17]</sup>, while most of them are case reports with short follow-up periods. In the present study, we innovatively adopted lens removal plus a modified surgical treatment of scleral-fixated 3-looped haptics IOL implantation with three reverse scleral pockets and intact conjunctiva.

## SUBJECTS AND METHODS

**Ethical Approval** The study was performed in accordance with the tenets of the Declaration of Helsinki. The study was approved by the Ethics Committee of the Second Affiliated Hospital, Zhejiang University School of Medicine (No.yan2020-465). Written informed consent was obtained from each patient and/or from his or her parents or guardians.

**Subjects and Examination** In the retrospective study, 10 patients (15 eyes) diagnosed with microspherophakia in the Eye Center of the Second Affiliated Hospital, Zhejiang University School of Medicine were recruited from July 2016 to December 2021. The follow-up was 17.60±15.44mo.

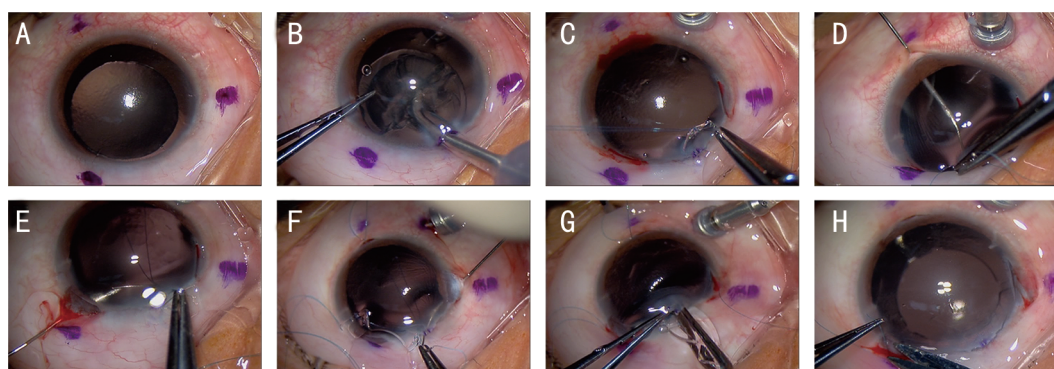
Inclusion criteria were set as follows: 1) Diagnosed as microspherophakia with lens diameter <9 mm; 2) Lens subluxation >90° and with uncorrectable vision; 3) increased intraocular pressure (IOP) or continuous loss of corneal endothelium (defined as an apparent decrease in the density of corneal endothelial cells during close follow-up) due to spherical lens; 4) Cataract; 5) Improved postoperative visual acuity measured by retinometer.

Exclusion criteria were set as follows: 1) Centered lens and stable lens position; 2) High possibility of postoperative corneal decompensation; 3) Poor fundus function; 4) Patients with other eye diseases that are not suitable for IOL implantation; 5) Patients with systemic diseases who cannot tolerate surgery.

The demographic information including age, gender, chief complaint and related general conditions were collected. All patients were required to undergo detailed eye examinations before and after surgery, including uncorrected distance visual

acuity (UCVA), best corrected visual acuity (BCVA), slit lamp examination (SL-D701, TOPCON, Tokyo, Japan) after the pupil was fully dilated, and a dilated fundus examination (TRC-NW8, TOPCON, Tokyo, Japan). Axial length (AL) was determined by ultrasonographic A-scan biometry (SW-2000, SUOER, Tianjin, China). Keratometry was measured by corneal topographic map (Pentacam HR; OCULUS Optikgerate, Wetzlar, Germany). The ED of the lens was determined by comparing the ED with the corneal diameter in the photographs from slit lamp examinations. Corneal diameter was obtained from corneal topographic map. Anterior lens radius was calculated using the formula in the previous study<sup>[3]</sup>. IOP was measured by a non-contact tonometer (NT-510, NIDEK, Aichi-ken, Japan). Anterior chamber depth (ACD) from the central corneal endothelium to the anterior surface of the lens was measured by ultrasound biomicroscope (UBM; SW-3200, SUOER, Tianjin, China). Endothelial cell density was measured by specular microscopy (EM-3000, TOMEY, Aichi-ken, Japan). PC-IOL tilt degree and PC-IOL decentration distance (defined as the larger value between vertical and horizontal directions) were observed by UBM according to a previously described approach<sup>[19]</sup>. Moreover, postoperative complications were also collected.

**Surgical Procedure** All operations were performed according to the following procedure by Dr. Xu W (Figure 1)<sup>[20]</sup>. After a retrobulbar anesthetic block, a 20-G infusion cannula was put into the anterior chamber to maintain the IOP at the limbus at about 6 o'clock. A marker pen was used to make three symmetrical marks at the conjunctiva at 4, 8 and 12 o'clock. A 3.5-mm corneal incision and an auxiliary 0.8-mm corneal incision were made at 10 o'clock and 2 o'clock, respectively. After lens removal by phacoemulsification or lensectomy, a thorough anterior vitrectomy was performed with the placement of the infusion cannula. Three 3-mm wide incisions were made at the limbus without opening the conjunctival sac at each marked meridian position. Then the scleral pockets were made by using a crescent blade to dissect the scleral lamellar 2 mm to the marked position in the direction of the conjunctival fornix. A 9-0 polypropylene suture (MANI Inc.) was attached to each haptic of a 3-looped haptics IOL (CT ASPHINA 603P, Zeiss, Germany). A 27-G hollow needle passed through the scleral pocket bed and entered the posterior chamber. The suture needle entered the center of the pupil through the 3.5 mm corneal incision, and then passed through the scleral pocket bed with the guidance of the hollow needle. After guiding and inserting three suture needles of three haptics, the PC-IOL was entered through the 3.5 mm incision at 10 o'clock and was placed in the ciliary sulcus. After adjusting the optics of the PC-IOL to the center of the pupil, the three pairs of sutures were tied and knotted at three scleral



**Figure 1** Intraoperative photos of lens removal plus scleral-fixated 3-looped haptics IOL implantation A: A three symmetrical marks were made at the conjunctiva; B: Lens removal by phacoemulsification and lens capsule removal by anterior vitrectomy; C: Three scleral pockets were made at limbus based on the marks and a 9-0 polypropylene suture was attached to each haptic of a 3-looped haptics IOL; D-F: A hollow needle passed through the three scleral pocket bed and guide out the suture needle through the scleral pocket bed in turn; G: The PC-IOL was folded and entered through the 3.5 mm incision; H: The three pairs of sutures were tied and knotted at three scleral pockets. All the scleral pockets and corneal incision were closed. IOL: Intraocular lens; PC-IOL: Posterior chamber intraocular lens.

pockets, respectively. At the end of the surgery, the infusion cannula was removed. A 10-0 nylon suture was used to close the scleral pockets and corneal incision.

Postoperatively, 0.5% levofloxacin (Santen Pharmaceutical, Osaka, Japan) eye drops were given four times daily for a week, 1% prednisolone acetate ophthalmic suspension (Allergan Inc., Irvine, California, USA) and 0.1% diclofenac sodium (Xingqi Pharmaceutical Co., Ltd. Shenyang, China) eye drops were given four times daily for 4wk.

**Statistical Analysis** The Statistical Program for Scientific Studies (SPSS) V.26.0 for Mac (IBM Corporation, Armonk, NY, USA) was used for statistical analysis. The distribution of continuous variables was determined by the Shapiro-Wilk test. Normally distributed data were compared using paired *t*-test, and nonnormally distributed data were analyzed using the Wilcoxon test. The results are expressed as the mean±standard deviation. A *P* value <0.05 was considered statistically significant.

## RESULTS

**Demographic Parameters and Morphological Characteristics of Microspherophakia** Table 1 list the demographic characteristics of microspherophakia before surgery. Ten patients were included in the study, of which only 3 were men. The mean subject age was 39.20±15.05y and the mean follow-up time was 17.60±15.44mo. Morphological characteristics of microspherophakia was shown in Table 1. The patients showed high lenticular myopia, about -9.58±7.47 D. The AL and keratometry are within the normal range, which are 23.89±2.21 mm and 41.65±3.29 D, respectively. Anterior segment examination results showed that ACD was 2.25±1.45 mm, ED was 7.90±0.38 mm, and anterior lens radius was 4.83±1.42 mm. The preoperative data of ACD, ED and anterior lens radius was lost in 2 patients because

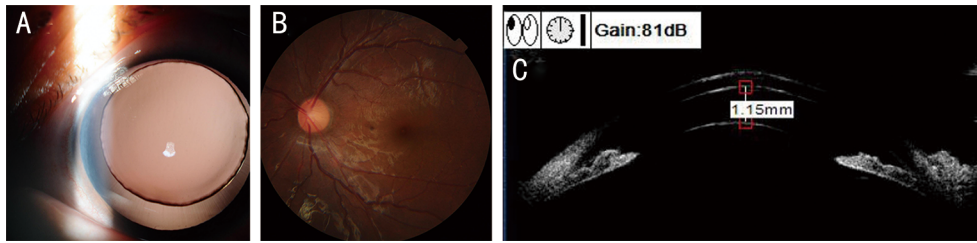
**Table 1** Demographic and morphological characteristics of microspherophakic patients before surgery

Demographic characteristics	Data
Patient	10
Age (y)	39.20±15.05
Sex (male/female)	3/7
Eyes (operated with the novel surgical technique)	15
OD/OS	8/7
Follow-up time (mo)	17.60±15.44
Morphological characteristics	
SE (D), <i>n</i> =15	-9.58±7.47
AL (mm), <i>n</i> =15	23.89±2.21
Keratometry (D), <i>n</i> =15	41.65±3.29
ACD (mm), <i>n</i> =13	2.25±1.45
ED (mm), <i>n</i> =13	7.90±0.38
Anterior lens radius (mm), <i>n</i> =13	4.83±1.42

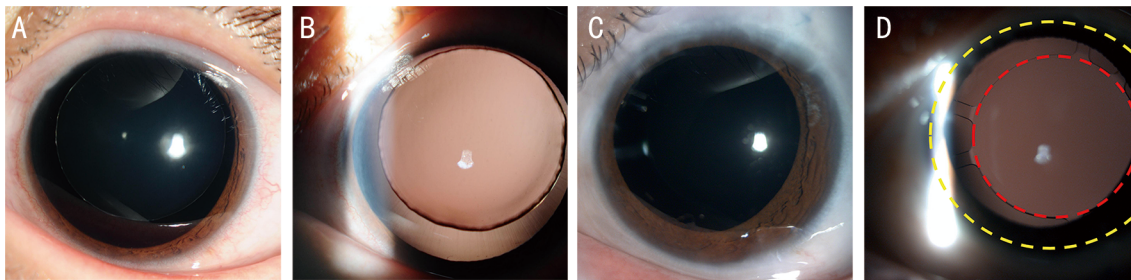
SE: Spherical equivalent; AL: Axial length; ACD: Anterior chamber depth; ED: Equatorial diameter.

microspherophakic lenses were removed in emergency, and secondary IOL implantations were arranged. The images of the slit lamp (Figure 2A), a dilated fundus examination (Figure 2B), and UBM image (Figure 2C) before surgery were presented. Based on the morphology and a forementioned measurement results, microspherophakia was diagnosed.

**Visual and Refractive Outcomes** Lens was removed, and IOL was successfully implanted with this innovative surgical technique in every patient (a total of 15 eyes). Visual and refractive outcomes improved after surgery (Table 2). The UCVA logMAR and BCVA logMAR improved compared with the preoperative ones (1.54±0.59 preoperatively vs 0.51±0.35 postoperatively, *P*=0.001; 0.97±0.91 preoperatively vs 0.24±0.23 postoperatively, *P*=0.003, respectively). SE decreased from -9.58±7.47 D preoperatively to -0.65±2.21 D postoperatively (*P*<0.001).



**Figure 2 Images of the slit lamp, a dilated fundus examination, and UBM before surgery** A: A photograph of the slit lamp was taken after pupil dilation, showing the entire lens exposed to the field of view, and a relaxed and elongated lens zonule at the equatorial edge of the lens; B: The photograph of the fundus was taken after pupil dilation, and the fundus was shown as a normal fundus; C: UBM image of microspherophakia showed a shallow anterior chamber, narrow anterior chamber angles and a very steep anterior lens curvature. UBM: Ultrasound biomicroscope.



**Figure 3 The anterior segment images before and after surgery** A, B: The anterior segment images before surgery. The lens was small, and the entire lenticular equator was visible when the pupil was fully dilated. Weak and stretched zonules could be seen around the lens. The edge of the lens was not smooth. The spherical lens was dislocated to the nasal-superior position. C, D: The anterior segment images after surgery. C: The conjunctiva was intact without a scar. D: The IOL was well centered. IOL: Intraocular lens.

**Table 2 Comparison of UCVA, BCVA, SE, ACD, IOP, and corneal endothelium before and after surgery**

Items	Pre-operation	Post-operation	P
UCVA logMAR, n=15	1.54±0.59	0.51±0.35	0.001 <sup>a</sup>
BCVA logMAR, n=15	0.97±0.91	0.24±0.23	0.003 <sup>a</sup>
SE (D), n=15	-9.58±7.47	-0.65±2.21	<0.001 <sup>a</sup>
ACD (mm), n=13	2.25±1.45	3.35±0.39	0.017 <sup>a</sup>
Average IOP (mm Hg), n=15	21.10±12.94	14.03±3.57	0.044 <sup>a</sup>
Previously normal IOP (mm Hg), n=12	15.39±3.15	13.96±3.63	0.231
Previously elevated IOP (mm Hg), n=3	32.3/43.5/56	12/19/12	-
Corneal endothelial cell (/mm <sup>2</sup> ), n=15	2051±721	1646±524	0.140

UCVA: Uncorrected distance visual acuity; BCVA: Best corrected visual acuity; logMAR: Logarithm of the minimal angle of resolution; SE: Spherical equivalent; ACD: Anterior chamber depth; IOP: Intraocular pressure. <sup>a</sup>Statistically significant.

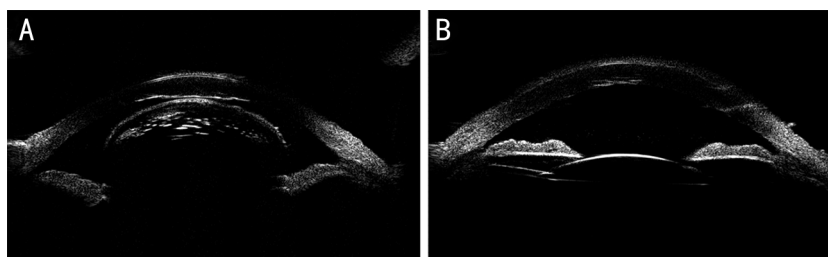
**Safety Outcomes** After surgery, ACD increased from 2.25±1.45 mm preoperatively to 3.35±0.39 mm postoperatively ( $P=0.017$ ). Average IOP significantly decreased from 21.10±12.94 mm Hg preoperatively to 14.03±3.57 mm Hg postoperatively ( $P=0.044$ ), and the previously elevated IOP of three eyes decreased to the normal range (Table 2). Previously normal IOP remained within the normal range after surgery ( $P=0.231$ ). The difference in corneal endothelial cell density were not statistically significant before and after surgery ( $P=0.140$ ). Compared with the preoperative one, the postoperative condition of the anterior eye segment improved (Figure 3). The IOLs were well centered. The representative images from UBM before and after surgery were presented (Figure 4A, 4B). The IOLs remained stable in the ciliary

sulcus. PC-IOL tilt degree was 3.01°±2.12°, and PC-IOL decentration distance was 0.40±0.27 mm.

No severe complications were record after surgery. One eye of a patient had a low IOP of 3 mm Hg on the first postoperative day, and then the IOP returned to normal range with systemic and topical use of glucocorticoids for a week. A patient with preoperative secondary glaucoma had postoperative IOP fluctuations. IOP of one eye decreased from 32.3 mm Hg preoperatively to 11.5 mm Hg 1d postoperatively, while it returned to 37 mm Hg 1wk postoperatively. IOP returned to normal with antiglaucoma medications 2mo after surgery.

#### DISCUSSION

As a rare lenticular disease, we found that the microspherophakic eyes had a reduced ED of 7.90±0.38 mm, which was similar



**Figure 4** The representative images from UBM before and after surgery A: Image from UBM before surgery. The spherical lens was dislocated into anterior chamber, which contacted the corneal endothelium. The anterior chamber disappeared. The anterior lens radius was small. B: Image from UBM after surgery. The IOL was stably placed in the ciliary sulcus. IOL: Intraocular lens; UBM: Ultrasound biomicroscope.

to those in previous studies<sup>[3-4,8-9,17,21-24]</sup>. The anterior lens radius was  $4.83 \pm 1.42$  mm, which presented a steeper curvature of the anterior lens surfaces compared with that in an existing case report at about 6 mm<sup>[3]</sup>. After the pupil was fully dilated, the entire lenticular equator became visible with a relaxed and elongated lens zonule, and the lens was much smaller than a normal one in the pupil plane (Figure 2A), which posed difficulty in conventional PC-IOL implantation.

Subluxation and secondary glaucoma are the common complications in microspherophakic patients. Microspherophakic patients should be treated with surgery if they have a large range of subluxation and/or secondary glaucoma which can not be controlled by drugs and laser peripheral iridotomy. The main surgical approach of microspherophakia is to remove abnormal spherical lens and implant IOL to improve postoperative vision<sup>[18,23]</sup>.

PC-IOL implantation with CTR was successfully performed by Yang *et al*<sup>[4]</sup>. The study<sup>[4]</sup> has shown that only 71.4% of patients with spherophakia were well centered at 3y post-operation of successful CTR implantation. With the gradual progress of the loose zonules, the bag-CTR-IOL complex may fall into the vitreous cavity<sup>[15]</sup>. Therefore, the bag-CTR-IOL complex should be fixed on the sclera with a capsular tension segment (CTS). Some studies successfully implanted PC-IOL with CTR and CTS in microspherophakic patients<sup>[15-16]</sup>. However, we found that EDs of lenses ( $7.90 \pm 0.38$  mm) in our microspherophakic patients were much smaller than normal lens (about 9 mm). The capsular bag could not be stretched by CTR to accommodate a PC-IOL with the normal whole length (range 12-13 mm). Initially, we implanted a CTR in a microspherophakic patient after lens removal. The two ends of the CTR were much overlapped in the pupil area, and the PC-IOL was difficult to implant. Therefore, the CTR and capsular bag were removed, and SF-IOL implantation was adopted. Because this case was operated before the conduction of the study, we did not include this case in the study.

AC-IOL implantation may be subjected to risks of corneal endothelial cell loss<sup>[18]</sup>. In a 12-year follow-up study of AC-IOL implanted eyes, it was found that the loss rate of corneal

endothelium was 29.1%<sup>[25]</sup>. However, microspherophakic patients are at high risks of corneal endothelial cell loss because the lens may move forward and injure the corneal endothelium<sup>[8,11]</sup>. Guo *et al*<sup>[11]</sup> found significantly reduced corneal endothelial cells of left eye in a microspherophakic patient, and the cell count was only 576 cells/mm<sup>2</sup>. In our study, Table 2 reveals that the corneal endothelial cell density of microspherophakic patients was  $2051 \pm 721$  cells/mm<sup>2</sup> before surgery, indicating that the corneal endothelium was damaged. Therefore, AC-IOL implantation in microspherophakia is required to consider corneal endothelial cell density before surgery.

SF-IOL implantation is a suitable choice for microspherophakic patients causing less damage to the corneal endothelium. A 2-year follow-up study showed only 3.5% loss of corneal endothelium after SF-IOL implantation comparing with 15.5% loss of corneal endothelium after AC-IOL implantation<sup>[26]</sup>. However, traditional SF-IOL implantation is performed by 2-point fixation technique at two symmetrical positions in the sclera<sup>[4,13]</sup>. Because two points make a straight line, 2-point fixation of IOL will inevitably cause postoperative IOL instability<sup>[27-29]</sup>. Cho and Yu<sup>[30]</sup> reported the incidence of complication is 9% in dislocation, 11% in tilting, and 23% in pupillary capture of IOL, respectively in combined vitrectomy patients. Our technique used three sutures to fix the IOL, leading to the relative stable plane of a triangle since three points made a plane. In our study, PC-IOL tilt degree was  $3.01^\circ \pm 2.12^\circ$ , and PC-IOL decentration distance was  $0.40 \pm 0.27$  mm. No IOL dislocation or severe IOL tilting were found in the study. In addition, 3-looped haptics IOL has three haptics, which are square in shape and wide in base, the possibility of incarceration of the IOL haptics in pupils is significantly reduced. The complication of pupillary capture of IOL was not found in our study.

The anatomical integrity of the conjunctiva is important for microspherophakic patients. Secondary glaucoma is one of the most common complications in microspherophakic patients. Rao *et al*<sup>[31]</sup> have found that 7.7% eyes still required glaucoma surgery because of uncontrolled IOP even after lensectomy.

The integrity of the conjunctival anatomy is important for these patients who need glaucoma surgery. Our technique made the reverse scleral pockets from the limbus, avoiding the conjunctival injury and further preventing the conjunctival scar formation. The conjunctiva of the patient which was still intact without scar was clearly shown in Figure 3C. The feasibility of anti-glaucoma surgery in those patients who needed glaucoma surgery in the future was reserved.

We used the modified technique of scleral-fixated PC-IOL to achieve the outcomes in microspherophakic patients. In a prospective interventional case series<sup>[4]</sup>, microspherophakic patients underwent PC-IOL implantation with CTR and SF-IOL implantation by 2-point fixation technique respectively. Two groups achieved the postoperative BCVA logMAR of  $0.44\pm 0.38$  and  $0.43\pm 0.38$  respectively, which were similar to our results that postoperative BCVA logMAR was  $0.24\pm 0.23$ . In this previous study<sup>[4]</sup>, SE decreased from  $-11.85\pm 3.71$  D preoperatively to  $-1.25\pm 0.78$  D postoperatively in PC-IOL+CTR group, and fell from  $-12.05\pm 3.42$  D preoperatively to  $-0.97\pm 0.57$  D postoperatively in SF-IOL group. This was similar to our results dropping from  $-9.58\pm 7.47$  D preoperatively to  $-0.65\pm 2.21$  D postoperatively. The surgical efficacy in visual outcomes seen in our study seemed comparable to previous studies using the two aforementioned IOL implantation methods. In our surgical method, IOP was well controlled, IOL was well centered and no severe complications were observed. Therefore, our surgical method obtained satisfied results in safety profile.

The limitation of our study is the retrospective design, which inherently is affected by missing data. However, the retrospective study is necessary for a rare disease to observe the long-term surgical effect. Another limitation is the sample size. A study with larger sample sizes is required in the future. In conclusion, the management of microspherophakia is challenging. There are some shortages in traditional surgical management for microspherophakia. Lens removal plus the modified treatment of scleral-fixated 3-looped haptics IOL implantation can also be a choice for the surgical management of microspherophakia, which ensures both visual acuity improvement and surgical safety.

#### ACKNOWLEDGEMENTS

**Authors' contributions:** All authors conceived and designed the study. Yu XW, Ge X, Chen WJ, Ni S, Lin XQ collected data and analyzed the statistics. Sheng ST and Chen D reviewed the literature. Yu XW and Xu W drafted the article or revised it critically for important intellectual content. All authors approved the final version to be published.

**Conflicts of Interest:** Yu XW, None; Ge X, None; Chen WJ, None; Ni S, None; Lin XQ, None; Sheng ST, None; Chen D, None; Xu W, None.

#### REFERENCES

- 1 Gilbert AL, Thanos A, Pineda R. Persistent blurry vision after a routine eye examination. *JAMA Ophthalmol* 2016;134(9):1065-1066.
- 2 Zhang Z, Zhang SH. Effect of aberrometry in diagnosis of isolated spherophakia. *Int J Ophthalmol* 2022;15(2):367-370.
- 3 Chan RTY, Collin HB. Microspherophakia. *Clin Exp Optom* 2002; 85(5):294-299.
- 4 Yang J, Fan Q, Chen JY, Wang AJ, Cai L, Sheng H, Lu WY, Jiang YX, Lu Y. The efficacy of lens removal plus IOL implantation for the treatment of spherophakia with secondary glaucoma. *Br J Ophthalmol* 2016;100(8):1087-1092.
- 5 Ndoye Roth PA, Toure SA, Kane H, Sow AS, Wane AM, Ndiaye JM, Ka AM, Diagne JP, Diallo HM, Demedeiros Quenum ME, Nguer M, Ba EA, Ndiaye PA, Ndiaye MR. Isolated microspherophakia in a Senegalese family. *J Fr Ophtalmol* 2017;40(2):110-114.
- 6 Muralidhar R, Ankush K, Vijayalakshmi P, George VP. Visual outcome and incidence of glaucoma in patients with microspherophakia. *Eye (Lond)* 2015;29(3):350-355.
- 7 Sivakumar P, Vedachalam R, Shivananda N. Diagnosis of a globular lens-a ring in the eye. *JAMA Ophthalmol* 2019;137(4):e184413.
- 8 Willoughby CE, Wishart PK. Lensectomy in the management of glaucoma in spherophakia. *J Cataract Refract Surg* 2002;28(6):1061-1064.
- 9 Liu Q, Wang XG, Zhang SH. Visual quality observation of clear lens extraction by ultrasonic phacoemulsification and intraocular lens implantation in a child with microspherophakia: a case report. *Medicine* 2020;99(34):e21937.
- 10 Yu XW, Chen WJ, Xu W. Diagnosis and treatment of microspherophakia. *J Cataract Refract Surg* 2020;46(12):1674-1679.
- 11 Guo H, Wu XY, Cai KL, Qiao Z. Weill-Marchesani syndrome with advanced glaucoma and corneal endothelial dysfunction: a case report and literature review. *BMC Ophthalmol* 2015;15:3.
- 12 Shreya TS, Senthilkumar VA, Mishra C, Krishnadas R. A rare presentation of bilateral dislocated lens in a patient with isolated microspherophakia. *Indian J Ophthalmol* 2020;68(6):1161-1163.
- 13 Subbiah S, Thomas PA, Jesudasan CAN. Scleral-fixated intraocular lens implantation in microspherophakia. *Indian J Ophthalmol* 2014; 62(5):596-600.
- 14 Karadag R, Celik HU, Bayramlar H, Rapuano CJ. Sutureless intrascleral fixated intraocular lens implantation. *J Refract Surg* 2016; 32(9):586-597.
- 15 Khokhar S, Gupta S, Kumar G, Rowe N. Capsular tension segment in a case of microspherophakia. *Contact Lens Anterior Eye* 2012; 35(5):230-232.
- 16 Canabrava S, Canedo Domingos Lima AC, Arancibia AEL, Bicalho Dornelas LF, Ribeiro G. Novel double-flanged technique for managing Marfan syndrome and microspherophakia. *J Cataract Refract Surg* 2020;46(3):333-339.
- 17 Moshirfar M, Meyer JJ, Schliesser JA, Espandar L, Chang JC. Iris-fixated phakic intraocular lens implantation for correction of high myopia in microspherophakia. *J Cataract Refract Surg* 2010;36(4): 682-685.

- 18 Khokhar S, Pillay G, Sen S, Agarwal E. Clinical spectrum and surgical outcomes in spherophakia: a prospective interventional study. *Eye (Lond)* 2018;32(3):527-536.
- 19 Choi SR, Jeon JH, Kang JW, Heo JW. Risk factors for and management of pupillary intraocular lens capture after intraocular lens transscleral fixation. *J Cataract Refract Surg* 2017;43(12):1557-1562.
- 20 Ni S, Wang W, Chen X, Wu XD, He SH, Ma YJ, Xu W. Clinical observation of a novel technique: transscleral suture fixation of a foldable 3-looped haptics one-piece posterior chamber intraocular lens implantation through scleral pockets with intact conjunctiva. *BMC Ophthalmol* 2019;19(1):105.
- 21 Gupta G, Gupta PC, Thakur A, Murugan B, Ram J. Isolated microspherophakia with retinitis pigmentosa. *Indian J Ophthalmol* 2019;67(7):1160.
- 22 Shakrawal J, Selvan H, Sharma A, Angmo DW. Double trouble: microspherophakia with axenfeld-rieger anomaly. *Indian J Ophthalmol* 2019;67(3):394-395.
- 23 Khokhar S, Pangtey MS, Sony P, Panda A. Phacoemulsification in a case of microspherophakia. *J Cataract Refract Surg* 2003;29(4):845-847.
- 24 Lim SH, Son JH, Cha SC. Acute angle-closure glaucoma in a highly myopic patient secondary to Weill-Marchesani syndrome: histopathologic lens features. *Int Ophthalmol* 2016;36(6):921-924.
- 25 Tang YT, Xu J, Chen JH, Lu Y. Long-term destiny of corneal endothelial cells in anterior chamber intraocular lens-implanted eyes. *J Ophthalmol* 2020;2020:5967509.
- 26 Ranno S, Rabbio GM, Lucentini S, Ruggiero E, Luccarelli SV, Lombardi L, Nucci P. Angle-supported intraocular lens versus scleral-sutured posterior chamber intraocular lens in post-cataract surgery aphakic patients: two-year follow-up cost-effectiveness analysis. *Int Ophthalmol* 2022;42(3):871-879.
- 27 Por YM, Lavin MJ. Techniques of intraocular lens suspension in the absence of capsular/zonular support. *Surv Ophthalmol* 2005;50(5):429-462.
- 28 Atik BK, Altan C, Agca A, Kirmaci A, Yildirim Y, Genc S, Taskapili M. The effect of intraocular lens tilt on visual outcomes in scleral-fixated intraocular lens implantation. *Int Ophthalmol* 2020;40(3):717-724.
- 29 Kim Y, Choi EY, Lee CS, Kim SS, Byeon SH. Clinical Characteristics of recurrent intraocular lens dislocation after scleral-fixated sutured intraocular lens and long-term outcomes of intraocular lens re-fixation. *Graefes Arch Clin Exp Ophthalmol* 2022;260(10):3267-3273.
- 30 Cho BJ, Yu HG. Surgical outcomes according to vitreous management after scleral fixation of posterior chamber intraocular lenses. *Retina* 2014;34(10):1977-1984.
- 31 Rao DP, John PJ, Ali MH, Kekunnaya R, Jalali S, Garudadri CS, Senthil S. Outcomes of lensectomy and risk factors for failure in spherophakic eyes with secondary glaucoma. *Br J Ophthalmol* 2018;102(6):790-795.