

Supporting suture combined scleral fixation of toric IOL implantation in traumatic aniridia, aphakia and corneal astigmatic eye: a case report

Yan Shao, Rong Luan, Ju-Ping Liu, Bo-Jie Hu, Xiao-Rong Li

Tianjin Key Laboratory of Retinal Functions and Diseases, Tianjin Branch of National Clinical Research Center for Ocular Disease, Eye Institute and School of Optometry, Tianjin Medical University Eye Hospital, Tianjin 384300, China

Co-first authors: Yan Shao and Rong Luan

Correspondence to: Xiao-Rong Li. Tianjin Key Laboratory of Retinal Functions and Diseases, Tianjin Branch of National Clinical Research Center for Ocular Disease, Eye Institute and School of Optometry, Tianjin Medical University Eye Hospital, Tianjin 384300, China. xiaorli@163.com

Received: 2023-01-30 Accepted: 2023-07-17

DOI:10.18240/ijo.2023.09.26

Citation: Shao Y, Luan R, Liu JP, Hu BJ, Li XR. Supporting suture combined scleral fixation of toric IOL implantation in traumatic aniridia, aphakia and corneal astigmatic eye: a case report. *Int J Ophthalmol* 2023;16(9):1559-1560

Dear Editor,

Ocular trauma can cause severe visual functional impairment. The management is often challenging due to multi-structures affected. Toric intraocular lens (IOL) implantation can be an effective method for the treatment of traumatic corneal astigmatism^[1]. Because of the optic design, the toric IOLs require more precise centration. Conventional toric IOL fixation methods require two-point fixation, which make the IOL tilting unpredictable, and have not been the first choice for patients without sufficient capsule and iris support. Now, we report a rare case of a woman with posttraumatic aniridia, aphakia and astigmatism who underwent toric IOL implantation, and the management of intraoperative IOL tilting.

The study was conducted in accordance with the principles of the Declaration of Helsinki. The informed consent was obtained from the subject.

CASE PRESENTATION

A 63-year-old woman with traumatic aniridia, aphakia, corneal astigmatism presented at our hospital complaining of low visual acuity. The patient underwent a stage I left eye debridement and suturing at a local hospital after trauma, with

removal of the lens and iris. Two months later, she was seen in our hospital, with the diagnosis of rhegmatogenous retinal detachment, aphakic eye, and aphakia eye, and she received pars plana vitrectomy with gas tamponade. Three months after the vitrectomy, the patient is proposed for IOL implantation surgery. The corneal topography with Scheimpflug imaging showed astigmatism (K1: 47.28 D, K2: 42.81 D, astigmatism 4.46 D; Figure 1). Due to the high astigmatism of the cornea, a toric IOL (SN6AT series, Alcon Inc.) was planned. The patient's data were sent to the manufacturer for IOL calculation, and a toric IOL with a sphere of 25.0 D and cylinder of 6.0 D to be aligned on the 62-degree axis was selected (SN6AT series, Alcon Inc.). This toric IOL is hydrophilic acrylic with a double-loop design.

Two-point suture fixation was adopted for toric IOL implantation. A surgical marker was used to stain the horizontal meridian (0°). Then we calculated that suture point angulation with axes of toric IOL was about 52°^[2]. Then another two marks of fixation point were stained on the limbus where the astigmatic axes (62°) rotate 52° counter clockwise (114°; Figure 2A). The 27-gauge infusion port was placed to maintain intraocular pressure since previously vitrectomy history. Partial-thickness scleral flaps were created and a 10-0 polypropylene suture needle was inserted into a 27-gauge needle to exit at the opposite side. A superior, clear corneal incision was created, the suture was externalized, separated and the ends fixed to the toric IOL trailing haptic. The toric IOL was inserted and the sutures were secured in the sclera after tension was adjusted^[3].

To avoid the tilting of IOL postoperatively because of aniridia in this case, extra-supporting was provided using a 10-0 poly-propylene suture in the coronal plane of the horizontal meridian. Two fornix-based conjunctival flaps with snip incisions 2 mm apart from the corneal limbus were made on the horizontal meridian. The 27-gauge needle was inserted into the eye passed behind the toric IOL, and the suture knots were tied under the conjunctiva. The toric IOL was steadily aligned on the 62° axis (Figure 2B, 2C).

Preoperatively, the patient's visual acuity was fingers counting. The best corrected visual acuity at postoperatively 1d was

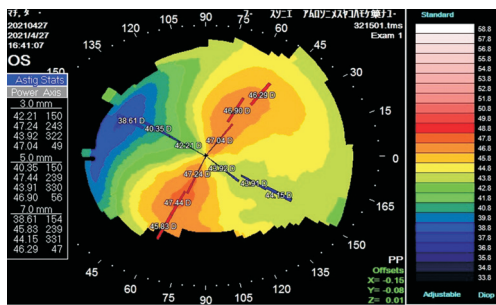


Figure 1 Scheimpflug imaging of the corneal front surface of the left eye with corneal astigmatism.

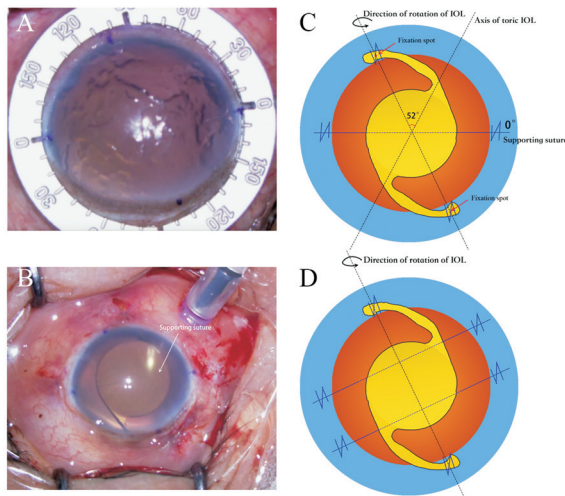


Figure 2 Photographs and schematic diagrams showing position of toric IOL and supporting suture A: A 114° counterclockwise rotation from the horizontal meridian was marked; B: Intraoperative photographs showing the position of toric IOL with supporting suture; C: Schematic diagram showing tilting direction of the toric IOL, and the suture support was provided in the coronal plane of the horizontal meridian. The angle between two black dotted line was about 52°; D: Schematic diagram showing two sutures support is provided perpendicular to the axis of rotation beside the visual axis. IOL: Intraocular lens.

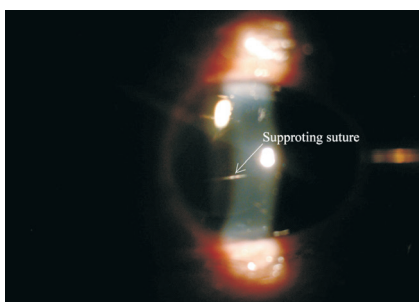


Figure 3 One-year postoperative slit lamp image with a well-placed supporting suture.

20/100 and recovered to 20/50 in 1y with the toric IOL implantation. The refractive cylinders decreased significantly from 4.46 to 1.25 D. The supporting suture is stable and the patient has no sense of occlusion one year after surgery (Figure 3). No postoperative complications were reported.

DISCUSSION

Combined aniridia and corneal astigmatism in traumatic eyes appear as a challenging situation. According to the

eye conditions, extended surgical treatments with different techniques are demanded.

To our knowledge, this is the first published report of suture combined scleral fixation of toric IOL implantation in traumatic aniridia, aphakia and corneal astigmatic eye. It is often necessary to implant a black diaphragm IOL or fix iris prosthesis and IOL to the sclera to provide stable position without tilt or torque^[4-5]. However, in order to observe the fundus clearly, we decided to implant the toric IOL without artificial diaphragm at the first stage. This requires additional support to limit the tilting of the IOL due to absence of the iris. Hence, we formed a second retention suture passed behind the IOL to ensure the stability of IOL. The only concern of the retention suture across the optic axis is the side effect of visual quality. Although this patient did not experience any IOL deviation and dislocation or visual disturbance during the follow-up process, we still hypothesize that the better method is to establish two supporting sutures perpendicular to the axis of rotation beside the visual axis, which has multiple advantages, including satisfactory maneuverability, achievement of better axial and rotation stability for the IOL, and avoidance of visual occlusion (Figure 2D).

In summary, the supporting suture make possible the scleral fixation of toric IOL as it is quick, easy, little traumatic, and the intraoperative complications can be minimized. Because of the rarity of the patient’s condition, it is difficult to include multiple patients for follow-up study, which is only reported as an individual case. However, longer follow-up times are needed to better determine the incidence of long-term complications with this method and how to avoid them.

ACKNOWLEDGEMENTS

Foundation: Supported by Tianjin Key Medical Discipline (Specialty) Construction Project (No.NTJYXZDXK-037A).

Conflicts of Interest: Shao Y, None; Luan R, None; Liu JP, None; Hu BJ, None; Li XR, None.

REFERENCES

- Vianna LMM, Prescott CR, Ferraz LO. Trifocal toric intra-ocular lens implantation in pediatric traumatic cataract. *Am J Ophthalmol Case Rep* 2020;17:100575.
- Pan QT, Yang ZW, Chen XM, et al. Suturing technique for scleral fixation of toric intraocular lens in the traumatic aphakic eye with corneal astigmatism. *Eur J Ophthalmol* 2019;29(1):100-105.
- Fiore T, Messina M, Muzi A, et al. Comparison of two different scleral fixation techniques of posterior chamber Carlevalle lens. *Medicine (Baltimore)* 2021;100(32):e26728.
- Chen YJ, Wu PC. Favorable outcome using a black diaphragm intraocular lens for traumatic aniridia with total iridectomy. *J Cataract Refract Surg* 2003;29(12):2455-2457.
- Watanabe N, Kobayakawa S. A case of foldable artificial iris implantation for treatment of postcataract surgery aniridia. *Case Rep Ophthalmol* 2023;7-12.