

MP-3 microperimeter in early primary open angle glaucoma with a new pattern

Shuang Liang¹, Li-Tao Wang², Xiao-Li Liu¹, Jia-Liang Duan¹, Dan-Yan Liu¹

¹Department of Ophthalmology of the Second Hospital of Hebei Medical University, Shijiazhuang 050000, Hebei Province, China

²Department of Ophthalmology, Shijiazhuang People's Hospital, Shijiazhuang 050000, Hebei Province, China

Correspondence to: Dan-Yan Liu. Department of Ophthalmology of the Second Hospital of Hebei Medical University, Shijiazhuang 050000, Hebei Province, China. liudanyan@hebmh.edu.cn

Received: 2023-01-22 Accepted: 2024-02-23

Abstract

• **AIM:** To investigate macular microperimetry in patients with early primary open angle glaucoma (POAG) using a new custom-made pattern, and analyze the characteristics of macular sensitivity.

• **METHODS:** This case-control study included 38 patients with POAG, who were divided into pre-perimetric glaucoma (18 eyes of 18 patients), early-stage (20 eyes of 20 patients), and control (20 eyes of 20 patients) groups. All subjects underwent standard 24-2 Humphrey visual field test. An MP-3 microperimeter with a new custom-made pattern (28 testing points distributed in four quadrants, covering the central 10° of the retina) was used to evaluate macular sensitivity. Ganglion cell complex (GCC) thicknesses were examined using an RS-3000 Advance OCT system. The features of structure and function were analysed per quadrant.

• **RESULTS:** The pre-perimetric glaucoma group had significantly lower inferior hemifield macular sensitivity compared to controls ($P < 0.05$). The early-stage POAG group had significantly lower average, inferior hemifield, inferonasal, and inferotemporal mean sensitivities compared to the pre-perimetric glaucoma group ($P < 0.05$), and lower macular sensitivity in all sectors compared to controls ($P < 0.05$). Regarding GCC thickness, all sectors in the early-stage POAG group became thinner compared to those in controls ($P < 0.05$); whereas all sectors in the early-stage POAG group, except the superonasal quadrant, became thinner compared to those in the pre-perimetric glaucoma group ($P < 0.05$). Macular sensitivity and GCC

thickness were significantly associated in each sector. The inferotemporal quadrant had the highest correlation coefficients (0.840). The structure-function relationship for the inferonasal and inferotemporal sectors was stronger compared to the corresponding superior sectors.

• **CONCLUSION:** Microperimetry reveals variations in macular sensitivity in patients with early glaucoma earlier than conventional perimetry, particularly in pre-perimetric glaucoma cases in which it might be undetectable by conventional methods. The new custom-made pattern may improve the accuracy of microperimetry by enhancing point arrangement and reducing fatigue effects. Macular sensitivity measured by MP-3 with this pattern shows statistically significant structural and functional associations with the thicknesses of the GCC.

• **KEYWORDS:** early primary open angle glaucoma; macular sensitivity; microperimetry; optical coherence tomography; ganglion cell complex

DOI: 10.18240/ijo.2024.05.10

Citation: Liang S, Wang LT, Liu XL, Duan JL, Liu DY. MP-3 microperimeter in early primary open angle glaucoma with a new pattern. *Int J Ophthalmol* 2024;17(5):861-868

INTRODUCTION

Glaucoma is a degenerative optic neuropathy characterized by optic nerve atrophy and visual field (VF) defects. Its pathological basis is selective retinal ganglion cell (RGC) apoptosis. Histopathological studies confirmed that RGC loss in the macular area could be detected in early glaucoma^[1]. However, VF defects could be detected only when the loss becomes severe enough. Standard automated perimetry (SAP) is commonly used to assess the VF; the 24-2 and 30-2 test patterns are preferred in glaucoma. The test points of the patterns were spaced every 6°, with only 12 test points within the central 10° with the highest RGC density. Detecting early glaucomatous VF defects in eyes with early structural abnormalities is difficult^[2].

Microperimetry allows performing an electronic view field contemporarily to display stimulated dots within the ocular fundus. The two VF examination methods have satisfactory

conformity^[3-4]. In microperimetry, stimuli are projected directly onto the retina, and an accurate test-retest of the same retinal point is monitored using eye-tracking technology. Therefore, a subtle reduction in mean sensitivity (MS) can be detected^[3].

No standard microperimetry test strategy exists for macular areas in early glaucoma^[5-7]. The test patterns in previous studies had numerous test points, which is time-consuming. However, when the analysis was performed, only some points were selected^[7]. Therefore, we designed a new pattern based on ganglion cell damage characteristics in the macular area of early glaucoma to complete microperimetry quickly and efficiently and to improve efficiency and accuracy. This study aimed to perform microperimetry in patients with pre-perimetric glaucoma (PPG) and early primary open angle glaucoma (POAG) using a custom-made pattern and evaluate the characteristics and correlation between RGCs and macular MS obtained by microperimetry.

SUBJECTS AND METHODS

Ethical Approval This study was performed according to the tenets of the Declaration of Helsinki and was approved by the local Ethics Committee of our hospital (No.2021-R489). Written informed consent was obtained from all the patients in the study.

Patients with POAG and normal controls were recruited from the outpatient clinic between December 2021 and December 2022. The patients with POAG were divided into the PPG and early-stage POAG groups based on the degree of VF damage.

Inclusion and Exclusion Criteria The inclusion criteria for the PPG group were: elevated intraocular pressure (IOP; ≥ 21 mm Hg by Goldmann applanation tonometry) without anti-glaucoma drugs; open angles with gonioscopy; typical glaucomatous optic disc changes: neuroretinal rim thinning, excavation, or notching, increased cupping, and inter-eye cup asymmetry >0.2 ; and no abnormalities in conventional static perimetry^[8]. The early-stage POAG group included patients with elevated IOP (≥ 21 mm Hg) that were not being treated with anti-glaucoma drugs, with open angles, with gonioscopy, with one of the typical glaucomatous optic disc changes enumerated above, and with VF loss meeting the standard of the Hodapp-Parrish-Anderson classification system: mean deviation (MD) <-6 dB; $<25\%$ of the points depressed below the 5% level, and <10 points depressed below the 1% level on the pattern deviation plot; all point in the central 5° must have a sensitivity of at least 15 dB^[9]. In the control group, patients, limited to 50 and 65 years old, with IOP ≤ 21 mm Hg, without a family history of glaucoma, without glaucomatous optic disc changes, with cup-to-disc ratio <0.5 , with a difference of <0.2 between the two eyes, with normal anterior chamber, and with conventional static perimetry were included.

Participants with best-corrected visual acuity <0.6 , refractive error exceeding -3 D spherical equivalent, abnormal pupil diameter, muddy optical media, a history of ocular surgery or laser treatment, any macular disease, or VF defect caused by intracranial lesions, oral medications or other systemic diseases were excluded.

Ophthalmologic Examination All participants underwent an adequate optic examination, including visual acuity, slit lamp, IOP measurement, gonioscopy, and fundus examination. SAP (at least two reliable and consistent tests) was performed using the Humphrey 24-2 standard strategy (Humphrey Field Analyzer; Carl Zeiss Meditec, Inc., Dublin, CA, USA). The right eye was chosen if both eyes met the inclusion criteria.

Microperimetry Examinations with Custom-Made Pattern

The MP-3 microperimeter (NIDEK Co., Ltd., Aichi, Japan) was used to evaluate retinal sensitivity with a Goldmann I stimulus and a 4-2 fast strategy. The background luminance was 31.4 asb, and the stimulus dynamic range was 34 dB. We created a specific stimuli pattern with a built-in pattern editor to represent the macular region with 28 testing points distributed in four quadrants (superonasal, superotemporal, inferonasal, and inferotemporal), covering the central 10° of the retina (Figure 1A). The fixation target was a single red cross with a 1° diameter. The procedure was performed in a dim room without pupil dilation. The interval between the microperimetry examination and the SAP testing was <4 wk. The 28 points covering the central 10° diameter constituted three circles centred in the macular fovea: the inner ring (4°) and middle ring (6°) comprised eight points each, whereas the outer ring (8°) comprised 12 points (Figure 1A).

Optical Coherence Tomography Angiography

Measurements Optical coherence tomography angiography (OCTA) was performed using an RS-3000 Advance OCT system (NIDEK). Raster scanning over a 6×6-mm² area automatically centred on the fovea was conducted at a scan density of 256 A-scans (horizontal) ×256 B-scans (vertical; Figure 2). The central 1.5-mm diameter area was not analysed. Ganglion cell complex (GCC) thickness was measured between the internal limiting membrane and the outer boundary of the inner plexiform layer. Automated measurement was provided by the built-in software (Figure 2A). However, we checked and manually adjusted the segmentation if necessary. In this investigation, the instrument provided superior hemifield, inferior hemifield, and quadrant GCC thickness values, including superonasal, superotemporal, inferonasal, and inferotemporal, used for the analysis (Figure 2B). The average GCC thickness was the average of the superior and inferior hemifields. The GCC thickness of the four quadrants was the average of the inner ring of 3 mm and the outer ring of 6 mm in each sector.

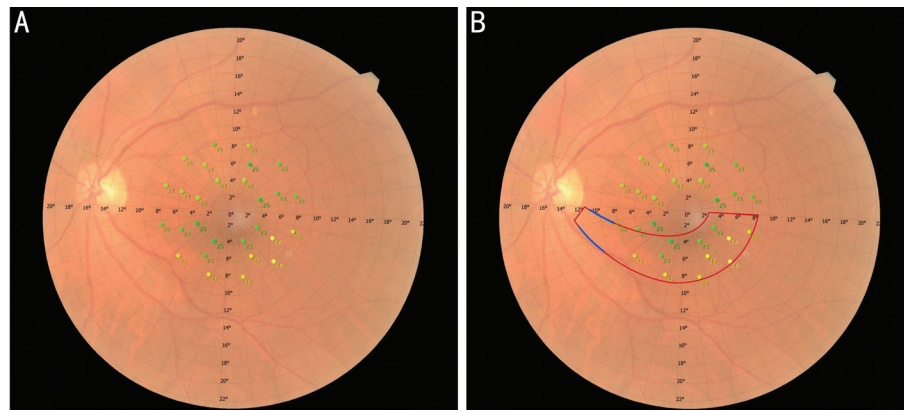


Figure 1 Microperimetry of a 54-year-old male patient diagnosed with early-stage POAG A: A new stimuli pattern with 28 testing points representing the 10° macular region; B: The region within the blue slanted lines was called the “MVZ” of the disc. The region within the red boundaries contained the RGCs that project to the MVZ region and was believed to be more vulnerable in the macular area^[1]. POAG: Primary open angle glaucoma; MVZ: Macular vulnerability zone; RGCs: Retinal ganglion cells.

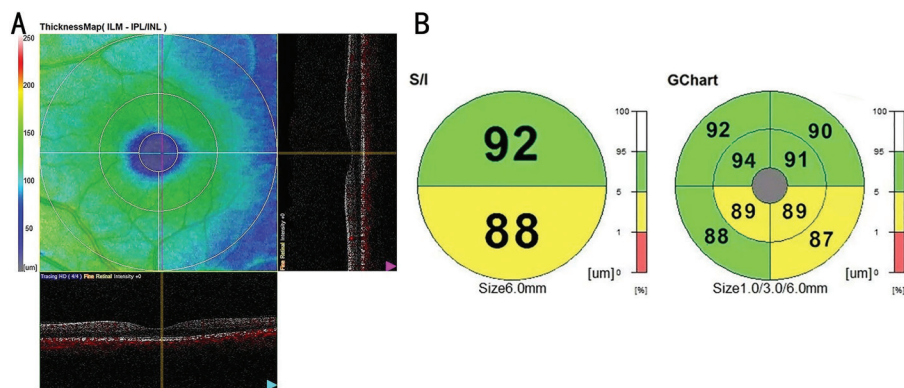


Figure 2 Optical coherence tomography angiography images acquired from the RS-3000 advance OCT in the glaucoma model A: Measured scope of the macular area; B: The ganglion cell complex thickness maps of the patient in Figure 1. OCT: Optical coherence tomography.

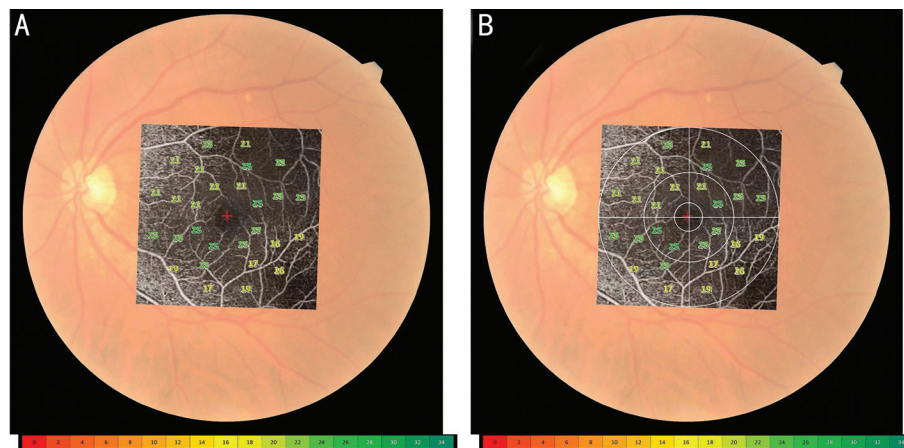


Figure 3 Microperimetry was overlaid with the OCTA images in the corresponding position of the colour fundus image A: Microperimetry was overlaid with OCTA image; B: White lines mark the measured scope and zoning in the OCTA image. OCTA: Optical coherence tomography angiography.

Mapping Structure to Function Microperimetry was overlaid with the OCTA images in the corresponding position of the colour fundus image (Figure 3A). The functional measurements of MP-3 with the custom-made pattern correlated exactly with the structural measurements of OCTA in the same sector (Figure 3B).

Statistical Analysis Statistical analyses were performed using SPSS version 25.0 (IBM Corp., Armonk, NY, USA).

Differences between the three groups were assessed using one-way analysis of variance followed by a post hoc LSD multiple comparison test. The Chi-square test was used to evaluate associations between categorical data. Correlations between GCC thickness and the corresponding VF MS was examined using Pearson’s correlation coefficient analysis. All continuous data of normal distribution are presented as the mean±standard deviation, non-normally distributed continuous data as

MP-3 microperimeter in POAG

Table 1 Clinical characteristics of the three groups

Parameters	PPG (n=18)	Early-stage POAG (n=20)	Normal (n=20)	F/ χ^2 /H	P
Age, y	56.83±4.29	59.05±4.20	57.05±4.78	1.483	0.236
Sex (male/female)	7/11	8/12	6/14	0.514	0.773
Eye (left/right)	7/11	9/11	5/15	1.813	0.404
BCVA	0.81±0.15	0.87±0.13	0.81±0.15	1.257	0.292
IOP (mm Hg)	22.83±3.00	30.3±4.28	14.75±2.22	111.915	<0.001
MD in HFA	-1.21±0.57	-4.51±1.1	-0.58±0.49	148.460	<0.001
PSD in HFA	1.85 (1.00, 2.00)	2.60 (2.00, 3.75)	1.67 (1.00, 2.25)	6.787	0.034
Measurement duration of microperimetry (s)	131.39±14.11	128.15±13.99	136.35±12.90	1.827	0.171

BCVA: Best-corrected visual acuity; IOP: Intraocular pressure; MD in HFA: Mean deviation in Humphrey Field Analyzer; PSD in HFA: Pattern standard deviation in Humphrey Field Analyzer; POAG: Primary open angle glaucoma; PPG: Pre-perimetric glaucoma.

Table 2 Comparison of mean sensitivity between groups

Parameters	PPG (n=18)	Early-stage POAG (n=20)	Normal (n=20)	F	P
Average	26.96±1.11	25.91±0.89 ^a	27.55±1.10 ^b	12.929	<0.001
Superior hemifield	27.06±1.18	26.4±1.06	27.48±1.10 ^b	4.733	0.013
Inferior hemifield	26.87±1.11	25.41±1.01 ^a	27.63±1.24 ^{a,b}	20.194	<0.001
Superonasal	27.29±1.25	26.79±1.12	27.29±1.32	1.061	0.353
Superotemporal	26.83±1.24	26.01±1.69	27.66±1.59 ^b	5.824	0.005
Inferonasal	26.90±1.13	25.64±1.22 ^a	27.55±1.20 ^b	13.389	<0.001
Inferotemporal	26.83±1.24	25.17±1.83 ^a	27.70±1.55 ^b	13.455	<0.001

^aComparison with PPG group, $P<0.05$; ^bComparison with early-stage POAG group, $P<0.05$. POAG: Primary open angle glaucoma; PPG: Pre-perimetric glaucoma.

Table 3 Comparison of ganglion cell complex between groups

Parameters	PPG (n=18)	Early-stage POAG (n=20)	Normal (n=20)	F	P
Average	94.23±5.54	86.45±5.84 ^a	102.04±7.31 ^{a,b}	30.560	<0.001
Superior hemifield	94.75±6.02	88.43±6.44 ^a	99.38±7.94 ^{a,b}	12.776	<0.001
Inferior hemifield	93.71±6.50	84.48±7.43 ^a	99.43±6.99 ^{a,b}	23.210	<0.001
Superonasal	94.33±7.36	89.45±6.47	104.60±9.21 ^{a,b}	19.717	<0.001
Superotemporal	95.17±6.49	87.40±8.20 ^a	98.63±8.72 ^b	10.542	<0.001
Inferonasal	101.09±6.36	86.95±7.10 ^a	105.75±9.63 ^b	30.772	<0.001
Inferotemporal	92.83±8.63	82.00±10.02 ^a	99.18±5.66 ^{a,b}	21.906	<0.001

^aComparison with PPG group, $P<0.05$; ^bComparison with early-stage POAG group, $P<0.05$. POAG: Primary open angle glaucoma; PPG: Pre-perimetric glaucoma.

median (interquartile range), with P -values <0.05 considered statistically significant.

RESULTS

Thirty-eight patients with glaucoma and 20 healthy participants (37 females and 21 males; mean age, 56.67±4.47y) were enrolled. The participants' characteristics are summarized in Table 1. The three groups had no differences in demographic characteristics, including age, sex, eye, and best-corrected visual acuity. IOP, MD, and pattern standard deviation (PSD) were significantly different among the three groups, as expected. The test duration of microperimetry examination was 131.98±13.86s.

The mean macular sensitivities of the average, superior hemifield, inferior hemifield, and four quadrants are shown in Table 2. The inferior hemifield MS of the PPG group was

significantly lower than that of normal controls. Statistical significance was observed in each sector of early-stage POAG compared with normal controls. The average, inferior hemifield, inferonasal, and inferotemporal MS of the early-stage POAG group were significantly lower than those of the PPG group.

The GCC thickness of the average, superior hemifield, inferior hemifield, and four quadrants are shown in Table 3. Compared with normal controls, the average, superior hemifield, inferior hemifield, superonasal, superotemporal, inferonasal, and inferotemporal GCC thicknesses decreased in the PPG group. All sectors in the early-stage POAG group became thinner than those in the normal controls. All sectors of the early-stage POAG group were thinner, except the superonasal quadrant, than those of the PPG group.

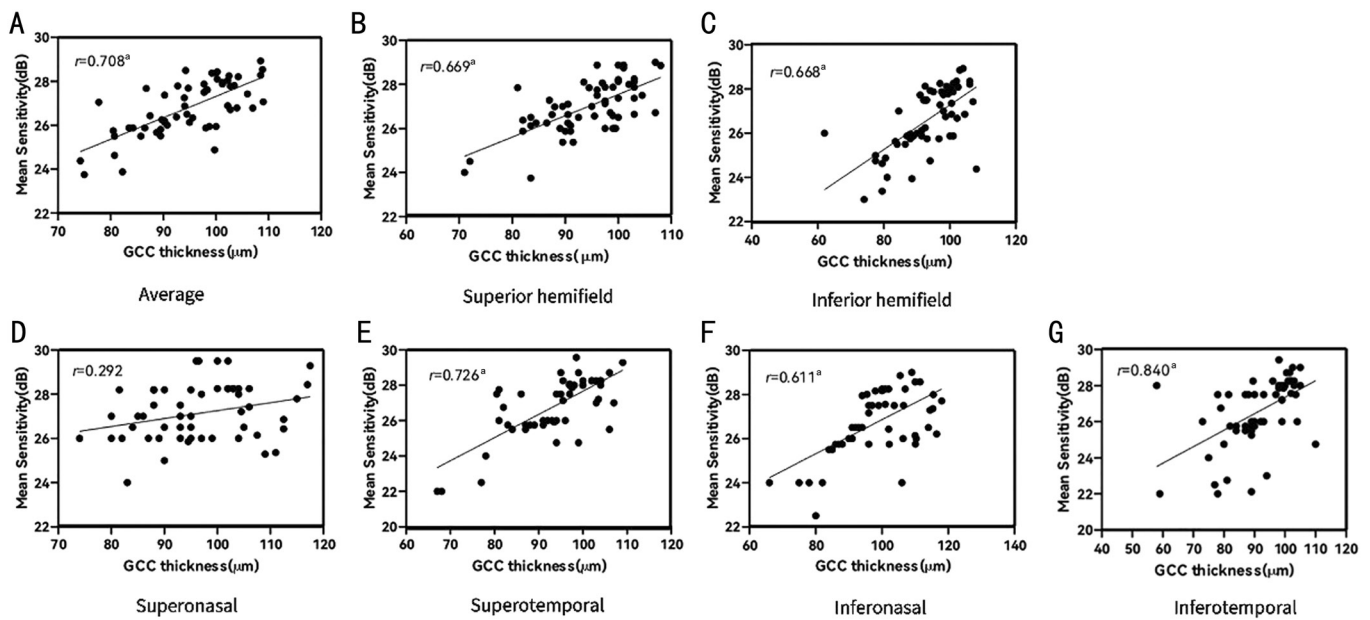


Figure 4 Scatterplots showing GCC thickness association and corresponding retinal MS A: Average thickness of the GCC vs macular MS; B: Superior hemifield thickness of the GCC vs superior hemifield macular MS; C: Inferior hemifield thickness of the GCC vs inferior hemifield macular MS; D: Superonasal thickness of the GCC vs superonasal MS; E: Superotemporal thickness of the GCC vs superotemporal MS; F: Inferonasal thickness of the GCC vs inferonasal MS; G: Inferotemporal thickness of the GCC vs inferotemporal MS. Pearson correlation coefficients, ^a $P < 0.001$, except in the superonasal sector, $P < 0.05$. MS: Mean sensitivity; GCC: Ganglion cell complex.

Correlation Analysis of GCC and Mean Sensitivity Figure 4 shows the structure-function relationship between the GCC thickness and the corresponding MS in the macula. In all sectors, except the superonasal, significant correlations were found [r -value: (0.611–0.840) and $P < 0.001$]; the highest Pearson’s correlation coefficient was 0.840 in the inferotemporal sector.

DISCUSSION

A region 10° from the foveal centre of the macula has the highest RGC density and is vital for visual function. Therefore, to conduct an intensive study on early glaucomatous damage in RGCs, attention should be paid to this special region. In SAP, rectangular test point arrangements with a spacing of 6°×6° (e.g., 24-2 or 30-2 grid) that omit the 6° central VF regions are most frequently used, and therefore lack detailed spatial information^[10]. A more detailed pattern with closely spaced test points is required to detect VF defects in early glaucoma more efficiently. Microperimetry can maximize the density of test points in disease-relevant regions of interest while minimizing the number of test points in uninformative regions^[5], which could meet the requirement. Microperimetry showed high reproducibility compared with conventional perimetry^[11].

In contrast, the SAP results of patients with unstable fixation were relatively unreliable, especially for detecting visual function in the macular area^[12]. MP-3 offers correction of subject eye movements with built-in eye trackers to generate an accurate projection of light stimuli in a specific region to be examined^[13]. In SAP, the magnitude of light reaching the

retina is influenced by pupil size. MP-3 has an optical aperture inside the body that makes light narrower than the pupil size to achieve a more accurate visual sensitivity assessment^[14].

There has been no uniform pattern for patients with glaucoma using microperimetry. Most research carried out 68 test points positioned identically to those in the SAP 10-2 test grid within 10° of the macular area^[6,14]. Matsuura *et al*^[14] performed microperimetry in patients with glaucoma, projecting 68 stimuli to the macular area. The measurement durations for the MP-3 test were 404s±84s for the net tracking duration and 629s±175s in total, including the time required to align the eye at the start of the test. The authors proposed that fatigue effects could reduce MS, interfering with the accuracy of the results^[14]. Huang *et al*^[7] adjusted the test points, leaving 40 stimulus locations covering the central 10° diameter. However, only some of these points were selected to further analyse structure-function associations.

Therefore, a new microperimetry pattern for patients with early glaucoma was designed for the macular area. The testing points were equally distributed in four quadrants, and points located on the central horizontal and vertical axes were excluded to ensure the accuracy of structure-function association analysis. In addition, the setting was in accordance with the sector divided in the built-in GCC thickness measurement of NIDEK RS-3000 Advance OCT (Figure 3B). Fewer test points indicated a shorter test duration. The test duration at this point was 131.98±13.86s, which is shorter than that in previous reports. The inner ring covers the centre 4°

from the foveal centre to minimize the impact of anatomical displacement of the RGCs^[15]. RGC displacement is a unique feature of the inner retina in the macular region that needs to be considered when comparing structural and functional measurements. RGCs receiving a stimulus in the parafoveal region are displaced toward the periphery for the location of their corresponding photoreceptors. They are connected to their corresponding photoreceptors *via* Henle's fibres, which have an oblique pathway in the parafoveal region^[16]. The effect of displacement was highest at the central eccentricity ring. Raza *et al*^[15] reported a high correlation coefficient outside 3.4° in radius, and this is the reason we chose a 4° radius on the fovea as the inner ring. The strongest structure-function correlation has been reported to occur at eccentricity 5°–7°^[17], and the RGC density gradually decreases beyond 8°^[18]; therefore, the middle ring of our study was set at 6° and the outer ring at 8° from the foveal centre. Size I was chosen, rather than size III, as the target. Although the size III target is widely used in conventional perimetry and microperimetry, the RGC receptive fields overlap with each other, particularly within 10° of the fovea. A target of size III can simultaneously stimulate both the damaged and remaining cells, and thus cover up RGC loss. That is, a smaller target of size I is less influenced by the overlapping RGC receptive fields^[17].

This study showed that the MSs of patients with PPG and early-stage POAG were lower than that of normal controls. Especially in the PPG group, microperimetry could detect MS reduction omitted by the SAP. The change in the MS in the inferior hemifield sector had a stronger correlation compared to the superior hemifield. The PPG group had lower scores than the normal controls, and the early-stage POAG group had the lowest scores. Schiefer *et al*^[10] implemented conventional perimetry with regionally enhanced spatial resolution, revealing that glaucomatous VF loss affects the upper hemifield area and that the corresponding RGC lesion was in the inferior hemifield area. Hood *et al*^[18] also proposed that VF damage was more pronounced in the superior hemifield. The author designated the region in the inferior hemifield of the macula as the more vulnerable region (Figure 1B, red frame). Between the four quadrants, in our study, the MSs of the inferonasal and inferotemporal quadrants of the POAG group were lower than those of the normal controls and PPG group. There was no such difference between the superonasal and superotemporal quadrants. We attributed this to the axons of RGCs located in the inferior macular area projecting to the macular vulnerability zone of the disc (Figure 1B, blue slanted lines). The macular vulnerability zone is an emerging concept that integrates the peripapillary and macular areas^[18-19]. It is a high-risk inferior arcuate region of the disc, which collects the axons of the inferonasal and inferotemporal quadrants. Axons

from the superior macula enter the temporal quadrant of the disc, which is relatively less affected in early glaucoma.

In recent years, more research has focused on the inner macular layers of patients with early glaucoma benefiting from OCT development^[20]. The GCC and ganglion cell-inner plexiform layer (GCIPL) are two important indicators. The GCC includes the retinal nerve fiber layer (RNFL), ganglion cell layer, and inner plexiform layer thickness, which is composed of ganglion cell axons, cell bodies, and dendrites. Kim *et al*^[11] found that GCC thickness appears to be a better diagnostic marker for early glaucoma than peripapillary RNFL thickness. Studies have confirmed the diagnostic value of GCC in early glaucoma^[21]. When it comes to the structure-function relationship within central 10°, Ohkubo *et al*^[2] found that GCC is the most useful parameter compared with RNFL, RGC, and GCIPL, which can be attributed to RGC displacement.

The built-in GCC scan mode for glaucoma of RS-3000 Advance OCT was used for the GCC thickness measurement in this study, thus avoiding the error of manual measurement to the greatest degree. By reducing the impact of spherical equivalents on GCC thickness^[22], cases whose refractive error exceeded -3 D were eliminated. In our study, the average, superior hemifield, inferior hemifield, superonasal, superotemporal, inferonasal, and inferotemporal GCC thicknesses of the PPG group were lower than those of the normal controls. All sectors in the early-stage POAG group became thinner than those in the normal controls. When compared with those of the PPG group, all sectors of the early-stage POAG group were thinner, except the superonasal quadrant.

The structure-function relationship was another important indicator that we focused on in patients with early-stage POAG. Rao *et al*^[23] observed 45 patients with POAG at the central 10° of the macula and found that the visual sensitivity measured with SAP and microperimetry correlated with the GCIPL similarly. Matsuura *et al*^[14] reported a better structure-function relationship of microperimetry than that of SAP. This study showed a strong correlation between the GCC thickness and microperimetry in every sector. The strongest correlation was found in the inferotemporal sector ($r=0.840$, $P<0.001$). Among the four quadrants, the correlation of the inferonasal quadrant was stronger than that of the superonasal quadrant, that of the inferotemporal quadrant was stronger than that of the superotemporal quadrant, and that of the temporal quadrant was stronger than the nasal quadrant. According to Hood *et al*^[18], the inferior hemifield of the macula is the most vulnerable region. The structural and functional damage in this area is more prone than that of the superior hemifield. The structure-function relationship was stronger; in other words, strong correlations were found much earlier. Based on the anatomical

features of RGCs, the thickness of GCC was thinner in the temporal of the macula than the nasal^[18], which means fewer RGC and axons in the temporal quadrant. Therefore, the effect of GCC apoptosis was more significant in the temporal retina, more likely to show a reduction in MS, and the structure-function relationship was stronger. This finding is consistent with the deduction of Sato *et al*^[6].

This study had some limitations, including the relatively small sample size. Although we did not observe an age effect in this relatively small sample, a larger study is needed to clarify this issue. The present study did not cover the full spectrum of glaucoma, such as normal-tension glaucoma. Future studies should more closely examine the diagnostic performance of microperimetry in glaucoma.

In conclusion, microperimetry could reveal variations in macular sensitivity in patients with early glaucoma earlier than conventional perimetry, particularly in PPG cases, which might be undetectable with the latter. The new custom-made pattern cut the test time to within 3min, thus improving the accuracy by reducing fatigue effects. Finally, the data is easy to acquire by the built-in pattern editor of MP-3 microperimeter, without extra expense. The functional measurements of macular sensitivity with this pattern correlated exactly with the structural measurements of OCTA in the same sector, showing statistically significant structure-function associations.

ACKNOWLEDGEMENTS

Authors' contributions: Liang S designed and wrote the research study; Wang LT and Liu XL analyzed and interpreted the data; Duan JL and Liu DY contributed to critical revision of the article. All authors approved the manuscript.

Foundation: Supported by Hebei Medical Science Research Project Program (No.20230067).

Conflicts of Interest: Liang S, None; Wang LT, None; Liu XL, None; Duan JL, None; Liu DY, None.

REFERENCES

- 1 Kim NR, Lee ES, Seong GJ, Kim JH, An HG, Kim CY. Structure-function relationship and diagnostic value of macular ganglion cell complex measurement using Fourier-domain OCT in glaucoma. *Invest Ophthalmol Vis Sci* 2010;51(9):4646-4651.
- 2 Ohkubo S, Higashide T, Udagawa S, *et al*. Focal relationship between structure and function within the central 10 degrees in glaucoma. *Invest Ophthalmol Vis Sci* 2014;55(8):5269-5277.
- 3 Tian T, Cai Y, Li M, Fang Y, Pan YZ. A comparison among microperimetry, standard automated perimetry and spectral domain optical coherence tomography in the evaluation of the macula in glaucoma eyes with hemifield defects. *Ophthalmol Ther* 2022;11(1):239-248.
- 4 Tepelus TC, Song S, Nittala MG, Nassisi M, Sadda SR, Chopra V. Comparison and correlation of retinal sensitivity between microperimetry and standard automated perimetry in low-tension

- glaucoma. *J Glaucoma* 2020;29(10):975-980.
- 5 Pfau M, Jolly JK, Wu ZC, Denniss J, Lad EM, Guymer RH, Fleckenstein M, Holz FG, Schmitz-Valckenberg S. Fundus-controlled perimetry (microperimetry): application as outcome measure in clinical trials. *Prog Retin Eye Res* 2021;82:100907.
- 6 Sato S, Hirooka K, Baba T, Tenkumo K, Nitta E, Shiraga F. Correlation between the ganglion cell-inner plexiform layer thickness measured with cirrus HD-OCT and macular visual field sensitivity measured with microperimetry. *Invest Ophthalmol Vis Sci* 2013;54(4):3046-3051.
- 7 Huang P, Shi Y, Wang X, Zhang SSM, Zhang C. Use of microperimetry to compare macular light sensitivity in eyes with open-angle and angle-closure glaucoma. *Jpn J Ophthalmol* 2012;56(2):138-144.
- 8 Mathews B, Le PH, Budenz DL, Mwanza JC. Agreement of diagnostic classification between structural parameters in pre-perimetric and early perimetric glaucoma. *J Glaucoma* 2023;32(4):301-306.
- 9 Kastner A, King AJ. Advanced glaucoma at diagnosis: current perspectives. *Eye (Lond)* 2020;34(1):116-128.
- 10 Schiefer U, Papageorgiou E, Sample PA, Pascual JP, Selig B, Krapp E, Paetzold J. Spatial pattern of glaucomatous visual field loss obtained with regionally condensed stimulus arrangements. *Invest Ophthalmol Vis Sci* 2010;51(11):5685-5689.
- 11 Leisser C, Palkovits S, Hirnschall N, Georgiev S, Findl O. Reproducibility of microperimeter 3 (MP-3) microperimetry in open-angle glaucoma patients. *Ophthalmic Res* 2020;63(3):302-308.
- 12 Scuderi L, Gattazzo I, de Paula A, Iodice CM, Di Tizio F, Perdicchi A. Understanding the role of microperimetry in glaucoma. *Int Ophthalmol* 2022;42(7):2289-2301.
- 13 Molina-Martín A, Pérez-Cambrodí RJ, Piñero DP. Current clinical application of microperimetry: a review. *Semin Ophthalmol* 2018;33(5):620-628.
- 14 Matsuura M, Murata H, Fujino Y, Hirasawa K, Yanagisawa M, Asaoka R. Evaluating the usefulness of MP-3 microperimetry in glaucoma patients. *Am J Ophthalmol* 2018;187:1-9.
- 15 Raza AS, Cho J, de Moraes CGV, Wang M, Zhang X, Kardon RH, Liebmann JM, Ritch R, Hood DC. Retinal ganglion cell layer thickness and local visual field sensitivity in glaucoma. *Arch Ophthalmol* 2011;129(12):1529-1536.
- 16 Montesano G, Ometto G, Hogg RE, Rossetti LM, Garway-Heath DF, Crabb DP. Revisiting the drasdo model: implications for structure-function analysis of the macular region. *Transl Vis Sci Technol* 2020;9(10):15.
- 17 Eura M, Matsumoto C, Hashimoto S, Okuyama S, Takada S, Nomoto H, Tanabe F, Shimomura Y. Test conditions in macular visual field testing in glaucoma. *J Glaucoma* 2017;26(12):1101-1106.
- 18 Hood DC, Raza AS, de Moraes CGV, Liebmann JM, Ritch R. Glaucomatous damage of the macula. *Prog Retin Eye Res* 2013;32:1-21.
- 19 Lee WJ, Park KH, Seong M. Vulnerability zone of glaucoma progression in combined wide-field optical coherence tomography event-based progression analysis. *Invest Ophthalmol Vis Sci* 2020;61(5):56.

MP-3 microperimeter in POAG

- 20 Yuksel Elgin C, Chen D, Al-Aswad LA. Ophthalmic imaging for the diagnosis and monitoring of glaucoma: a review. *Clin Exp Ophthalmol* 2022;50(2):183-197.
- 21 Wang YW, Xin C, Li M, Swain DL, Cao K, Wang HZ, Wang NL. Macular vessel density vs ganglion cell complex thickness for detection of early primary open-angle glaucoma. *BMC Ophthalmol* 2020;20(1):17.
- 22 Yao Y, Fu J, Li L, Chen WW, Meng ZJ, Su H, Dai W. Retinal and circumpapillary nerve fiber layer thickness and associated factors in children. *Eye (Lond)* 2021;35(10):2802-2811.
- 23 Rao HL, Januwada M, Hussain RSM, *et al.* Comparing the structure-function relationship at the macula with standard automated perimetry and microperimetry. *Invest Ophthalmol Vis Sci* 2015;56(13):8063-8068.