

Acanthamoeba keratitis in a tertiary referral hospital in central China: demographics, risk factors, clinical presentation, treatments and outcomes

Jia–Song Wang, Dan Zhao, Tian–Yu Yao, Xiao–Ying Jiang, Hua–Tao Xie, Ming–Chang Zhang

Department of Ophthalmology, Union Hospital, Tongji Medical College, Huazhong University of Science and Technology, Wuhan 430022, Hubei Province, China

Correspondence to: Hua-Tao Xie and Ming-Chang Zhang. Department of Ophthalmology, Union Hospital, Tongji Medical College, Huazhong University of Science and Technology, Wuhan 430022, Hubei Province, China. huataoxie@hust.edu.cn; mingc_zhang@hust.edu.cn

Received: 2024-07-18 Accepted: 2024-12-18

Abstract

• **AIM:** To investigate the demographics, risk factors, clinical presentation, treatments and outcomes of *Acanthamoeba* keratitis (AK) in a tertiary referral hospital in central China.

• **METHODS:** In this noncomparative, retrospective study, a total of 21 AK patients were enrolled between April 2020 and March 2023. All patients underwent anterior segment photography, *in vivo* confocal microscopy (IVCM), best-corrected visual acuity (BCVA) and anterior segment optical coherence tomography (AS-OCT).

• **RESULTS:** The most common potential predisposing factors were contact lens wearing (71.4%), mostly were students, and organic trauma (23.8%), mainly by outdoor workers. And 80.9% of patients were initially misdiagnosed with herpes keratitis. The clinical features were radial keratoneuritis 42.8% ($n=9$), crude salt-like granular dense infiltration 28.6% ($n=6$), and corneal ring infiltration 28.6% ($n=6$). Fifteen patients were completely cured by medical therapy, and six patients with corneal ring infiltration feature were performed conjunctival flap covering surgery (CFCS), three of them later underwent secondary deep anterior lamellar keratoplasty (DALK). All patients completed their follow-up at the Union Hospital, with a total of 20 patients (95.2%) had improved visual acuity after treatment, 1 had no change. Corneal scarring and vascularization were the two most common complications of AK in this study, with incidence rates of 85.7% and 28.6%, respectively.

• **CONCLUSION:** In central China, AK occurs predominantly in contact lens wearers, mainly in students with myopia

prevention and control. The radial keratoneuritis with crude salt-like granular dense infiltration can generally be effectively managed with medications. In contrast, corneal ring infiltration necessitates immediate surgical intervention. The CFCS combined with secondary DALK is effective for patients with high-risk AK in this condition.

• **KEYWORDS:** acanthamoeba keratitis; *in vivo* confocal microscopy; contact lenses

DOI:10.18240/ijo.2025.06.07

Citation: Wang JS, Zhao D, Yao TY, Jiang XY, Xie HT, Zhang MC. *Acanthamoeba* keratitis in a tertiary referral hospital in central China: demographics, risk factors, clinical presentation, treatments and outcomes. *Int J Ophthalmol* 2025;18(6):1016-1022

INTRODUCTION

Acanthamoeba keratitis (AK) is a rare parasitic infection of the cornea, if not diagnosed and treated promptly, which can lead to permanent blindness^[1]. *Acanthamoeba* is ubiquitous, living in soil and water, and is an opportunistic human pathogen. In developed countries, for the purpose of refractive and cosmetic wearing contact lens is the main external risk factors, AK estimate that about 86% of cases^[2]. In contrast, AK in developing countries is more commonly caused by ocular trauma, including stones, dust, mud, or plant materials, and water contamination^[3].

At present, there is no single efficient and effective drug that targets AK, thus early diagnosis of AK is essential to prevent the disease from progressing to an advanced stage^[4-5]. In clinical practice, patients with atypical lesions are easy to be misdiagnosed as herpes simplex keratitis, fungal or bacterial keratitis^[4,6-7], especially in the early stage of the disease or when ophthalmologists have insufficient knowledge of the disease. In terms of diagnosis, *Acanthamoeba* culture remains the gold standard but is less sensitive^[8-9]. In this context, *in vivo* confocal microscopy (IVCM) is considered the primary method for diagnosing AK, or serves as a confirmatory test and used to evaluate the progression of AK, due to its high sensitivity and specificity^[10]. The treatment course for AK is

often long and challenging, the trophozoite and cystic forms are highly drug resistant and may persist for months. In cases of AK that are poorly responsive to medical treatment or late diagnosis AK, often increases the likelihood of poorer final visual outcome and the need for therapeutic penetrating keratoplasty (PK), otherwise the eyeballs may be removed^[4].

Hubei Province, located in central China, has more than 58 million people, with nearly half of whom work in agriculture or outdoors and more than 3 million students, some of whom wear contact lenses for refractive. To improve outcomes, ophthalmologists are urgently needed to learn more about AK, however, the related data for central China is limited. Therefore, this study aims to describe the demographics, risk factors, presentation, treatments and outcomes of a tertiary referral hospital in central China.

PARTICIPANTS AND METHODS

Ethical Approval The medical history data of AK patients at Union Hospital, Tongji Medical College, Huazhong University of Science and Technology from April 2020 to March 2023 were retrospectively analyzed. The Ethics Committee of Wuhan Union Hospital approved this study (Approval No. UHCT230415) according to the tenets of the Declaration of Helsinki and waived the requirement for patients informed consent owing to the retrospective nature of this study.

Participants All patients underwent anterior segment photography, IVCN, best-corrected visual acuity (BCVA) and anterior segment optical coherence tomography (AS-OCT). The inclusion criteria were as follows: 1) typical *Acanthamoeba* cysts or trophozoites were observed in IVCN; 2) contact lens or corneal trauma-related eye infection had typical presentations, with a therapeutic response only to anti-amoebic agents; or 3) a positive result of laboratory examinations [cytological smear, the culture of amoebae, polymerase chain reaction (PCR), etc.]. The following patients were excluded: 1) *Acanthamoeba* was examined in a laboratory outside the United Hospital; 2) there is no IVCN record; or 3) AK cannot be definitely diagnosed because anti-amoeba therapy has been started before the visit. The following clinical data were collected: 1) demographic data (age, sex, risk factors, time of onset, history of diagnosis, clinical presentations and chief complaints); 2) ocular examination data (area of epithelial defect, width and depth of infiltration, presence, height of hypopyon, presence of endothelial plaque and satellite lesions); 3) details of medical and surgical management; 4) visual outcome and complications.

In Vivo Confocal Microscopy and Diagnosis IVCN was performed to check typical *Acanthamoeba* cysts or trophozoites as previously described^[11-12] by the same ophthalmologist, using the Heidelberg Retina Tomograph II with Rostock Cornea Module (Heidelberg, Germany). A typical

cyst is defined as a hyperreflective structure (approximately 10 to 15 μm) with a double-walled structure and a bright spot or signet ring appearance. The special arrangement of clusters and linear structures is another characteristic of cyst identification. In contrast, *Acanthamoeba* trophozoites are more difficult to identify because of their irregular shapes. The diameter of *Acanthamoeba* trophozoites is approximately 25-40 μm and the reflection density is medium. The nucleus of trophozoite is a circular dark area with a dense center and high reflectivity.

Medication and Surgical Procedures Patients diagnosed with AK received topical eye drops consisting of 0.02% Chlorhexidine and Ornidazole (5 mg/mL) every hour. Oral voriconazole (Pfizer, New York, USA) was given 200 mg twice daily. Slit-lamp examination recorded response to treatments during hospitalization. If there were no changes in the width or depth of the ulcer, or it worsened after 14d of medication treatment, operation would be considered. To avoid post-iris adhesions and reduce inflammation, 1% atropine and 0.1% bromfenac sodium eye drops were used.

Postoperative Management and Follow-Up All participants in this study were examined and continued to be regularly monitored for liver and kidney function. And complications were recorded and described in detail. Chlorhexidine and ornidazole were administered hourly and gradually reduced monthly. Oral voriconazole 200 mg twice daily for 4wk. AK healing was defined as the complete disappearance of epithelial defect, corneal infiltrates, hypopyon, and satellite lesion, and without the presence of cysts or trophozoites on IVCN examination. Failure was defined as corneal perforation or recurrence of AK or eyeball removal.

Statistical Analysis SPSS 25.0 was used for statistical analysis, and all aggregated data were expressed as mean \pm standard deviation (SD).

RESULTS

Baseline Characteristics Twenty-one patients with 8 males (38.1%) and 13 females (61.9%) detected *Acanthamoeba* cysts through IVCN were included in this study. The average age was 22.3 \pm 10.9y, ranging from 11 to 45y. All patients had monocular disease, including 10 right eyes (47.6%) and 11 left eyes (52.3%). In terms of occupation, 13 cases (61.9%) were students, 2 (9.5%) were white-collar workers, and 6 (28.6%) were outdoor workers (Table 1).

Corneal abrasions following mud or plant trauma were documented in 23.8% ($n=5$), contact lens wearing were recorded in 71.4% ($n=15$) of patients, no cause could be found in 1 patient (4.8%). Four patients (19.1%) complained of eye pain, were mainly at night. The time from the onset of symptoms to diagnosis ranged from 7 to 38d, with a mean of 19.3 \pm 9.1d. Seventeen patients (80.9%) were being treated as

Table 1 Demographic details of patients with *Acanthamoeba* keratitis

Items	Data
<i>n</i> =21	
Sex, <i>n</i>	
Male	8 (38.1%)
Female	13 (61.9%)
Age, y, mean±SD (range)	22.3±10.9 (11-45)
Eye, <i>n</i>	
Right	10 (47.6%)
Left	11 (52.3%)
Occupation, <i>n</i>	
Student	13 (61.9%)
White-collar worker	2 (9.5%)
Outdoor worker	6 (28.6%)

SD: Standard deviation.

herpes simplex keratitis, 1 patient (4.8%) was misdiagnosed as fungal keratitis and 3 patients (14.3%) as bacterial keratitis. Of all cases, 8 patients (38.1%) were used topical steroid before diagnosis. The average diameter of corneal infiltrates was 7.50±0.6 mm, ranging from 6.3 to 8.7 mm. The mean depth of corneal infiltrates by AS-OCT was 205.2 µm±101.4 µm, ranging from 120 to 480 µm. According to clinical features on presentation, there were three main categories (Figure 1), radial keratoneuritis (*n*=9, 42.8%), crude salt-like granular dense infiltration (*n*=6, 28.6%), and corneal ring infiltration (*n*=6, 28.6%), respectively (Table 2).

Treatments, Outcomes and Complications A total of 71.4% (15 of 21) of the patients with radial keratoneuritis and crude salt-like granular dense infiltration clinical features improved after topical drugs therapy. The rest, 28.6% of patients (6 of 21), both with corneal ring infiltration, responded poorly to medical treatment, and surgical intervention was performed. For surgical intervention, in order to reduce the recurrence rate of *Amoeba*, 6 patients underwent conjunctival flap covering surgery (CFCS) after receiving corneal debridement. Among them, 3 patients received secondary deep anterior lamellar keratoplasty (DALK; Table 3).

A total of 20 of 21 (95.2%) patients had improved visual acuity after treatment, 1 of 21 (4.8%) patients had no change in visual acuity, and no patient had decreased visual acuity after treatment. The patient lack of improvement of visual acuity was due to corneal perforation involving pupillary and severe corneal scar after CFCS, nevertheless, corneal transplantation was not performed because of the patient's financial difficulties (Table 3).

At the last follow-up (average 11.2±5.4, ranging from 3.5 to 26mo), no *Acanthamoeba* recurrence or graft rejection appeared, and no eyeballs were removed. Corneal scarring and vascularization were the two most commonly complications in our series, occurring in 85.7% and 28.6%, respectively.

Table 2 Characteristic of patients with *Acanthamoeba* keratitis *n*=21

Risk factor	Data, <i>n</i> (%)
Mud or plant trauma	5 (23.8)
Contact lens wear	15 (71.4)
Unknown	1 (4.8)
Complained of pain	4 (19.1)
Time from onset to diagnosis, d, mean±SD (range)	19.3±9.1 (7-38)
Misdiagnosed before diagnosis	
Herpes simplex keratitis	17 (80.9)
Fungal keratitis	1 (4.8)
Bacterial keratitis	3 (14.3)
Use of topical steroid before diagnosis	
Yes	8 (38.1)
No	13 (61.9)
Presentation AS-OCT measurements	
Infiltrate thickness, µm, mean±SD (range)	205.2±101.4 (120-480)
Infiltrate width, mm, mean±SD (range)	7.5±0.6 (6.3-8.7)
Corneal clinical sign	
Radial keratoneuritis	9 (42.8)
Crude salt-like granular dense infiltration	6 (28.6)
Ring infiltration	6 (28.6)

AS-OCT: Anterior segment optical coherence tomography; SD: Standard deviation.

Table 3 Analysis of treatment modalities and changes in visual acuity in patients with *Acanthamoeba* keratitis

Items	Data
<i>n</i> =21	
Treatment	
Drug	15 (71.4%)
Surgery	
CFCS	6 (28.6%)
CFCS+DALK	3 (14.3%)
Change in visual acuity	
Improved	20 (95.2%)
Not improved	1 (4.8%)
Depressed	0
Duration of therapy, d, mean±SD (range)	132.5±23.1 (95-172)
Complications	
Corneal scarring	18 (85.7%)
Corneal vascularization	6 (28.6%)
Follow-up, mo, mean±SD (range)	11.2±5.4 (3.5-26)

CFCS: Conjunctival flap covering surgery; DALK: Deep anterior lamellar keratoplasty; SD: Standard deviation.

Representative Case Reports

Case 1: radial keratoneuritis A 16-year-old female student because of improper wearing of orthokeratology, presented with typical radial keratoneuritis lesion in her right eye (Figure 2A, 2B). IVCM detected a large number of *Acanthamoeba* cysts (Figure 2C). She was well responded to topical and oral medications. After 128d treatment, the ulcer healed and the cornea became stable (Figure 2D, 2E). At 11mo follow-up, the BCVA was 0.8 although the central cornea remained mild

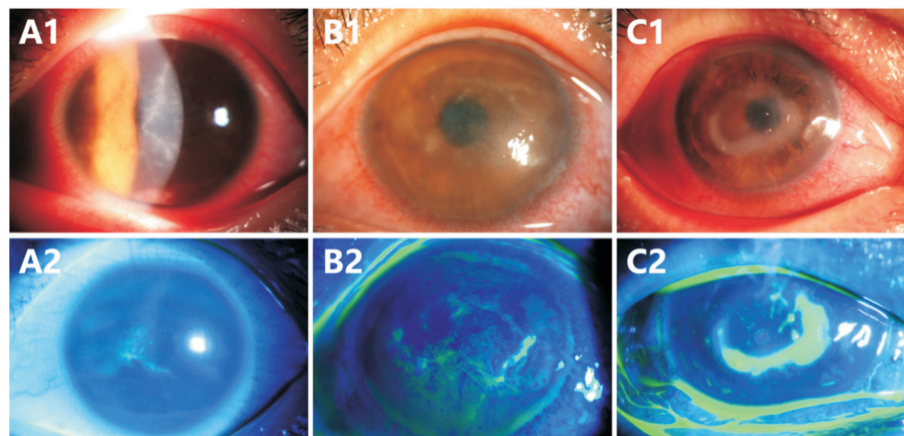


Figure 1 Slit-lamp photographs and examinations of radial keratoneuritis (A1, A2), crude salt-like granular dense infiltration (B1, B2), and corneal ring infiltration (C1, C2).

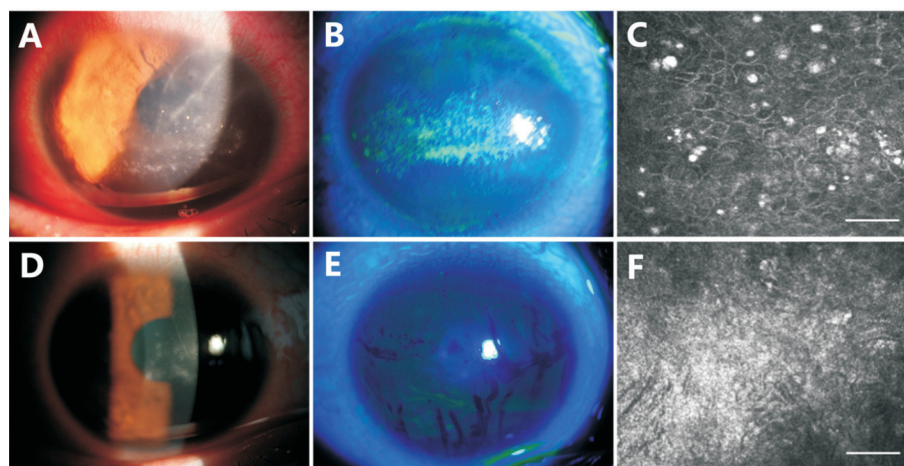


Figure 2 Case 1 radial keratoneuritis Slit-lamp photographs and examinations of a 16-year-old female with radial keratoneuritis (A, B). IVCM detected a large number of *Acanthamoeba* cysts (C). After 28d treatment, the ulcer healed and the cornea became stable (D, E). Reexamination of IVCM showed no *Acanthamoeba* cysts or trophozoites existing (F). Scale bar: 50 μ m. IVCM: *In vivo* confocal microscopy.

opacity. Reexamination of IVCM showed no *Acanthamoeba* cysts or trophozoites existing (Figure 2F).

Case 2: crude salt-like granular dense infiltration A 12-year-old male student was referred because of a 6.3 mm width of central corneal ulcer in his left eye after long time orthokeratology wearing (Figure 3A, 3B). In clinical practice, mainly showed with typical crude salt-like granular dense infiltration. IVCM revealed of *Acanthamoeba* cysts (Figure 3C). After 48d treatment, a stable ocular surface was obtained, but unfortunately, the corneal scarring and corneal vascularization involving the pupillary area (Figure 3D, 3E). AS-OCT showed the depth of corneal scarring was 698 μ m. Similarly, reexamination of IVCM showed no evidence of *Acanthamoeba* presence (Figure 3F). His BCVA was 0.08 at the 13mo follow-up.

Case 3: corneal ring infiltration A 39-year-old female patient visited our hospital because of a 6.5 mm width of central corneal ring ulcer in her right eye with unknown cause (Figure 4A). IVCM also revealed the presence of *Acanthamoeba* cysts (Figure 4B). AS-OCT showed the corneal

infiltrate thickness was 404 μ m. After 14d drugs treatment, there was no significant improvement (Figure 4C), then CFCS was performed (Figure 4D). A stable ocular surface was obtained with a leucoma and superficial conjunctiva 3mo postoperatively (Figure 4E) and reexamination of IVCM also showed no evidence of *Acanthamoeba*. A transparent cornea was restored 10mo after DALK (Figure 4F). AS-OCT showed the corneal thickness was 590 μ m and the residual host cornea was 100 μ m. Her BCVA was 0.6 at the 10mo follow-up.

Case 4: corneal ring infiltration with corneal perforation A 45-year-old farmer presented with a 7.0 mm width of central corneal ring infiltration lesion in his right eye because of plant trauma (Figure 5A). AK was also diagnosed by IVCM (Figure 5B) and later next-generation sequencing (NGS) result also showed *Acanthamoeba*. Under IVCM *Acanthamoeba* cysts were found at deep stroma layer, but didn't invade the corneal endothelial cells layer. He was poorly responded to topical and oral anti-amoeba medications after 14d treatment (Figure 5C) and then CFCS was performed (Figure 5D). Unfortunately, a central corneal perforation occurred 15d later (Figure 5E).

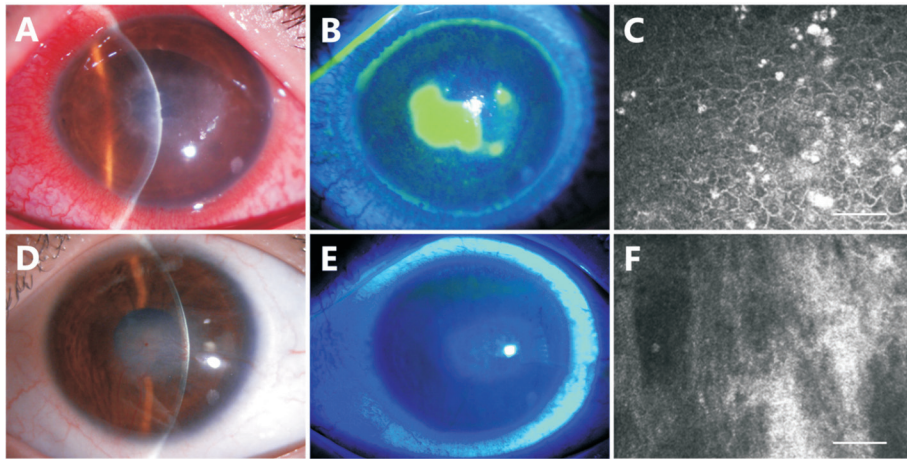


Figure 3 Case 2: photographs of a 12-year-old AK patient after contact lens wearing A corneal ulcer with typical crude salt-like granular dense infiltration was observed by slit-lamp examination (A, B). *Acanthamoeba* cysts were detected by IVCM (C). A stable ocular surface with corneal scarring and corneal vascularisation was obtained 48d after medical treatment (D, E). IVCM showed no evidence of *Acanthamoeba* presence (F). Scale bar: 50 μ m. AK: *Acanthamoeba* keratitis; IVCM: *In vivo* confocal microscopy.

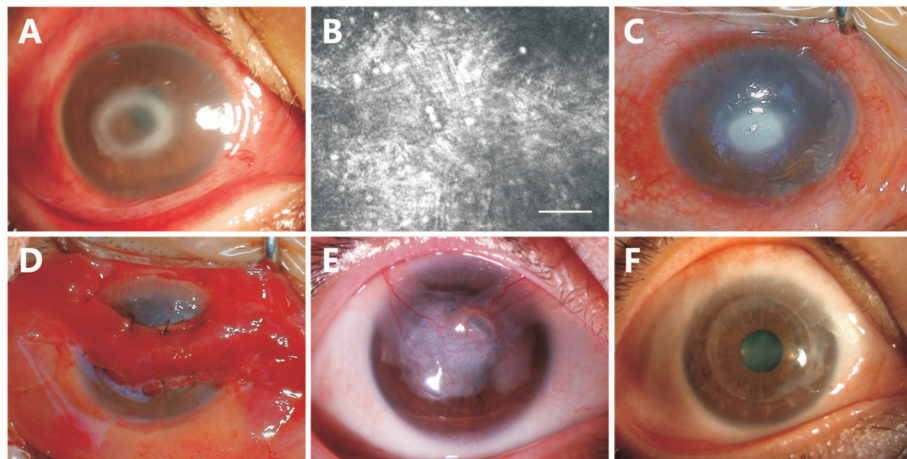


Figure 4 Case 3: photographs of a 39-year-old AK patient with unknown cause A corneal ulcer with ring infiltration was observed by slit-lamp examination (A). *Acanthamoeba* cysts were detected by IVCM (B). Drugs treatment was not effective after 14d (C), and CFCS was performed (D). A stable ocular surface was obtained 3mo postoperatively (E). A transparent cornea was restored 10mo after DALK (F). Scale bar: 50 μ m. AK: *Acanthamoeba* keratitis; IVCM: *In vivo* confocal microscopy; CFCS: Conjunctival flap covering surgery; DALK: Deep anterior lamellar keratoplasty.

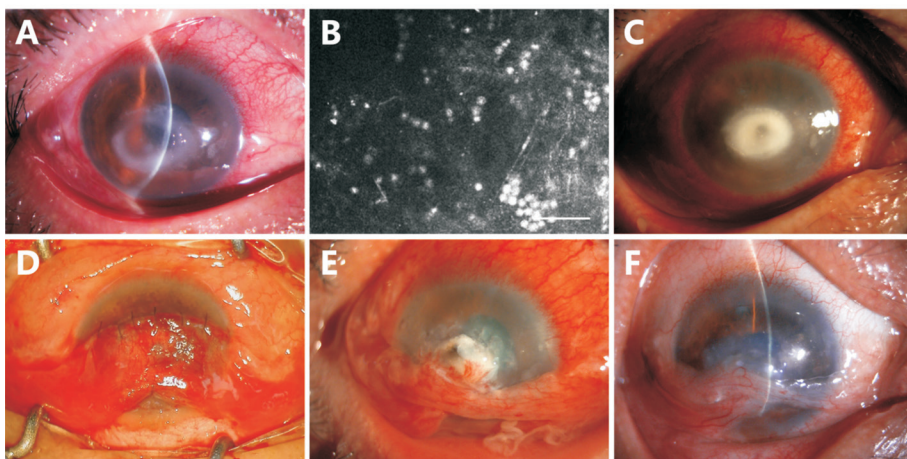


Figure 5 Case 4: corneal ring infiltration with corneal perforation Slit-lamp photographs and examinations of a 45-year-old farmer with central corneal ring infiltration (A). *Acanthamoeba* cysts were detected by IVCM (B). He was poorly responded to medications treatment (C) and CFCS was performed after 28d drugs treatment (D). A central corneal perforation occurred 15d later (E). Then, the amniotic membrane was applied to repair the perforation and performed CFCS again, and the ulcer healed and the cornea became stable with a leucoma and superficial conjunctiva at 10mo follow-up (F). Scale bar: 50 μ m. IVCM: *In vivo* confocal microscopy; CFCS: Conjunctival flap covering surgery.

Then, the amniotic membrane was applied to repair the perforation and performed CFCS again. At 10mo follow-up, the ulcer healed and the cornea became stable with a leucoma and superficial conjunctiva (Figure 5F). His corneal thickness was 575 μm and the depth of corneal opacity was 351 μm by AS-OCT. Due to corneal scarring, superficial conjunctiva and therapeutic corneal transplantation was not done, so vision did not improve, but the eyeball was saved, preserving a chance of regaining visual function.

DISCUSSION

As far as we known *Acanthamoeba* is the most common cause of protozoal infections among free-living amoeba, although AK is previously a rare disease worldwide, but the number of cases is now increasing year by year^[6]. Other study estimated that China has the lowest incidence of AK, with 0.7 cases per million per year in Beijing, north China^[13]. But there may be a geographical gap, with data lacking in central China.

This retrospective case series included 21 patients diagnosed with AK at a tertiary referral hospital in central China between April 2020 and March 2023. Our findings demonstrated that contact lens wearing (13 of 21, 61.9%) was the most common susceptibility factor, followed by trauma (5 of 21, 23.8%). 71.4% (15 of 21) of the patients both with radial keratoneuritis or crude salt-like granular dense infiltration clinical features, and these patients were associated with orthokeratology, which was considered as a practice to control myopia^[14]. This is slightly lower than the range of contact lens use in the peer literature for AK cases of 80% to 96%^[15]. Due to the increasing number of contact lens using in China's primary and middle school students, showing high association between contact lens wearing and AK in our country, similar to that in developed countries. The remaining 28.6% of patients (6 of 21) presented with corneal ring infiltration, which were mainly caused by corneal trauma (83.3%, 5 of 6). Our result was higher than case series from the UK and Australia^[16], but lower than that in Southern India^[17].

Primary medical institutions were unable to identify clinical characteristic patterns of early or late disease manifestations. The delay from symptom onset to initiation of anti-amoebic therapy ranged from 7 to 38d, with a mean of 19.3 \pm 9.1d. According to previous reports, herpes simplex keratitis (HSK) is the most common misdiagnosis for AK^[15], which is similar to our results. This emphasizes the importance of maintaining a high suspicion of AK among contact lens wearers and corneal trauma patients^[15]. Patients with keratitis who do not respond to appropriate treatment based on microbiological results should be reinvestigated. Nevertheless, four patients (19.1%) complained of eye pain mainly at night, which were lower compared with other study^[18]. the potential factors and timing for aggravation of AK. It is not difficult to summarize

the experience from our data that, from the onset of symptoms to delayed hospital presentation, misdiagnosis, and use of topical steroid for more than 2wk in AK patients, the condition is aggravated.

All patients started with a combination of anti-amoebic agents and oral voriconazole. Totally 71.4% patients were medically cured, of which 6 patients (28.6%) required CFCS to achieve disease control, which is lower than earlier studies^[19]. Three patients underwent a second optical keratoplasty, and all grafts were clear at the last follow-up. This difference can be explained by the delayed initiation of anti-amoebic therapy. There was a statistically significant correlation between the type and severity of the disease at the time of onset and the visual outcome. Indeed, a recent large case series reported that patients who underwent therapeutic keratoplasty had a poor prognosis, whereas patients who underwent optical keratoplasty had a better visual prognosis^[20]. When the drug treatment is not effective, we try not to do corneal transplantation immediately, CFCS may be a better choice. All of the patients completed their follow-up at the Wuhan Union Hospital, with a total of 20 of 21 (95.2%) patients had improved visual acuity after treatment. Corneal scarring and vascularization were the two most common complications of AK in our series, occurring in 85.7% and 28.6%, respectively. This condition is more common in patients with salt-like granular dense infiltration and ring infiltration.

The limitations of this study included lack of controls and small sample size. In addition, the data were collected from patient records, so the integrity of the data set depends on the quality of those records. This may have skewed the results, as the outcomes may represent a higher proportion of complicated patients who completed follow up at the Wuhan Union Hospital. Admittedly, our diagnosis of acanthamoeba infection based on clinical morphology and IVCN is limited by subjective awareness and operator dependence. In addition, we have not perfected the histopathology of transplant cases, and we will improve this aspect in future studies. Despite these limitations, this is a contemporary case series of consecutive AK cases at a referral hospital in central China, providing valuable clinical and epidemiologic data.

In central China, AK mainly occurred predominantly in contact lens wearers, mostly in students without severe ocular pain, with typical clinical features including radial keratoneuritis, crude salt-like granular dense infiltration, and corneal ring infiltration. Clinical feature radial keratoneuritis and crude salt-like granular dense infiltration are largely treatable with medications, whereas corneal ring infiltration requires prompt surgical intervention, and have a higher risk of corneal perforation, the two-step strategy CFCS combined with secondary DALK is effective for patients with high-risk AK.

ACKNOWLEDGEMENTS

Authors' Contributions: Conceptualization, Xie HT and Zhang MC; methodology, Yao TY, Jiang XY, and Wang JS; writing—original draft preparation, Wang JS and Zhao D; writing—review and editing, Xie HT and Zhang MC; supervision, Xie HT and Zhang MC; project administration, Zhang MC; funding acquisition, Xie HT and Zhang MC. All authors have read and agreed to the published version of the manuscript.

Data Availability Statement: The original contributions presented in the study are included in the article. Further inquiries can be directed to the corresponding author.

Foundations: Supported by National Natural Science Foundation of China (No.82171025; No.82070934); the Fundamental Research Funds for the Central Universities (HUST: 2019kfyXMBZ065); the Key Research and Development Program of Hubei Province (No.2021BCA146); the Clinical Research Foundation of Wuhan Union Hospital (No.2021xhlcyj03); the Hubei Province Health and Family Planning Scientific Research Project (No.WJ2023M035).

Conflicts of Interest: Wang JS, None; Zhao D, None; Yao TY, None; Jiang XY, None; Xie HT, None; Zhang MC, None.

REFERENCES

- 1 Varacalli G, Di Zazzo A, Mori T, Dohlman TH, Spelta S, Coassin M, Bonini S. Challenges in acanthamoeba keratitis: a Review. *J Clin Med* 2021;10(5):942.
- 2 Sagerfors S, Ejdermik-Lindblad B, Söderquist B. Infectious keratitis: isolated microbes and their antibiotic susceptibility pattern during 2004-2014 in Region Örebro County, Sweden. *Acta Ophthalmol* 2020;98(3):255-260.
- 3 Lam DS, Houang E, Fan DS, *et al.* Incidence and risk factors for microbial keratitis in Hong Kong: comparison with Europe and North America. *Eye (Lond)* 2002;16(5):608-618.
- 4 Scruggs BA, Quist TS, Zimmerman MB, *et al.* Risk factors, management, and outcomes of *Acanthamoeba* keratitis: a retrospective analysis of 110 cases. *Am J Ophthalmol Case Rep* 2022;25:101372.
- 5 de Lacerda AG, Lira M. *Acanthamoeba* keratitis: a review of biology, pathophysiology and epidemiology. *Ophthalmic Physiol Opt* 2021;41(1):116-135.
- 6 Zhang YH, Xu XZ, Wei ZY, *et al.* The global epidemiology and clinical diagnosis of *Acanthamoeba* keratitis. *J Infect Public Health* 2023;16(6):841-852.
- 7 Oliveira-Ferreira C, Leuzinger-Dias M, Tavares-Ferreira J, *et al.* Microbiological profile of infectious keratitis in a Portuguese tertiary centre. *J Ophthalmol* 2019;2019:6328058.
- 8 Fanselow N, Sirajuddin N, Yin XT, *et al.* *Acanthamoeba* keratitis, pathology, diagnosis and treatment. *Pathogens* 2021;10(3):323.
- 9 Yera H, Ok V, Lee Koy Kuet F, *et al.* PCR and culture for diagnosis of *Acanthamoeba* keratitis. *Br J Ophthalmol* 2021;105(9):1302-1306.
- 10 Goh JWY, Harrison R, Hau S, *et al.* Comparison of *in vivo* confocal microscopy, PCR and culture of corneal scrapes in the diagnosis of acanthamoeba keratitis. *Cornea* 2018;37(4):480-485.
- 11 Winchester K, Mathers WD, Sutphin JE, *et al.* Diagnosis of acanthamoeba keratitis *in vivo* with confocal microscopy. *Cornea* 1995;14(1):10-17.
- 12 Lee HJ, Alipour F, Cruzat A, *et al.* Utility of *in vivo* confocal microscopy in diagnosis of acanthamoeba keratitis: a comparison of patient outcomes. *Cornea* 2023;42(2):135-140.
- 13 Jiang C, Sun XG, Wang ZQ, *et al.* *Acanthamoeba* keratitis: clinical characteristics and management. *Ocul Surf* 2015;13(2):164-168.
- 14 Liu YM, Xie PY. The safety of orthokeratology—a systematic review. *Eye Contact Lens Sci Clin Pract* 2016;42(1):35-42.
- 15 Patel DV, Rayner S, McGhee CN. Resurgence of acanthamoeba keratitis in Auckland, New Zealand: a 7-year review of presentation and outcomes. *Clin Exp Ophthalmol* 2010;38(1):15-20.
- 16 Maycock NJ, Jayaswal R. Update on acanthamoeba keratitis: diagnosis, treatment, and outcomes. *Cornea* 2016;35(5):713-720.
- 17 Sharma S, Garg P, Rao GN. Patient characteristics, diagnosis, and treatment of non-contact lens related *Acanthamoeba* keratitis. *Br J Ophthalmol* 2000;84(10):1103-1108.
- 18 Bacon AS, Frazer DG, Dart JG, *et al.* A review of 72 consecutive cases of *Acanthamoeba* keratitis, 1984-1992. *Eye (Lond)* 1993;7(6):719-725.
- 19 Höllhumer R, Keay L, Watson SL. *Acanthamoeba* keratitis in Australia: demographics, associated factors, presentation and outcomes: a 15-year case review. *Eye (Lond)* 2020;34(4):725-732.
- 20 Robaei D, Carnt N, Minassian DC, *et al.* Therapeutic and optical keratoplasty in the management of *Acanthamoeba* keratitis: risk factors, outcomes, and summary of the literature. *Ophthalmology* 2015;122(1):17-24.