

Intravitreal bevacizumab versus bevacizumab and 1 mg triamcinolone acetonide in eyes with bilateral diabetic macular edema

Sever Ozkan¹, Horozoglu Fatih¹, Celik Erkan², Topcu Birol³

¹Department of Ophthalmology, Namik Kemal University School of Medicine, Namik Kemal University, Tekirdag 59000, Turkey

²Department of Ophthalmology, Sakarya Education and Research Hospital, Sakarya 54100, Turkey

³Department of Biostatistics, Namik Kemal University School of Medicine, Namik Kemal University, Tekirdag 59000, Turkey

Correspondence to: Ozkan Sever. Department of Ophthalmology, Namik Kemal University School of Medicine, Namik Kemal University, Tekirdag 59000, Turkey. sever_ozkan@hotmail.com

Received: 2019-04-13 Accepted: 2020-08-03

Abstract

• **AIM:** To Compare of intravitreal bevacizumab and intravitreal bevacizumab and triamcinolone acetonide in eyes with bilateral diabetic macular edema.

• **METHODS:** In this retrospective comparative-randomized study, 42 eyes of 21 diabetic patients with bilateral macular edema were evaluated. In one eye intravitreal injection of 1.25 mg bevacizumab (IVB group) was performed and in the fellow eye intravitreal injection of combined 1.25 mg bevacizumab and 1 mg triamcinolone acetonide (IVTA-IVB group) was performed. Main outcomes were the central macular thickness (CMT) measured with optical coherence tomography (OCT), ETDRS visual acuity (VA) and intraocular pressure (IOP).

• **RESULTS:** Mean follow-up time was 4.7±1.5mo. In the IVB and IVTA-IVB groups, mean CMT was 494.7±114.4 µm and 546.8±165.6 µm before injections; 430.4±133.2 µm and 363.7±105.3 µm at first month; 484.8±167.4 µm and 407.3±108.7 µm at 3rd month; 550.4±191.5 µm and 516.8±158 µm after 6mo respectively. Differences were significant at first and 3rd month ($P<0.05$). In the IVB and IVTA-IVB groups, mean ETDRS VA score was 57.1±13.5 and 48.9±13.9 before injections; 62.2±14 and 58.8±12.1 at first month; 59±13.7 and 59.3±13.6 at 3rd month; 55.6±14.9 and 55.5±8.7 after 6mo respectively. Differences were significant at first and 3rd and 6mo ($P<0.05$). There was no IOP difference. IVTA-IVB group gains best VA at 3rd month

after the first injection and maintains it for 6mo whereas IVB group gains best VA at first month and can be able to maintain for 3mo.

• **CONCLUSION:** Injection of 1 mg IVTA-IVB seems to be better than IVB alone in improving VA for 6mo without any steroid dependent complications.

• **KEYWORDS:** diabetic retinopathy; triamcinolone acetonide; bevacizumab

DOI:10.18240/ier.2020.03.09

Citation: Sever O, Horozoglu F, Celik E, Birol T. Intravitreal bevacizumab versus bevacizumab and 1 mg triamcinolone acetonide in eyes with bilateral diabetic macular edema. *Int Eye Res* 2020;1(3):183-189

INTRODUCTION

Diabetic macular edema (DME) is the most common cause of visual impairment in patients with diabetic retinopathy^[1]. Laser photocoagulation has been the standard-of-care treatment for DME for decades, based on the Early Treatment Diabetic Retinopathy Study (ETDRS) and other more recent clinical trials^[2-3]. Later it was reported that the improvement in visual acuity (VA) occurs in only about 17% of treated eyes and laser treatment causes many complications such as laser scars that can enlarge postoperatively, leading to decreased vision^[2-4]. Intravitreal triamcinolone (IVT) showed to have a beneficial effect on macular thickness and VA in eyes with DME, with a probable mechanism of increase in tight junction proteins, which diminish vessel leakage by a local vasoconstrictive effect and angiostatic properties through inhibition of vascular endothelial growth factor (VEGF). Corticosteroids block the arachidonic acid pathway via phospholipase A2 inhibition. This inhibits the synthesis of thromboxanes, leukotrienes, and prostaglandins, and prevents vasodilation and increased capillary permeability. Corticosteroids also stabilize lysozymes, reduce synthesis of inflammatory mediators and VEGF, inhibit cell proliferation, stabilize the BRB, enhance the density and activity of tight junctions in the retinal capillary endothelium, and improve retinal oxygenation^[5]. However, its effect is temporary and side effects such as cataract formation and intraocular pressure (IOP) elevation have been reported in a significant percentage

of cases^[6-8]. VEGF plays as an important factor in the breakdown of the blood-retinal barrier and increased vascular permeability in diabetic eyes and recent studies have revealed elevated VEGF levels in the vitreous of patients^[9-10]. There is an increasing trend for use of intravitreal bevacizumab (IVB) (a humanized full-length monoclonal antibody that inhibits all isoforms of VEGF) for DME^[11-13].

Various modalities of treatment are currently being tried in the management of DME such as supplemental laser, intravitreal steroids, anti-VEGF drugs and combination of these procedures. The aim of this study was to compare the effectiveness and safety of only IVB versus combination of IVB and IVT in eyes with bilateral DME.

SUBJECTS AND METHODS

Ethical Approval The study protocol adhered to the tenets of the Declaration of Helsinki and was approved by the local Institutional Review Board and all participants gave written informed consent before injections.

Patient Eligibility and Baseline Evaluation Twenty-one consecutive diabetic patients with bilateral DME, whose foveal thickness was more than 300 µm in both eyes were recruited in this study. All the patients were among those without any health insurance and could not afford repeated therapies and novel drugs. Exclusion criteria were: 1) vitreoretinal traction on spectral-domain optical coherence tomography (OCT); 2) history of glaucoma or ocular hypertension; 3) an ocular condition that, in the opinion of the investigator, might affect macular edema or alter VA during the course of the study (*e.g.* uveitis, retinal vein occlusion, epiretinal membrane, age-related macular degeneration, recently performed cataract surgery, macular laser *etc.*); 4) systemic corticosteroid therapy; 5) any condition that, in the opinion of the investigator, might preclude follow-up throughout the study period such as; high blood sugar levels and high blood pressure levels.

All patients received a comprehensive systemic and ophthalmologic examination including; blood HbA1c levels, systemic blood pressure levels, measurement of best-corrected visual acuity (BCVA) according to the standardized ETDRS refraction protocol using a retroilluminated Lighthouse for the Blind distance VA test chart (using modified ETDRS charts 1, 2, and R; Precision Vision IL), as well as applanation tonometry, undilated and dilated slit-lamp biomicroscopic examination, indirect fundus examination, and fluorescein angiography to detect and assess leakage around the fovea. Retinal thickness by OCT (Cirrus HD-OCT, Carl Zeiss Ophthalmic System Inc, Zeiss-Humphrey, Dublin, California, USA) were measured during the follow-up examinations. A macular thickness map was made from six radial scans that intersected at the fovea using the OCT retinal-mapping program (version 6.2). This program calculates mean thickness

in nine regions: the 1000 µm central area, and the four quadrants of the inner and outer rings. The diameters of the inner and outer rings were 1000 µm to 3000 µm and 3000 µm to 6000 µm, respectively. In this study, foveal thickness was defined as the value of a 1000 µm central area. No patients received macular grid laser during follow-up period because most of the patients had grid laser photocoagulation during former visits.

Intravitreal Injection Forty two eyes of 21 diabetic patients with bilateral DME were randomly assigned. In each patient, 1.25 mg of bevacizumab (Avastin; Genetech, Inc, South San Francisco, California, USA) was injected into the vitreous in one eye, and combination of 1.25 mg bevacizumab and 1 mg of triamcinolone acetonide (Kenacort; Bristol-Myers Squibb, Tokyo, Japan) was injected in the other eye. Injections to each eye was made separately at different times using different drape sets. Both drugs were prepared in different injectors and first we administered intravitreal triamcinolone and then we removed the injector but not the needle from the eye and second injection was applied thorough the same needle. All injections were performed using topical proparacaine drops under sterile conditions (eyelid speculum, povidone-iodine and draping). Before the injection was performed, the eyelids were scrubbed with 10% povidone-iodine, and 5% povidone-iodine drops were applied to the conjunctiva. The time between application of 5% povidone-iodine solution to the conjunctiva and administration of the intravitreal injection was 2 minutes. Povidone-iodine was applied to the conjunctiva directly over the intended injection site. Care was taken in all cases to insure that the needle did not touch the lids or lashes. Afterwards, 0.05 mL volume containing 1.25 mg of bevacizumab or 0.1 mL volume containing the combination of 1.25 mg of bevacizumab and 1 mg of triamcinolone acetonide was injected into the vitreous cavity using a sharp 27-gauge needle through the superotemporal quadrant at a distance of 3.5-4 mm from the limbus. Central retinal artery perfusion was confirmed with indirect ophthalmoscopy and right after the injections their intraocular pressure were measured with air tonometry (Canon Tx10, non-contact tonometry). IOP till 25 mmHg were accepted as normal. Patients were instructed to instill one drop of 0.5% moxifloxacin hydrochloride (Vigamox, Alcon Lab., Fort Worth, USA) into the injected eye 4 times daily for 1wk after the procedure.

Follow-up Examinations and Outcome Measures After the injections 1st day, 1st week, 1st month, 3rd month and 3 months intervals thereafter were the time points for examination. At these visits, patients' VA was determined after ETDRS refraction, and they underwent complete ophthalmic examination using the same procedures as at baseline. Main outcome measures were the changes in the ETDRS VA and

central macular thickness (CMT) measured with OCT, and IOP, and occurrence of complications.

Statistical Analysis One-Way ANOVA, independent sample *t* test, Mann-Whitney *U* test, paired sample *t* test and Wilcoxon tests were used for statistical analysis (SPSS for Windows, version 18.0, SPSS, Chicago, IL, USA). A *P* value of less than 0.05 was considered to be statistically significant.

RESULTS

Forty two eyes of 21 patients (11 females, 10 males) with bilateral DME were studied. The ages of patients ranged from 46-89y with a mean of 65.4±8.9y. The mean follow-up period was 4.7±1.5mo (range: 3-6mo, 6mo for 12 patients, 3mo for 9 patients). The duration of diabetes ranged from 20.5±9.77 (8-30)y and the mean level of HbA1c was 9.1±2.2 mg/dL. Fifteen patients had hypertension as accompanying systemic disease. Five eyes had proliferative diabetic retinopathy and 18 patients had a history of focal and/or panretinal photocoagulation treatment.

Before the administration of the drugs, CMT obtained by OCT was 494.7±114.4 μm in the IVB group, and 546.8±165.6 μm in the IVB + IVTA group, and there was no significant difference between them (*P*=0.243). Also, there was no significant difference in initial VAs (57.1±13.50 in IVB, 48.9±13.90 in IVTA+IVB, *P*=0.59) and IOPs (15.6±3.20 mm Hg in IVB, 15.8±3.10 mm Hg in IVTA+IVB, *P*=0.779) between two groups (Table 1).

Outcome Measures

Visual acuity At baseline, mean ETDRS scores were 57.1±13.5 and 48.9±13.90 in the IVB and IVTA+IVB groups, respectively. After the injections 1st day, 1st week, 1st month, 3rd month and 6th month mean ETDRS scores were 49.8±13.07, 54.7±12.7 and 57.5±12.6, 60.4±12.05 and 58.8±12.1, 62.2±14 and 59.3±13.60, 59±13.70 and 55.5±8.7, 55.6±14.9 in the IVTA+IVB and IVB groups, respectively. We observed that IVTA-IVB group gains best VA at 3rd month after the first injection and maintains it for 6mo; whereas, IVB group gains best VA at first month and can be able to maintain for 3mo.

Intragroup VA improvement in IVB alone group was statistically significant in 1st week (*P*<0.01) and 1st month (*P*<0.04). However, 3rd month (*P*<0.23) and 6th month (*P*<0.875) improvements were not statistically significant. Intragroup VA improvement in IVTA+IVB group was statistically significant in 1st week (*P*<0.01), 1st month (*P*<0.04), 3rd month (*P*<0.01) and 6th month (*P*<0.03). Between these two groups, there was a statistically significant difference of VA at the time of all visits (1st day, 1st week, 1st month, 3rd month and 6th month). VA changes are summarized in the Table 2, Figure 1.

Central macular thickness At baseline, mean CMT was 494.7±114.4 μm and 546.8±165.6 μm in the IVB and

Table 1 Pre-injection demographic features mean±SD

Pre-injection	IVTA+IVB	IVB	<i>P</i>
Visual acuity	48.9±13.90	57.1±13.50	0.23 ^a
Intraocular pressure (mm Hg)	15.8±3.10	15.6±3.20	0.92 ^a
Central macular thickness (μm)	546.8±165.6	494.7±114.4	0.12 ^a

IVTA: Intravitreal triamcinolone+bevacizumab; IVB: Intravitreal bevacizumab. ^aIndependent sample *t* test.

Table 2 Comparison of BCVA alterations for combined IVTA+IVB group and only IVB group

BCVA	IVTA+IVB letter gain	IVB letter gain	<i>P</i>
1 st day	+1.1 letter	-1.3 letter	0.012 ^a
1 st week	+4.8 letter	+2.1 letter	0.013 ^a
1 st month	+7.2 letter	+3.01 letter	0.045 ^b
3 th month	+5.8 letter	+0.9 letter	0.01 ^a
6 th month	+1.5 letter	-0.8 letter	0.03 ^a

IVTA: Intravitreal triamcinolone+bevacizumab; IVB: Intravitreal bevacizumab; BCVA: Best-corrected visual acuity. ^aMann Whitney *U* test *P*<0.05; ^bIndependent sample *t* test *P*<0.05.

Table 3 Comparison of CMT alterations for combined IVTA+IVB group and only IVB group

CMT, μm	IVTA + IVB mean differences	IVB mean differences	<i>P</i>
1 st week	-82.4	-24.2	0.04 ^a
1 st month	-94.3	-42.2	0.021 ^a
3 th month	-53.1	-4.1	0.027 ^a
6 th month	-2.3	+10.3	0.241 ^b

IVTA: Intravitreal triamcinolone+bevacizumab; IVB: Intravitreal bevacizumab; CMT: Central macular thickness. ^aMann Whitney *U* test *P*<0.05. ^bIndependent sample *t* test *P*<0.05.

IVTA+IVB groups, respectively (*P*=0.243) and 430.4±133.2 μm and 363.7±105.3 μm at first month, was 484.8±167.4 μm and 407.3±108.7 μm at 3rd month, was 550.4±191.5 μm and 516.8±158 μm after 6mo respectively. Comparison of differences between the two groups was significant at first 3mo (*P*<0.05). CMT changes are summarized in the Table 3 and Figure 1.

For the eyes treated with IVTA+IVB, intragroup statistically significant reduction in CMT, compared with baseline, was observed at 1st week (*P*<0.05), 1st month (*P*<0.05) and 3rd month (*P*<0.05) follow-up visits. However, 6th month CMT change was not statistically significant (*P*<0.556). For the eyes treated with IVB, intragroup statistically significant reduction in CMT, compared with baseline, was observed only at 1st week (*P*<0.031) and 1st month (*P*<0.034). However, 3rd and 6th month CMT changes were not statistically significant (*P*<0.366). We observed that IVTA-IVB group gains best VA at 3rd month after the first injection and maintains it for 6mo; whereas, IVB group gains best VA at first month and can be able to maintain for 3mo.

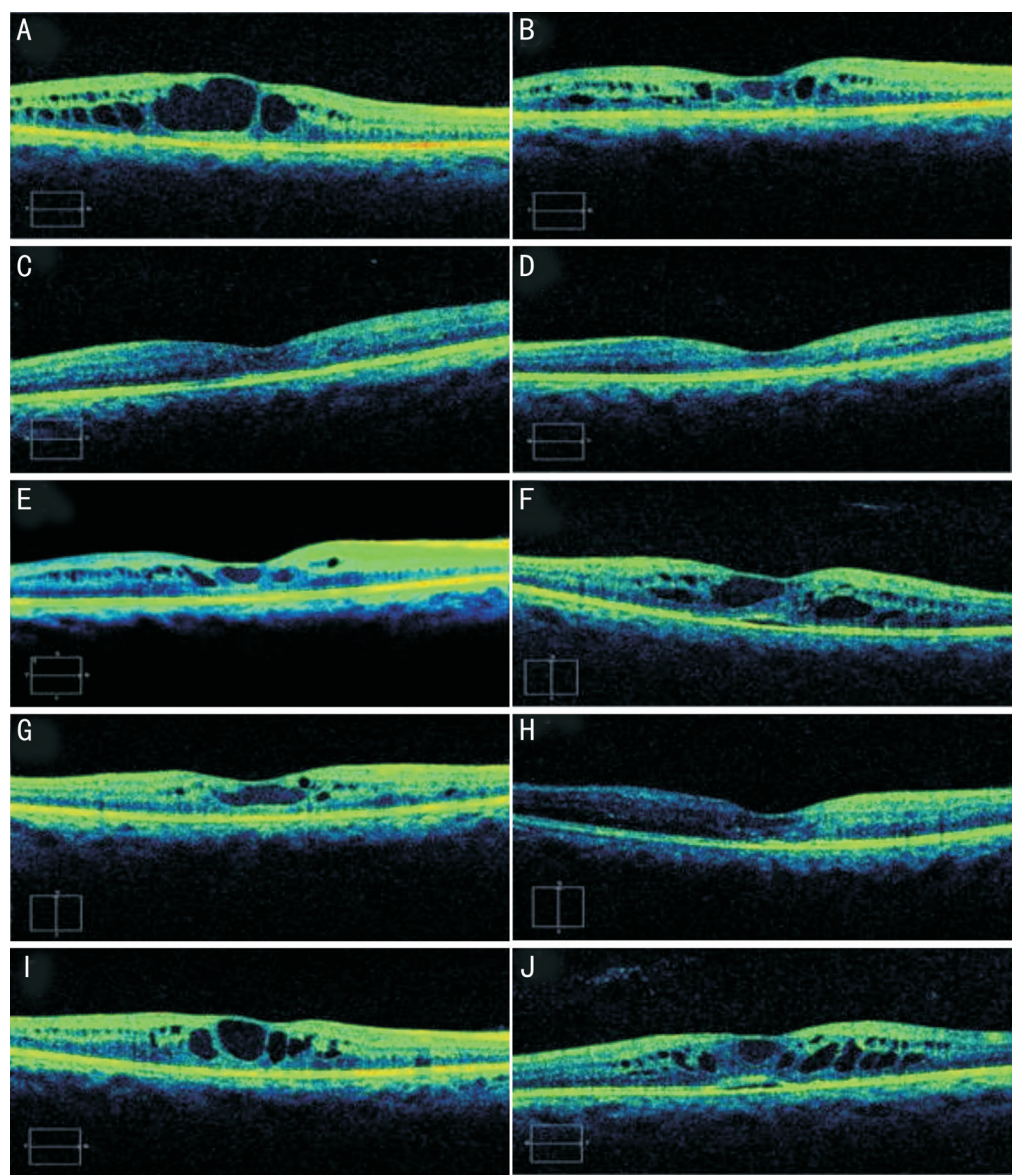


Figure 1 Pre-injection, post-injection 1st week, 1st, 3rd and 6th month macular optical coherence tomography changes for combined intravitreal bevacizumab and triamcinolone (A-E) and only bevacizumab (F-J) group.

Intraocular pressure At the initial examination, average baseline IOP was 15.6 ± 3.2 and 15.8 ± 3.1 mm Hg in the IVB and IVTA+IVB groups, respectively. There was no statistically significant difference between the two groups initially ($P=0.779$). There was no significant change in mean IOP compared with baseline at any of the study follow-up visits in either group ($P>0.05$; Table 4).

DISCUSSION

Although the molecular mechanisms of DME development are not completely understood, DME has been characterized by inflammation, including intravitreal induction of proinflammatory cytokine, intraretinal expression of proinflammatory caspases and mediators, and therefore, many clinical investigators have found that intravitreal injection of a corticosteroid of triamcinolone acetonide may reduce macular edema^[6,9]. And also, VEGF is a well-known potent angiogenic factor that is involved in the increased vascular

Table 4 Comparison of IOP alterations for combined IVTA+IVB group and only IVB group

IOP, mm Hg	IVTA+IVB	IVB	<i>P</i>
1 st day	15.8±4.50	14.8±2.70	0.05 ^a
1 st week	15.6±3.20	16.4±3.30	0.05 ^a
1 st month	15.5±3.00	16.3±2.60	0.05 ^a
3 th month	15.6±3.10	15.3±2.80	0.05 ^b
6 th month	16.2±2.80	15.8±2.80	0.05 ^a

IVTA: Intravitreal triamcinolone+bevacizumab; IVB: Intravitreal bevacizumab; IOP: Intraocular pressure. ^aMann Whitney *U* test $P<0.05$. ^bIndependent sample *t* test $P<0.05$.

permeability leading to macular edema and induces retinal neovascularization^[13]. Since recent studies have shown that VEGF plays a major role in the pathogenesis of diabetic retinopathy, studies with anti-VEGF therapy showed dramatic reductions of DME^[12,14-15].

Among recent treatments available for DME, intravitreal

injections of triamcinolone acetonide and of bevacizumab have been shown to be safe, effective, and visually and anatomically beneficial in most patients with DME^[2,14]. Nonetheless, the exact mechanisms of these treatments and reasons for response to the treatment still remain unknown. In this study, we compared the effectiveness and safety of IVB alone versus combination of IVB and IVT in eyes with bilateral DME.

We observed that IVTA-IVB group gains best VA at 3rd month after the first injection and maintains it for 6mo; whereas, IVB group gains best VA at first month and can be able to maintain for 3mo. After the injections intragroup VA improvement in IVB alone group was statistically significant in 1st week and 1st month. However, 3rd and 6th month improvements were not statistically significant. Intragroup VA improvement in IVTA+IVB group was statistically significant in 1st week, 1st, 3rd and 6th month. Between these two groups, there was a statistically significant difference of VA at the time of all visits (1st day, 1st week, 1st, 3rd and 6th month).

There are so many studies comparing treatment modalities with IVB and IVTA on DME reporting different results. Treatment with IVB has been reported to be associated with favorable anatomic effects in patients with DME; the BOLT study reported a mean CMT reduction at 1y of 130 μ m and improvement in VA, which is similar to a recent report from the Pan-American Collaborative Retina Study Group showing a dramatic decrease of DME^[10,14]. In the study by Chakrabarti *et al*^[16], the response to therapy with bevacizumab showed superiority compared with TA for DME. In a study designed by and Marey *et al*^[17], comparing the efficacy of IVB alone and IVB-IVTA combination for primary treatment of DME, they concluded that IVB is an effective drug for DME, and has a long lasting effect compared with IVTA and when compared with combined IVTA/IVB; and also they reported that, adding IVT does not affect the outcome measures except for elevating the IOP in treated patients in the early post-injection period. However, these studies differed from that of Shimura *et al*^[18], Paccola *et al*^[19], Isaac *et al*^[20] and Lim *et al*^[21], who demonstrated that IVTA was more efficient in reducing DME relative to bevacizumab. And in the other study by Rensch *et al*^[22], IVTA and IVB did not differ markedly on VA and CMT. Soheilian *et al*^[23] found that combination therapy with IVB and IVTA demonstrated no additional benefit in patients with DME when compared with IVB alone. Which treatment is more effective remains controversial.

In a meta-analysis, including 6 studies comparing IVT versus IVB alone or IVB combined with IVT, they reported that the IVT group had a statistically significant improvement in vision over the IVB group, and this difference persisted to 3mo^[24]. However, reduction in CMT was not significant during the earlier follow-up period (1 and 3mo). At later visit (6mo), eyes that received IVT had a significant decrease in CMT while no

significant improvement in VA was observed. With regards to IVT versus IVB combined with IVT, due to the inadequate data of VA, the meta-analysis could not be assessed but there were no significant differences in CMT at 1mo and 3mo. The results of this study showed a favorable response to IVT compared with IVB in improvement of VA at 1 and 3mo^[24]. This meta-analysis and other previous studies pointed out that there was no absolute correlation between anatomical change (CMT) and functional change (VA). Some studies indicated that not only CMT, but age, hemoglobin A1c, and severity of leakage in the center and inner subfields were responsible for change in VA^[25-26]. In another study managed by Kamoi *et al*^[27], they concluded the varying degree of macular ischemia may explain why some patients do not show a marked improvement in vision despite a regression of CMT.

In our study, the IVB+IVTA group demonstrated better improvements of VA and CMT, compared with IVB alone group. These results may be explained by the edema formation hypothesized by two theories: 1) increased permeability of vessels and 2) increased water flux from vascular to the tissue compartment^[28]. VEGF is well known to increase vascular permeability; however, no report is available indicating that VEGF affects water flux through the vascular wall^[29]. In contrast, TA reduces the expression of VEGF and thereby prevents the accumulation of fluid in the extracellular space^[30-31]. In addition, DME is related with not only VEGF, but also IL-6, ICAM-1 and other cytokines^[32-33]. TA affects a number of different cytokine including VEGF, thus it may be necessary to reduce more than one cytokine to make an effective reduction in DME^[34]. From these aspects, TA is a multipotent drug, and therefore may have more advantages for regression of DME when compared with bevacizumab, which only reduces the amount of circulating free VEGF in the eye^[6,18].

As in the previous clinical data, intravitreal application of bevacizumab or bevacizumab combined with TA are both tolerated well in most of patients^[35-36]. Among the complications of IVTA, IOP elevation is the most common^[37-40]. Oh *et al*^[41] reported that 5 of 40 eyes developed temporary IOP elevation after IVTA injection and required temporary treatment. Gillies *et al*^[42] reported that over half of the eyes receiving IVTA injections for DME required cataract surgery within 3y. Chan *et al*^[43] reported that, even if the ocular hypertensive effects were similar between the injection types, the cumulative effects of the intraocular steroids would lead to increased cataractogenesis, and each injection exposes the eye to the small but serious risk of infective endophthalmitis. Retrospective reports indicate a per-injection endophthalmitis risk between 0 and 0.87% for IVTA injection and 0.019% to 0.16% for IVB injection^[44-47]. Neither severe complications such as infectious endophthalmitis/retinal detachment nor IOP

elevation were observed in the present study. There was no significant change in mean IOP compared with baseline at any of the study follow-up visits in either group in our study. Our results of IOP may be explained by the use of a lower dose of TA. When compared to DRCR, net protocol, in which cataract formation was 23% prior to the 2y visit, we didn't meet with any significant cataracts after single dose injection^[48].

The present study has some limitations because of the retrospective nature of the work, limited patient number. There may be an interaction of bevacizumab and triamcinolone agents in combination group.

In conclusion, our results suggest that injection of combined IVTA-IVB seems to have better results than IVB alone. We decided that the use of a lower dose of TA combined with bevacizumab resulted in almost no IOP and cataract-like complications. Among patients who did not have any health insurance and could not effort repeated therapies and novel drugs, receiving a single combined treatment may still be beneficial up to 3-6mo. Additional prospective and larger studies are needed to further investigate optimal interventions.

ACKNOWLEDGEMENTS

Conflicts of Interest: Sever O, None; Horozoglu F, None; Celik E, None; Birol T, None.

Peer Review File: Available at: http://ier.ijo.cn/gjykie/ch/reader/download_attache_file.aspx?seq_id=20210325153011001&flag=1&journal_id=gjykie&year_id=2020&issue=3

REFERENCES

- Simunovic MP, Hunyor AP, Ho IV. Vitrectomy for diabetic macular edema: a systematic review and meta-analysis. *Can J Ophthalmol* 2014;49(2):188-195.
- Arevalo JF. Diabetic macular edema: current management 2013. *World J Diabetes* 2013;4(6):231-233.
- Diabetic Retinopathy Clinical Research Network. A randomized trial comparing intravitreal triamcinolone acetonide and focal/grid photocoagulation for diabetic macular edema. *Ophthalmology* 2008;115(9):1447-1450.e10.
- Googe J, Brucker AJ, Bressler NM, Qin HJ, Aiello LP, Antoszyk A, Beck RW, Bressler SB, Ferris FL 3rd, Glassman AR, Marcus D, Stockdale CR. Diabetic Retinopathy Clinical Research Network. Randomized trial evaluating short-term effects of intravitreal ranibizumab or triamcinolone acetonide on macular edema after focal/grid laser for diabetic macular edema in eyes also receiving panretinal photocoagulation. *Retina* 2011;31(6):1009-1027.
- Stewart MW. Corticosteroid use for diabetic macular edema: old fad or new trend? *Curr Diab Rep* 2012;12(4):364-375.
- Shimura M, Yasuda K, Nakazawa T, Hirano Y, Sakamoto T, Ogura Y, Shiono T. Visual outcome after intravitreal triamcinolone acetonide depends on optical coherence tomographic patterns in patients with diffuse diabetic macular edema. *Retina* 2011;31(4):748-754.

- Sampat KM, Garg SJ. Complications of intravitreal injections. *Curr Opin Ophthalmol* 2010;21(3):178-183.
- Šarić B, Šarić VB, Motušić R, Predović J. Is the effect of intravitreal triamcinolone acetonide on diabetic macular edema dose-dependent? *Eur J Ophthalmol* 2014;24(2):221-227.
- Zhou JZ, Wang SH, Xia XB. Role of intravitreal inflammatory cytokines and angiogenic factors in proliferative diabetic retinopathy. *Curr Eye Res* 2012;37(5):416-420.
- Funk M, Schmidinger G, Maar N, Bolz M, Benesch T, Zlabinger GJ, Schmidt-Erfurth UM. Angiogenic and inflammatory markers in the intraocular fluid of eyes with diabetic macular edema and influence of therapy with bevacizumab. *Retina* 2010;30(9):1412-1419.
- Arevalo JF, Fromow-Guerra J, Quiroz-Mercado H, Sanchez JG, Wu L, Maia M, Berrocal MH, Solis-Vivanco A, Farah ME; Pan-American Collaborative Retina Study Group. Primary intravitreal bevacizumab (avastin) for diabetic macular edema results from the Pan-american collaborative retina study group at 6-month follow-up. *Ophthalmology* 2007;114(4):743-750.
- Roh MI, Byeon SH, Kwon OW. Repeated intravitreal injection of bevacizumab for clinically significant diabetic macular edema. *Retina* 2008;28(9):1314-1318.
- Welch DE, Elmariah H, Peden MC, Adams SG, Ratnakaram R, Kaushal S. Short-term response of macular oedema to intravitreal bevacizumab. *Br J Ophthalmol* 2009;93(8):1033-1036.
- Sohn HJ, Han DH, Kim IT, Oh IK, Kim KH, Lee DY, Nam DH. Changes in aqueous concentrations of various cytokines after intravitreal triamcinolone versus bevacizumab for diabetic macular edema. *Am J Ophthalmol* 2011;152(4):686-694.
- Michaelides M, Kaines A, Hamilton RD, Fraser-Bell S, Rajendram R, Quhill F, Boos CJ, Xing W, Egan C, Peto T, Bunce C, Leslie RD, Hykin PG. A prospective randomized trial of intravitreal bevacizumab or laser therapy in the management of diabetic macular edema (BOLT study) 12-month data: report 2. *Ophthalmology* 2010;117(6):1078-1086.e2.
- Chakrabarti M, John SR, Chakrabarti A, Stephen VT. Intravitreal monotherapy with bevacizumab (IVB) and triamcinolone acetonide (IVTA) versus combination therapy (IVB and IVTA) for recalcitrant diabetic macular edema. *Kerala J Ophthalmol* 2009;21:139-148.
- Marey HM, Ellakwa AF. Intravitreal bevacizumab alone or combined with triamcinolone acetonide as the primary treatment for diabetic macular edema. *Clin Ophthalmol* 2011;5:1011-1016.
- Shimura M, Nakazawa T, Yasuda K, Shiono T, Iida T, Sakamoto T, Nishida K. Comparative therapy evaluation of intravitreal bevacizumab and triamcinolone acetonide on persistent diffuse diabetic macular edema. *Am J Ophthalmol* 2008;145(5):854-861.
- Paccola L, Costa RA, Folgosa MS, Barbosa JC, Scott IU, Jorge R. Intravitreal triamcinolone versus bevacizumab for treatment of refractory diabetic macular oedema (IBEME study). *Br J Ophthalmol* 2008;92(1):76-80.
- Isaac DL, Abud MB, Frantz KA, Rassi AR, Avila M. Comparing intravitreal triamcinolone acetonide and bevacizumab injections for the treatment of diabetic macular oedema: a randomized double-blind study. *Acta Ophthalmol* 2012;90(1):56-60.

- 21 Lim JW, Lee HK, Shin MC. Comparison of intravitreal bevacizumab alone or combined with triamcinolone versus triamcinolone in diabetic macular edema: a randomized clinical trial. *Ophthalmologica* 2012;227(2):100-106.
- 22 Rensch F, Spandau UH, Wickenhäuser A, Jonas JB. Diffuse diabetic macular oedema treated with intravitreal bevacizumab or triamcinolone acetate. *Acta Ophthalmol* 2010;88(2):e36-e37.
- 23 Soheilian M, Ramezani A, Obudi A, Bijanzadeh B, Salehipour M, Yaseri M, Ahmadi H, Dehghan MH, Azarmina M, Moradian S, Peyman GA. Randomized trial of intravitreal bevacizumab alone or combined with triamcinolone versus macular photocoagulation in diabetic macular edema. *Ophthalmology* 2009;116(6):1142-1150.
- 24 Zhang XL, Chen J, Zhang RJ, Wang WJ, Zhou Q, Qin XY. Intravitreal triamcinolone versus intravitreal bevacizumab for diabetic macular edema: a meta-analysis. *Int J Ophthalmol* 2013;6(4):546-552.
- 25 Karth PA, Chang AN, Wiostko W. Paired responses to intravitreal bevacizumab in diabetic macular edema: predictors of response in the fellow eye. *Graefes Arch Clin Exp Ophthalmol* 2014;252(2):207-211.
- 26 Diabetic Retinopathy Clinical Research Network. Browning DJ, Glassman AR, Aiello LP, Beck RW, Brown DM, Fong DS, Bressler NM, Danis RP, Kinyoun JL, Nguyen QD, Bhavsar AR, Gottlieb J, et al. Relationship between optical coherence tomography-measured central retinal thickness and visual acuity in diabetic macular edema. *Ophthalmology* 2007;114(3):525-536.
- 27 Kamoi K, Takeda K, Hashimoto K, Tanaka R, Okuyama S. Identifying risk factors for clinically significant diabetic macula edema in patients with type 2 diabetes mellitus. *Curr Diabetes Rev* 2013;9(3):209-217.
- 28 Vadlapatla RK, Vadlapudi AD, Mitra AK. Hypoxia-inducible factor-1 (HIF-1): a potential target for intervention in ocular neovascular diseases. *Curr Drug Targets* 2013;14(8):919-935.
- 29 Boyer DS, Hopkins JJ, Sorof J, Ehrlich JS. Anti-vascular endothelial growth factor therapy for diabetic macular edema. *Ther Adv Endocrinol Metab* 2013;4(6):151-169.
- 30 Kakkassery V, Winterhalter S, Joussen AM. Anti-VEGF inhibitors and their role in the treatment of diabetic macular oedema. *Klin Monbl Augenheilkd* 2010;227(9):701-711.
- 31 Zhang XY, Bao SS, Lai D, Rapkins RW, Gillies MC. Intravitreal triamcinolone acetate inhibits breakdown of the blood-retinal barrier through differential regulation of VEGF-a and its receptors in early diabetic rat retinas. *Diabetes* 2008;57(4):1026-1033.
- 32 Chu LQ, Wang BS, Xu B, Dong N. Aqueous cytokines as predictors of macular edema in non-diabetic patients following uncomplicated phacoemulsification cataract surgery. *Mol Vis* 2013;19:2418-2425.
- 33 Sonoda S, Sakamoto T, Yamashita T, Shirasawa M, Otsuka H, Sonoda Y. Retinal morphologic changes and concentrations of cytokines in eyes with diabetic macular edema. *Retina* 2014;34(4):741-748.
- 34 Lee WJ, Cho HY. Possible short-term changes of aqueous inflammatory cytokines after intravitreal bevacizumab for diabetic macular edema. *Am J Ophthalmol* 2012;153(2):387-388; author reply 388.
- 35 Vasconcelos-Santos DV, Nehemy PG, Schachat AP, Nehemy MB. Secondary ocular hypertension after intravitreal injection of 4 Mg of triamcinolone acetate: incidence and risk factors. *Retina* 2008;28(4):573-580.
- 36 Wang HY, Li X, Wang YS, Zhang ZF, Li MH, Su XN, Zhu JT. Intravitreal injection of bevacizumab alone or with triamcinolone acetate for treatment of macular edema caused by central retinal vein occlusion. *Int J Ophthalmol* 2011;4(1):89-94.
- 37 Jain S, Thompson JR, Foot B, Tatham A, Eke T. Severe intraocular pressure rise following intravitreal triamcinolone: a national survey to estimate incidence and describe case profiles. *Eye (Lond)* 2014;28(4):399-401.
- 38 Mahar PS, Memon AS. Frequency and management of raised intraocular pressure following intravitreal triamcinolone acetate. *J Coll Physicians Surg Pak* 2012;22(11):699-702.
- 39 Qi HP, Bi S, Wei SQ, Cui H, Zhao JB. Intravitreal versus subtenon triamcinolone acetate injection for diabetic macular edema: a systematic review and meta-analysis. *Curr Eye Res* 2012;37(12):1136-1147.
- 40 Jin ZY, Zhu D, Tao Y, Wong IY, Jonas JB. Meta-analysis of the effect of intravitreal bevacizumab versus intravitreal triamcinolone acetate in central vein occlusion. *J Ocul Pharmacol Ther* 2013;29(9):826-831.
- 41 Oh SB, Moon JW, Kim HC. Comparison of effects of intravitreal triamcinolone and bevacizumab in the treatment of diabetic macular edema. *J Korean Ophthalmol Soc* 2009;50:1190-1196.
- 42 Gillies MC, Islam FM, Larsson J, Pasadhika S, Gaston C, Zhu MD, Wong TY. Triamcinolone-induced cataract in eyes with diabetic macular oedema: 3-year prospective data from a randomized clinical trial. *Clin Exp Ophthalmol* 2010;38(6):605-612.
- 43 Chan CK, Mohamed S, Shanmugam MP, Tsang CW, Lai TY, Lam DS. Decreasing efficacy of repeated intravitreal triamcinolone injections in diabetic macular oedema. *Br J Ophthalmol* 2006;90(9):1137-1141.
- 44 Wu L, Martínez-Castellanos MA, Quiroz-Mercado H, Arevalo JF, Berrocal MH, Farah ME, Maia M, Roca JA, Rodriguez FJ, Pan American Collaborative Retina Group (PACORES). Twelve-month safety of intravitreal injections of bevacizumab (Avastin): results of the Pan-American Collaborative Retina Study Group (PACORES). *Graefes Arch Clin Exp Ophthalmol* 2008;246(1):81-87.
- 45 Fintak DR, Shah GK, Blinder KJ, Regillo CD, Pollack J, Heier JS, Hollands H, Sharma S. Incidence of endophthalmitis related to intravitreal injection of bevacizumab and ranibizumab. *Retina* 2008;28(10):1395-1399.
- 46 Mason JO III, White MF, Feist RM, Thomley ML, Albert MA, Persaud TO, Yunker JJ, Vail RS. Incidence of acute onset endophthalmitis following intravitreal bevacizumab (avastin) injection. *Retina* 2008;28(4):564-567.
- 47 Diago T, McCannel CA, Bakri SJ, Pulido JS, Edwards AO, Pach JM. Infectious endophthalmitis after intravitreal injection of antiangiogenic agents. *Retina* 2009;29(5):601-605.
- 48 Beck RW, Edwards AR, Aiello LP, Bressler NM, Ferris F, Glassman AR, Hartnett E, Ip MS, Kim JE, Kollman C. Three-year follow-up of a randomized trial comparing focal/grid photocoagulation and intravitreal triamcinolone for diabetic macular edema. Diabetic Retinopathy Clinical Research Network (DRCR.net). *Arch Ophthalmol* 2009;127(3):245-251.