

Comparison of polymethylmethacrylate versus hydrophobic acrylic lenses for primary intraocular lens implantation in pediatric cataract surgery

Gamze Uçan Gündüz, Ahmet Tuncer Özmen, Berna Akova Budak

Department of Ophthalmology, Uludağ University Faculty of Medicine, Bursa 16059, Turkey

Correspondence to: Gamze Uçan Gündüz. Department of Ophthalmology, Uludağ University Faculty of Medicine, Bursa 16059, Turkey. gamzeucan@gmail.com

Received: 2018-04-13 Accepted: 2020-06-03

DOI:10.18240/ier.2020.03.05

Citation: Uçan Gündüz G, Özmen AT, Akova Budak B. Comparison of polymethylmethacrylate versus hydrophobic acrylic lenses for primary intraocular lens implantation in pediatric cataract surgery. *Int Eye Res* 2020;1(3):160-165

Abstract

• **AIM:** To compare the visual results and postoperative complications of polymethylmethacrylate (PMMA) and hydrophobic acrylic intraocular lenses (IOLs) in children who underwent cataract extraction with primary IOL implantation.

• **METHODS:** This retrospective study included 117 eyes of 63 children with bilateral pediatric cataract undergoing cataract surgery and primary IOL implantation. The patients were divided into two groups, Group I included 58 eyes of 30 patients with PMMA IOLs; Group II included 59 eyes of 33 patients with hydrophobic acrylic IOLs. The clinical features, refraction errors, best corrected visual acuity (BCVA) and surgical complications were compared between two groups.

• **RESULTS:** The mean age at the time of surgery was 5.8 (2-12)y and mean follow up period was 40.5 (6-196)mo. Postoperatively, BCVA was ≥ 0.5 in 80 eyes (68.4%) and this was comparable in two groups. Visual axis opacification was seen in 28 eyes (48.3%) in Group I and 16 eyes (27.1%) in Group II and this difference was statistically significant ($P=0.018$). Postoperative IOL dislocation and posterior synechia formation were also noted. When all postoperative complications were considered, there were significantly less complications in the acrylic IOL group than PMMA IOL group ($P=0.020$).

• **CONCLUSION:** Pediatric cataract surgery with primary IOL implantation is a safe procedure. Hydrophobic acrylic IOLs may lead to less postoperative complications compared to PMMA IOLs.

• **KEYWORDS:** hydrophobic acrylic intraocular lens; pediatric cataract; polymethylmethacrylate intraocular lens; primary intraocular lens implantation

INTRODUCTION

Pediatric cataract is the most common cause of treatable childhood blindness and its management still remains a challenge. Increased intraoperative and postoperative complications, changing refractive state of the growing eye and the risk of irreversible amblyopia affect the visual outcome in children with congenital or juvenile cataracts. The timing of surgery, and choice of the type and calculation of the power of the intraocular lens (IOL) are current discussions in pediatric cataract surgery^[1-3].

Due to the fact that an IOL can provide a full time correction with optics that simulate those of crystalline lens, IOL implantation during the cataract surgery is becoming an increasingly accepted procedure in young children and infants^[4]. The ability to implant the IOL through a small wound, minimizing posterior capsule opacification (PCO) and long-term IOL stability have to be considered during IOL selection. Polymethylmethacrylate (PMMA) IOLs required a relatively large incision for implantation whereas foldable acrylic IOLs could be implanted through a smaller incision.

Also it is essential to select the best IOL power for a growing eye, due to the risk of large myopic shift. In order to minimize the need to exchange IOL later in life, it has been advised to undercorrect children with IOLs so that they can grow into emmetropia or mild myopia in adult life^[5].

In this study, we compared postoperative complications and visual outcomes of primary IOL implantation of foldable hydrophobic acrylic and rigid PMMA IOLs in pediatric eyes.

SUBJECTS AND METHODS

Ethical Approval The notes of all children, who underwent lens aspiration and primary IOL implantation at Department of Ophthalmology in Uludağ University, Bursa, Turkey between 1994 and 2014 were reviewed retrospectively. This study was

approved by the Ethics Committee of Uludağ University and conformed to the tenets of the Helsinki Declaration. Inclusion criteria were between the ages of 2-12y at the time of surgery, presence of bilateral congenital or juvenile cataracts, and at least six months of follow up after surgery. Children with traumatic cataract, microphthalmia, microcornea, glaucoma, uveitis, posterior lenticonus and retinal lesions were excluded. The patients were divided into two groups, Group I included 58 eyes of 30 patients with one-piece PMMA IOLs (Microplex, Dr. Schmidt, Germany) and Group II included 59 eyes of 33 patients with three-pieces foldable hydrophobic acrylic IOLs (Acrysof, Alcon Laboratories, Fort Worth, TX, USA). PMMA IOL has an optic diameter of 5.5 mm and overall length of 12.5 mm whereas acrylic IOL has an optic diameter of 6 mm and overall length of 13 mm. Only one eye of 2 children in Group I and only one eye of 7 children in Group II were included in the study, because the other eyes had been operated by different surgeons.

Preoperative Assessment All patients underwent a detailed preoperative evaluation including best corrected visual acuity (BCVA), biomicroscopy, intraocular pressure measurement and fundoscopy. The visual acuity was determined using Snellen's visual acuity charts, E charts or Teller acuity cards according to the patients' age and cooperation. The Snellen fractions were converted to decimals. Coexisting systemic disease and the presence of strabismus and nystagmus were noted.

Intraocular lens power was calculated using the SRK-II formula whenever the preoperative keratometry was possible. When keratometry was not available in uncooperated and younger patients IOL power was calculated by Dahan guidelines^[6] according to the axial length. The IOL power was selected to achieve postoperative hypermetropia in patients less than 5 years old. It was targeted +5 diopter between 2-3 years old and +3 diopter between 4-5 years old at the time of cataract surgery. In children older than 5y, IOL power was adjusted to ensure postoperative emmetropia.

Surgical Technique Preoperatively pupils were dilated with tropicamide 0.5%, cyclopentolate 1%, phenylephrine 2.5% eye drops. All operations were performed under general anesthesia by a single surgeon (ATÖ). Under all aseptic precautions, an anterior segment maintainer was inserted at the inferior temporal quadrant of the cornea. A 5 mm anterior capsular continuous curvilinear capsulorrhexis was completed with a 26 G needle cystitome or microcoaxial rhexis forceps. After hydrodissection manual aspiration or the aspiration mode of vitrector was used to remove cortical and nuclear lens materials. In children aged less than 6 years, a posterior continuous curvilinear capsulorrhexis (PCCC) at least 4 mm, and anterior vitrectomy (AV) were performed. IOL was implanted into the eye through a scleral tunnel in Group I, and clear

corneal incision in Group II. Corneal incisions were closed by hydration or 10.0 vicryl sutures if it was not sufficient. Scleral tunnels were sutured by 10.0 nylon sutures.

Intraoperatively all patients received 1 mg/kg systemic corticosteroids and at the end of the surgery a subconjunctival injection of gentamicin sulphate 0.5 mL (20 mg) and dexamethasone 0.5 mL (2 mg) was given. The postoperative treatment protocol included a combination of antibiotic and steroid ointment four times daily, which continued for a month. All patients were examined on the first postoperative day and subsequently at first week, first and sixth months. At each visit, the BCVA and biomicroscope examination was performed. The presence of visual axis opacification (VAO), PCO, IOL dislocation and signs of anterior chamber inflammation were noted. At the postoperative sixth month and the last visit, BCVA and refraction errors calculated as spherical equivalents were recorded.

In statistical analysis, Fischer exact or Chi-square tests were used for comparing frequency values, and *t*-test was used for comparing mean values between the study groups. $P < 0.05$ was considered to be statistically significant.

RESULTS

A total of 117 eyes of 63 patients (39 boys and 24 girls), aged between 2-12y, were included in this study. All cases had bilateral congenital or juvenile cataracts. Patients were divided into two groups considering the IOL types implanted into their eyes; group I consisted of 58 eyes of 30 patients with PMMA IOLs, group II consisted of 59 eyes of 33 patients with hydrophobic acrylic IOLs. The two groups were comparable in terms of age at the time of surgery. All patients were followed for at least 6mo and the mean follow up time was 40.5mo. The mean follow up time was statistically longer in Group I (59.8mo) than in Group II (21.5mo; $P = 0.008$). Table 1 shows demographic and clinical data of the study groups.

The mean preoperative BCVA measured by Snellen's charts was 0.15 ± 0.14 ranging from fixing and following light to 0.2. BCVA was measured < 0.1 in 68 eyes (58%) preoperatively. At the postoperative sixth month, BCVA was > 0.1 in 108 eyes (92.3%) and > 0.5 (68.4%) in 80 eyes. Preoperative and postoperative mean BCVA values were not significantly different between two groups. The improvement of BCVA was statistically significant in both groups. Figure 1 shows preoperative and postoperative BCVA values of two groups.

Posterior continuous curvilinear capsulorrhexis and AV were performed in 64 of 117 eyes (54.7%) during the surgery. Posterior capsule (PC) was intact in the rest of the eyes. The mean age of the patients underwent PCCC and AV was 4.3y and who did not was 7.6y, this difference was statistically significant ($P < 0.001$). Table 2 shows PCCC and AV rates of two groups. No intraoperative complications were observed.

Table 1 Demographic and clinical data

Patients	Group I (PMMA, n=30)	Group II (Acrylic, n=33)	P
Male/Female	19/11	20/13	0.824
Mean age at surgery (y)	5.5±2.9	6.1±3.4	0.454
Axial length (mm)	21.49±1.98	21.38±1.87	0.736
Strabismus	11	9	0.380
Nystagmus	5	2	0.243
Coexisting systemic diseases ^a	6	5	0.613
Positive family history	4	9	0.172
Cataract type			0.242
Lamellar	27	23	
Nuclear	16	13	
Posterior subcapsular	4	13	
Anterior polar	6	5	
Mature	5	5	

PMMA: Polymethylmethacrylate. ^aCoexisting systemic diseases: in group I, 3 patients had heart valve diseases, 3 patients had diabetes and in group II, 2 patients had heart valve disease, one patient had renal agenesis, 1 patient had galaktosemia, 1 patient had juvenile diabetes.

Table 2 PCCC and AV rates of two groups

	Group I (PMMA, n=58)	Group II (Acrylic, n=59)	Total (n=117)	n (%)
Status of posterior capsule				
PCCC+AV	31 (53.4)	33 (55.9)	64 (54.7)	
Intact posterior capsule	27 (46.6)	26 (44.1)	53 (45.3)	

PMMA: Polymethylmethacrylate; PCCC: Posterior continuous curvilinear capsulorhexis; AV: Anterior vitrectomy. *P*=0.787.

Table 3 The postoperative complication incidences (%) of two groups

Postoperative complications	Group I (PMMA, n=58)	Group II (Acrylic, n=59)	Total (n=117)	P	n (%)
VAO	28 (48.3)	16 (27.1)	44 (37.6)	0.018	
IOL dislocation	2 (3.4)	3 (5.1)	5 (4.3)	1.00	
Posterior synechiae	7 (12.1)	0	7 (6.0)	0.006	

VAO: Visual axis opacification; IOL: Intraocular lens.

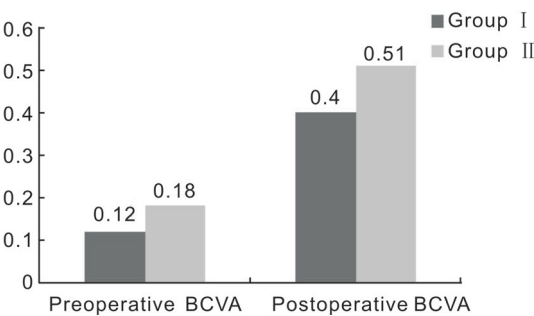


Figure 1 Preoperative and postoperative BCVA measured by Snellen's charts of two groups.

During the mean follow up time (40.5mo), VAO was seen in 44 (37.6%) of 117 eyes. The number of eyes developing VAO was 28 (48.3%) in Group I and 16 (27.1%) in Group II. Due to these results the incidence of VAO was significantly less with acrylic lenses (*P*=0.018). In both groups, a total of 64 eyes underwent PCCC and AV, and 11 of them (17%) developed VAO. Besides that PC was intact in 53 eyes, and 33 of them (62%) developed PCO. As a result, the incidence of VAO was

significantly less in the eyes that underwent PCCC and AV. Figure 2 shows the VAO rates (%) of two groups.

Intraocular lens dislocation was observed in two eyes in group I and three eyes in group II. The incidence of IOL dislocation was similar in two groups. No eyes in group II developed posterior synechiae while seven eyes in group I had posterior synechiae. Glaucoma or retinal detachment had not been observed in any patient postoperatively. Table 3 shows postoperative complication incidences of two groups.

Six months after surgery, 51.1% of all patients were hyperopes and 37.6% were myopes. At the end of the follow-up period, these percentages were 32.5% and 52.1% respectively (Table 4).

DISCUSSION

Primary IOL implantation in children older than 2y has become the standard of care in pediatric cataract surgery^[7-8]. But it is important to choose appropriate surgical technique, IOL material and IOL power for preventing VAO and amblyopia^[1,9]. Until 1990s, the implantation of PMMA IOLs was considered as the best practice in pediatric patients, but over the past

Table 4 Refraction errors at the last follow up in 117 eyes

Age (y)	Hypermetropia (D)				Myopia (D)				Emmetropia
	+0.5/+2	+2/+4	+4/+8	+8	-0.5/-2	-2/-4	-4/-8	-8	-0.5/+0.5
2-8	14	11	1	0	12	5	6	0	7
>8	9	3	0	0	23	11	4	0	11
	38 (32.5%)				61 (52.1%)				18 (15.4%)
	mean: +2.00±2.01 D				mean: -2.34±1.32 D				

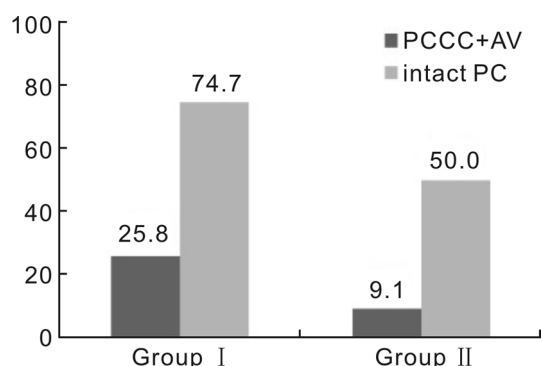


Figure 2 The visual axis opacification (VAO) rates of two groups
Group I refers eyes with PMMA IOLs, Group II refers eyes with acrylic IOLs.

decade three-pieces hydrophobic acrylic IOLs have gained a popularity^[10]. In our study PMMA IOLs were implanted to the patients that were operated between 1994 and 2003, and acrylic IOLs were implanted after 2004. For these historical causes, the follow-up time for PMMA IOLs was longer than acrylic IOLs in our study as similar studies in the literature^[10-12]. In our study, the mean follow up time was 59.8mo in PMMA group and 21.5mo in acrylic group. In several previous studies it was reported that posterior synechia and VAO could occur usually in 3-24mo after surgery^[10-11,13-14], so the difference between the follow up time of two groups may not affect the incidence of postoperative complications.

Since the incidence of PCO has been reported to be almost 100% within two years after pediatric cataract surgery^[13,15], several surgical techniques have been described to prevent it. Posterior continuous curvilinear capsulorhexis with AV is routinely suggested in children under 6-7y or in children who have poor cooperation for portable Neodymium-doped: Yttrium Aluminium Garnet (Nd:YAG) capsulotomy^[1,15-17]. In accordance with this knowledge, the mean age of the patients underwent PCCC and AV was 4.3y and who did not was 7.6y in our study. This procedure greatly influences PCO development in children regardless of IOL material. In our study, the incidence of VAO was 17% in the children underwent PCCC and AV, and 62% in children with intact PC overall the eyes. As compatible with our results, VAO incidence was reported 16%-100% in eyes with intact PC^[10,13-14], and 0-27% in eyes underwent PCCC and AV^[18-20] in different studies. Ram *et al*^[21] evaluated the effect of PCCC with AV

and various IOL materials to development of VAO in 64 eyes of 32 children, at least 2y after cataract surgery. They used the Acrysof acrylic IOL in one group (32 eyes) and PMMA IOL in the other group (32 eyes). In each group, 16 eyes underwent PCCC with AV however the PC was left intact in the other 16 eyes. Twelve eyes with acrylic and 13 eyes with PMMA IOLs developed PCO where PC was intact and 2 eyes with acrylic and 3 eyes with PMMA IOLs in the PCCC with AV subgroup developed VAO ($P<0.05$).

Additionally it was reported that IOL design and material could also affect PCO development. Aasuri *et al*^[13] compared PMMA and acrylic IOLs in an intra-patient study, they implanted an acrylic IOL in one eye and a PMMA IOL in the other eye of each patient with bilateral cataracts in patients older than 5 years old. They detected visually significant PCO of 75% in eyes with PMMA IOLs and 21.5% in eyes with acrylic IOLs where the PC was intact. Wilson *et al*^[10] reported PCO rates 50% in 120 pediatric eyes that implanted PMMA IOLs, 45.4% in 110 pediatric eyes that implanted hydrophobic acrylic IOLs. Rowe *et al*^[12] reported visually significant VAO in PMMA and acrylic IOL group respectively 60% and 45% in patients between the age of 3wk and 15y. As similar with these results, in our study VAO was seen more common in eyes with PMMA IOLs (48.3%) than eyes with acrylic IOLs (27.1%). Experimental studies have shown that acrylic IOLs adhered to the lens capsule more than PMMA IOLs. Due to this stronger adhesion, lens epithelial cell (LEC) regression occurs more frequently in acrylic IOLs. The higher rate of regression and the lower incidence of LECs may explain why PCO formation appears to be reduced with acrylic IOLs^[12,22-23].

Ram *et al*^[24], reported comparable complications in infants with PMMA and hydrophobic acrylic lenses. Unlike our study, they evaluated patients who underwent cataract surgery in the first year of the life. They suggested that children implanted with PMMA IOLs may require earlier surgical re-intervention for PCO.

Also, there are few studies about hydrophilic acrylic IOL implantation in children. Hydrophilic foldable IOLs have excellent uveal biocompatibility and are resistant to damage during folding and insertion. They have low potential to damage corneal endothelium in case of contact. Additionally hydrophilic IOLs are cheaper than hydrophobic IOLs. The

disadvantage of hydrophilic biomaterial is having lower capsular biocompatibility and higher incidence of LEC outgrowth, anterior capsule contracture and PCO. But PCCC with AV, components of standard pediatric cataract surgery, helps to eliminate VAO. In different studies, it was reported that hydrophilic acrylic IOLs produce similar complication rates and visual acuity results compared with hydrophobic acrylic and PMMA IOLs. Hydrophilic acrylic IOLs were found suitable for use in pediatric cataract surgery with performing PCCC with AV^[11,25-26].

The retrospective nature of the study limited us from accurately evaluate the effect of IOL material on postoperative uveal inflammation and synechiae. But during the examination visits it was recorded that, none of the eyes with an acrylic IOL developed any postoperative uveal inflammation and posterior synechiae, unlike 7 eyes with PMMA IOL. Several studies reported significantly less posterior synechiae in the acrylic group compared with the PMMA group^[10,13]. This appears to be caused by less trauma to the eye with the smaller incision necessary for implantation of foldable soft acrylic lens. Besides that, acrylic IOLs have a higher degree of biocompatibility in the eye and cause lesser amount of cellular reaction on the IOL surface^[23]. The intra-ocular inflammation is expected to be greater in children, so acrylic lenses may be preferred especially in younger age group.

The surgical technique, PCCC with AV appeared to increase the risk of IOL dislocation (3%-20%)^[13]. In our patients postoperative IOL dislocation was observed in five eyes, four eyes had undergone PCC with AV during the cataract surgery and one eye had had a trauma after cataract surgery. There was no difference between the IOL groups with regard to IOL dislocation.

In our study, none of the eyes developed glaucoma. This may depend on patients being older than 2 years old and exclusion of the pathologies that increased the glaucoma risk like anterior segment dysgenesis or microphthalmia.

The axial length of pediatric eyes increases rapidly during the first 2y of life, causing a myopic shift in refraction. Additionally, given the fixed position of an IOL in the eye, could lead increasing elongation of the posterior segment of the eye relative to the anterior segment. This effect magnifies the myopic shift that occurs with ocular growth^[27]. For preventing the myopic shift, many reports have recommended undercorrection of the IOL power for pediatric cataracts^[13,15,27]. In our study, with regard to spheric equivalent values, 51.1% of all patients were hyperopes and 37.6% were myopes at postoperative 6mo, whereas at the end of the 40.5mo follow up period these were 32.5% and 52.1% respectively. Ram *et al*^[19], showed refractive errors -4 and -8 D in 20 eyes and >-8 D in 11 eyes of 230 patients between age of 1mo and 15y at the end of

the 30mo follow up time. Age was reported as the significant influencing factor, with younger children exhibiting a larger and more unpredictable myopic shift^[6,19]. We did not observe a large and unpredictable myopic shift and not need IOL exchange due to the patients being older than 2 years old (10 eyes -4 to -8 D, none of eyes >-8 D).

It is known that the presence of strabismus or nystagmus may cause poor visual acuity in pediatric cataracts. In our study there were 22 eyes whose postoperative BCVA were <0.2 and all of these eyes had strabismus and/or nystagmus. The final visual acuity was better than 0.5 in 68.4% of all patients. Comparable with our results, Nihalani and VanderVenn^[28], reported a final BCVA of 0.5 or better in 96% of 124 eyes but they had excluded the patients with ocular comorbidities that would affect the outcomes poorly. Besides that, Hennig *et al*^[29], reported a normal visual status (range: 6/6 to 6/18) in 53.5% of 390 children who had bilateral cataract.

In pediatric age, comparing the results of cataract surgery is difficult because of general limitations including various ages during surgery, different surgical techniques and variations of underlying diseases that have caused cataract. In addition, due to the younger age, patients are uncooperated to visual acuity examination. In our study the patient age was similar between two groups. Furthermore, surgical techniques varied between the groups, IOL was implanted into the eye through a scleral tunnel in PMMA group, and clear corneal incision in the acrylic group. Additionally the acrylic group was surgically treated later than PMMA group. Thus the possibility that the learning curve of the surgeon may also have played a role cannot be completely excluded. Despite these, we believe that this single-center, one-surgeon retrospective study gives valuable and important results about primary IOL implantation in children.

In conclusion, we found hydrophobic acrylic IOLs to be safe in children with less early postoperative inflammation, posterior synechia and VAO development in comparison with PMMA IOLs.

ACKNOWLEDGEMENTS

Conflicts of Interest: Uçan Gündüz G, None; Özmen AT, None; Akova Budak B, None.

Peer Review File: Available at: http://ier.ijo.cn/gjykier/ch/reader/download_attache_file.aspx?seq_id=20210325152914001&flag=1&journal_id=gjykier&year_id=2020&issue=3

REFERENCES

- 1 Vasavada AR, Nihalani BR. Pediatric cataract surgery. *Curr Opin Ophthalmol* 2006;17(1):54-61.
- 2 Nihalani BR, VanderVeen DK. Technological advances in pediatric cataract surgery. *Semin Ophthalmol* 2010;25(5-6):271-274.

- 3 Forbes BJ, Guo SQ. Update on the surgical management of pediatric cataracts. *J Pediatr Ophthalmol Strabismus* 2006;43(3):143-151; quiz 165-6.
- 4 Kumar P, Lambert SR. Evaluating the evidence for and against the use of IOLs in infants and young children. *Expert Rev Med Devices* 2016;13(4):381-389.
- 5 O'Hara MA. Pediatric intraocular lens power calculations. *Curr Opin Ophthalmol* 2012;23(5):388-393.
- 6 Dahan E, Drusedau MU. Choice of lens and dioptric power in pediatric pseudophakia. *J Cataract Refract Surg* 1997;23(Suppl 1):618-623.
- 7 Struck MC. Long-term results of pediatric cataract surgery and primary intraocular lens implantation from 7 to 22 months of life. *JAMA Ophthalmol* 2015;133(10):1180-1183.
- 8 Vasavada AR, Vasavada V. Current Status of IOL implantation in pediatric eyes: an update. *Expert Rev Med Devices* 2017;1-9.
- 9 Lin AA, Buckley EG. Update on pediatric cataract surgery and intraocular lens implantation. *Curr Opin Ophthalmol* 2010;21(1):55-59.
- 10 Wilson ME, Elliott L, Johnson B, Peterseim MM, Rah S, Werner L, Pandey SK. AcrySof acrylic intraocular lens implantation in children: clinical indications of biocompatibility. *J AAPOS* 2001;5(6):377-380.
- 11 Kleinmann G, Zaugg B, Apple DJ, Bleik J. Pediatric cataract surgery with hydrophilic acrylic intraocular lens. *J AAPOS* 2013;17(4):367-370.
- 12 Rowe NA, Biswas S, Lloyd IC. Primary IOL implantation in children: a risk analysis of foldable acrylic v PMMA lenses. *Br J Ophthalmol* 2004;88(4):481-485.
- 13 Aasuri MK, Fernandes M, Pathan PP. Comparison of acrylic and polymethyl methacrylate lenses in a pediatric population. *Indian J Ophthalmol* 2006;54(2):105-109.
- 14 Batur M, Gül A, Seven E, Can E, Yaşar T. Posterior capsular opacification in preschool- and school-age patients after pediatric cataract surgery without posterior capsulotomy. *Turk J Ophthalmol* 2016;46(5):205-208.
- 15 Whitman MC, Vanderveen DK. Complications of pediatric cataract surgery. *Semin Ophthalmol* 2014;29(5-6):414-420.
- 16 Vasavada AR, Praveen MR, Tassignon MJ, Shah SK, Vasavada VA, Vasavada VA, van Looveren J, De Veuster I, Trivedi RH. Posterior capsule management in congenital cataract surgery. *J Cataract Refract Surg* 2011;37(1):173-193.
- 17 Medsinge A, Nischal KK. Pediatric cataract: challenges and future directions. *Clin Ophthalmol* 2015;9:77-90.
- 18 Bhusal S, Ram J, Sukhija J, Pandav SS, Kaushik S. Comparison of the outcome of implantation of hydrophobic acrylic versus silicone intraocular lenses in pediatric cataract: prospective randomized study. *Can J Ophthalmol* 2010;45(5):531-536.
- 19 Ram J, Gupta N, Sukhija JS, Chaudhary M, Verma N, Kumar S, Severia S. Outcome of cataract surgery with primary intraocular lens implantation in children. *Br J Ophthalmol* 2011;95(8):1086-1090.
- 20 Nihalani BR, VanderVeen DK. Comparison of intraocular lens power calculation formulae in pediatric eyes. *Ophthalmology* 2010;117(8):1493-1499.
- 21 Ram J, Brar GS, Kaushik S, Gupta A, Gupta A. Role of posterior capsulotomy with vitrectomy and intraocular lens design and material in reducing posterior capsule opacification after pediatric cataract surgery. *J Cataract Refract Surg* 2003;29(8):1579-1584.
- 22 Oshika T, Nagata T, Ishii Y. Adhesion of lens capsule to intraocular lenses of polymethylmethacrylate, silicone, and acrylic foldable materials: an experimental study. *Br J Ophthalmol* 1998;82(5):549-553.
- 23 Hollick EJ, Spalton DJ, Ursell PG, Pande MV. Lens epithelial cell regression on the posterior capsule with different intraocular lens materials. *Br J Ophthalmol* 1998;82(10):1182-1188.
- 24 Ram J, Jain VK, Agarwal A, Kumar J. Hydrophobic acrylic versus polymethyl methacrylate intraocular lens implantation following cataract surgery in the first year of life. *Graefes Arch Clin Exp Ophthalmol* 2014;252(9):1443-1449.
- 25 Adhikari S, Shrestha UD. Pediatric cataract surgery with hydrophilic acrylic intraocular lens implantation in Nepalese children. *Clin Ophthalmol* 2018;12:7-11.
- 26 Panahi-Bazaz MR, Zamani M, Abazar B. Hydrophilic acrylic versus PMMA intraocular lens implantation in pediatric cataract surgery. *J Ophthalmic Vis Res* 2009;4(4):201-207.
- 27 Lambert SR. Changes in ocular growth after pediatric cataract surgery. *Dev Ophthalmol* 2016;57:29-39.
- 28 Nihalani BR, VanderVeen DK. Benchmarks for outcome indicators in pediatric cataract surgery. *Eye (Lond)* 2017;31(3):417-421.
- 29 Hennig A, Schroeder B, Gilbert C. Bilateral pediatric cataract surgery: outcomes of 390 children from Nepal and Northern India. *J Pediatr Ophthalmol Strabismus* 2013;50(5):312-319.