

Graft epithelial mapping following penetrating keratoplasty using anterior segment optical coherence tomography

Shaimaa A Arfeen, Riham SHM Allam, Noha M Khalil, Ghada A Nassar

Department of Ophthalmology, Faculty of Medicine, Kasr Al Ainy School of Medicine, Cairo University, Cairo 11562, Egypt

Correspondence to: Shaimaa A Arfeen. Department of Ophthalmology, Faculty of Medicine, Kasr Al Ainy School of Medicine, Cairo University, Cairo 11562, Egypt. Shaimaa.arfeen@yahoo.com

Received: 2010-08-12 Accepted: 2021-01-14

Abstract

• **AIM:** To evaluate the changes in corneal epithelial thickness in corneal grafts following penetrating keratoplasty (PK) using anterior segment optical coherence tomography (AS-OCT), and to determine the role of epithelial thickness mapping in the early detection of graft rejection.

• **METHODS:** This prospective comparative observational study included 20 patients (20 eyes) who underwent PK as study group and 16 patients (16 eyes) as control group. Corneal epithelial thickness mapping using AS-OCT was performed at 2wk, 1 and 3mo postoperatively. The parameters of epithelial thickness and distribution at the 3mo were compared to 16 patients (16 eyes) with allograft rejection following PK.

• **RESULTS:** There was significant decline in the superior, inferior, maximum, and minimum epithelial thickness values of the study group at 1mo compared to 2wk ($P=0.0004$, 0.0001 , 0.0001 , 0.04 respectively) with no significant differences at 3mo compared to 1mo ($P=0.4$, 0.1 , 0.8) respectively. Percentage of reduction in epithelial thickness was significantly higher than that of stromal thickness at 1mo compared to 2wk ($P=0.04$). The epithelial thickness maps showed a similar pattern of epithelial thickness distribution in the study group and in the rejection group showing considerable corneal edema. However, the allograft rejection group showed irregular pattern of epithelial thickness distribution in patients showing relatively higher central corneal thickness (CCT) as measured by pachymetry map.

• **CONCLUSION:** Quantitative assessment of graft epithelial remodeling following PK shows early changes that

contribute to significant corneal graft thickness changes. Changes in corneal epithelial thickness and pattern of distribution could be used as an indicator for corneal graft rejection.

• **KEYWORDS:** AS-OCT; corneal epithelial thickness; penetrating keratoplasty; epithelial remodeling; corneal graft rejection

DOI:10.18240/ier.2021.01.04

Citation: Arfeen SA, Allam RSHM, Khalil NM, Nassar GA. Graft epithelial mapping following penetrating keratoplasty using anterior segment optical coherence tomography. *Int Eye Res* 2021;2(1):20-24

INTRODUCTION

The corneal epithelium acts as a barrier which protects the corneal graft against infection and damage. Surface epithelial dysfunction following penetrating keratoplasty (PK) plays a vital role in delayed visual rehabilitation, poor refractive outcome, and postoperative patient discomfort^[1]. Although endothelial dysfunction, infection, and high astigmatism are common causes of graft failure after PK, epithelial dysfunction can contribute to failure of up to 25% of grafts^[2]. Anterior segment spectral domain optical coherence tomography (AS-OCT) has become a promising non-contact method to study corneal epithelial thickness. The high-speed and resolution make AS-OCT a popular device in assessing corneal epithelial thickness with good repeatability and accuracy at the same time^[3-6].

As evaluation of the corneal epithelial thickness following PK reflects corneal graft competence, it is important to quantitatively assess the changes in the graft epithelium thickness and distribution following PK. As early rejection signs could be easily missed on routine slit-lamp examination, AS-OCT changes, if present, could be a clue to the diagnosis of early rejection. The aim of this study is to evaluate changes in the epithelial thickness map of corneal grafts following PK and the central corneal thickness by AS-OCT at 2wk, 1 and 3mo postoperatively, and to compare the obtained parameters at the 3mo to patients with corneal graft rejection following

PK. This is done as an attempt to establish an objective method that could assist in the clinical diagnosis of early graft rejection.

SUBJECTS AND METHODS

Ethical Approval This study adhered to the tenets of the Declaration of Helsinki and an informed written consent was signed by all patients before participation.

This study included 20 eyes of 20 patients who underwent PK at Cairo University Hospital during the period between February 2017 and May 2018.

Preoperatively, complete ophthalmological examination was performed for the recipients including; documentation of the preoperative corneal pathology, measurement of best corrected visual acuity (BCVA) using a Snellen chart, slit-lamp biomicroscopy, Goldmann applanation tonometry, and a dilated fundus examination or B-scan ultrasonography if fundus was not visible. Patients with any systemic or ocular disorders that might affect epithelial wound healing, such as eyelid abnormalities, corneal hyposthesia, diabetes mellitus, and rheumatoid arthritis, were excluded from the study.

Surgery was performed by experienced surgeons under general anesthesia. All the corneal grafts were preserved in McKarey-Kaufmann medium with complete aseptic precautions. All surgeons used the same trephine and punch sizes (7.5 mm and 8 mm respectively). The suturing technique consisted of 16-18 interrupted 10-0 nylon Mono-filament sutures. All patients received the same postoperative treatment in the form of topical prednisolone acetate 1% every 2h, topical Gatifloxacin 0.3% q.i.d and a preservative free lubricant. The treatment was tapered gradually over 3mo.

AS-OCT Imaging Technique Corneal epithelial thickness maps were obtained using AS-OCT (Optovue RTVue model RT100, Optovue, Inc., Fremont, CA). A corneal adapter module (CAM) which produced telecentric scanning for anterior segment imaging using CAM lens (CAM-L6.0 to 2.0 mm) was mounted on the OCT. A pachymetry map scan and an epithelial thickness map scan were chosen; a scan rate of 26 000 axial scans per second with a 6mm scan diameter and 8 radial scan lines as previously reported^[7].

The scans were performed at 2wk, and 1 and 3mo postoperatively in each subject. The epithelial thickness map was divided into three zones on the basis of diameter: Zone (1): central 2 mm; Zone (2): mid-peripheral 2-5 mm; Zone (3): peripheral 5-6 mm.

The epithelium statistics within the central 5 mm zone, including the average epithelial thickness of the superior and inferior zones, the minimum and maximum thicknesses, and map standard deviation (MSD) from the average value of a single epithelial thickness map, were calculated automatically by the RTVue corneal adaptor module software. The overall corneal thickness was also evaluated. The pattern of

distribution of the epithelial thickness in the map was also noticed and documented.

The AS-OCT results at the third month were then compared to age matched group of 16 eyes (16 patients) having allograft rejection which was defined as new development of one or more of the following; corneal haze, keratic precipitates, or limbal injection in a patient with previously clear graft associated with recent reduction of visual acuity^[8]. Patients were only included if a complete automated reproducible epithelial map could be obtained (16 eyes out of 24 examined eyes).

Statistical Analysis Summary statistics were done. Numerical variables were tested for normality by the Shapiro-Wilk normality test. Comparison between values at baseline & follow up was done with the paired *t*-test for normally distributed variables or the Wilcoxon matched pairs sign rank test for non-normally distributed data. The percent change in stromal and epithelial thickness at follow up was calculated as follows: (follow-up thickness-baseline thickness/baseline thickness)×100.

Comparison between percent change in epithelial versus stromal thickness was done with the Wilcoxon-rank sum test. Comparison between cases and controls was done using Student's *t*-test. Data analysis was done using statistics/data analysis (STATA) version 13.1 software.

RESULTS

Twenty eyes of twenty patients that fulfilled the inclusion criteria were enrolled in this study; twelve females (60%) and 8 males (40%). The mean age of the patients at time of the study was 40.5±11.40y (16-62y).

The indications for PK in the study group were bullous keratopathy (2 eyes, 10%), corneal dystrophy (1 eye, 5%), keratoconus (3 eyes, 15%), leucoma adherent (2 eyes, 10%) and leucoma non-adherent (12 eyes, 60%).

There were no statistically significant differences in age, BCVA, spherical equivalent, IOP, CCT and maximum epithelial thickness between different etiological groups at 3mo postoperatively as shown in (Table 1).

The mean superior epithelial thickness was 54.85±8.75, 52.15±7.48 and 51.7±7.84 µm at 2wk, 1 and 3mo respectively. There was a significant decline in the epithelial thickness values at 1 and 3mo compared to 2wk ($P<0.001$). However, there were no significant differences in the epithelial values of 3mo compared to 1mo ($P=0.4$).

The mean inferior epithelial thickness was 53.55±6.72, 51.55±6.43, 52.6±5.9 µm at 2wk, 1 and 3mo respectively. There was a significant decline in the epithelial thickness values at 1mo compared to 2wk ($P<0.001$). However, there were no significant differences in the epithelial values at 3mo compared to 2wk and 1mo ($P=0.2$, $P=0.1$ respectively).

Table 1 Demographic data of the study group

Parameters	Bullous keratopathy	Corneal dystrophy	Keratoconus	Leucoma adherent	Leucoma nonadherent	mean±SD
Age	56.00±4.6	45.00±0.0	27.57±8.76	34.00±24.6	45.78±11.5	0.58
BCVA (logMAR)	0.72±0.40	0.8±0.46	0.40±0.49	0.55±0.45	0.56±0.50	0.162
SE	4.50±2.12	4.5±0.0	5.67±3.79	5.50±0.71	5.00±1.21	0.889
IOP (mm Hg)	14.5±1.11	15.1±0.1	17.3±1.0	16.0±0.1	15.5±1.78	0.751
CCT (µm)	543.5±19.9	520±0.0	524±36.5	530±22.4	522±16.8	0.881
Epithelium maximum (µm)	76.7±11.5	75.4±12.3	76.8±12.6	76.9±11.8	76.9±12.1	0.41

BCVA: Best corrected visual acuity; SE: Spherical equivalent; IOP: Intraocular pressure; CCT: Central corneal thickness.

The maximum corneal epithelial thickness within the central 5 mm showed significant changes at 1mo postoperatively compared to 2wk (mean 75.5, 78.7 µm respective) ($P\leq 0.001$) with no significant decrease at 3mo (mean 75.65±11.96 µm) ($P=0.8$).

The minimum corneal epithelial thickness within the central 5 mm showed significant changes at 1mo postoperatively compared to 2wk (36.8±5.67 µm) ($P=0.04$) and 3mo (35.15±5.34 µm) ($P=0.03$).

There was significant difference between the percentage of reduction of maximum epithelial thickness (3.91%) and stromal thickness (1.95%) at 1mo compared to 2wk ($P=0.04$), with no significant difference in the percentage of reduction of epithelial thickness (3.66%) and stromal thickness (4.46%) at 3mo compared to 2wk ($P=0.1$).

There was statistically significant decrease in the mean CCT at 2wk, 1 and 3mo postoperative period (541.8±22.55 µm, 530.2±19.82 µm and 515.3±17.45 µm) ($P\leq 0.001$).

On comparing the epithelial thickness map parameters at 3mo follow up with those of the allograft rejection group, there was a statistically significant difference in the central corneal thickness between both groups. The median thickness in graft rejection group was 617 µm (549-652 µm), while at 3mo follow up it was 514.5 µm (505-521 µm) ($P\leq 0.001$). However, there was no statistically significant difference between both groups regarding epithelial thickness map parameters (Table 2). The pachymetry map showed within normal total CCT in the study group compared to above normal CCT in the rejection group.

Regarding the pattern of epithelial thickness distribution, both groups showed decreased central epithelial thickness surrounded by an intermediate zone of relative thickening. In the study group, a peripheral zone of thin epithelium reappeared (central thin zone-paracentral within normal zone-peripheral thin zone). On the contrary, the rejection group showed progressive thickening of the epithelium towards the periphery (central thin zone-paracentral within normal zone-peripheral thick zone; Figure 1).

DISCUSSION

The corneal epithelium plays an important role in maintaining

Table 2 Comparison between epithelial thickness parameters at 3mo and allograft rejection

Items	Rejection group	Control group	mean±SD (µm)
Superior	51.81±7.42	51.7±7.84	0.9
Inferior	54.81±9.82	52.6±5.90	0.4
Maximum	69.44±12.05	75.65±11.96	0.1
Minimum	38±7.31	35.15±5.34	0.2

the integrity of the ocular surface. Previous studies evaluated the clinical course of corneal epithelial wound healing after PK and reported total replacement of the donor epithelium by the recipient in the initial postoperative weeks by mitosis, migration and transformation of the host stem cell population^[9-12].

Previous morphometric analysis of graft epithelium following PK indicated that the most prominent epithelial change was the appearance of elongated spindle-shaped cells, which was suggested to be resulting from migration of the cells from the periphery of the cornea^[13-15]. Also, other studies reported the presence of extra large cells, nucleated cells, and small cell formations. All these changes took place in the early postoperative period then started to decrease months later^[16].

In this study, we evaluated the topographic epithelial thickness changes after PK using AS-OCT to investigate whether or not the previously reported results of cellular changes were accompanied with similar changes in epithelial thickness. The postoperative changes in corneal epithelial thickness have been previously studied following cataract surgery, and showed early epithelial remodeling^[17-19]. However, no previous studies have investigated these changes following keratoplasty.

The current study indicated that the epithelial thickness showed a statistically significant decrease during the postoperative period, with a more significant decline occurring at 2mo irrespective of the original preoperative diagnosis. These changes are associated with similar changes in the central corneal thickness. It was found that the change in corneal thickness was attributed mainly to the early reduction of epithelial thickness than in the stroma.

This remodeling in epithelial thickness might be explained by the presence of a correlation between the inflammatory cascades and the use of postoperative anti-inflammatory drugs

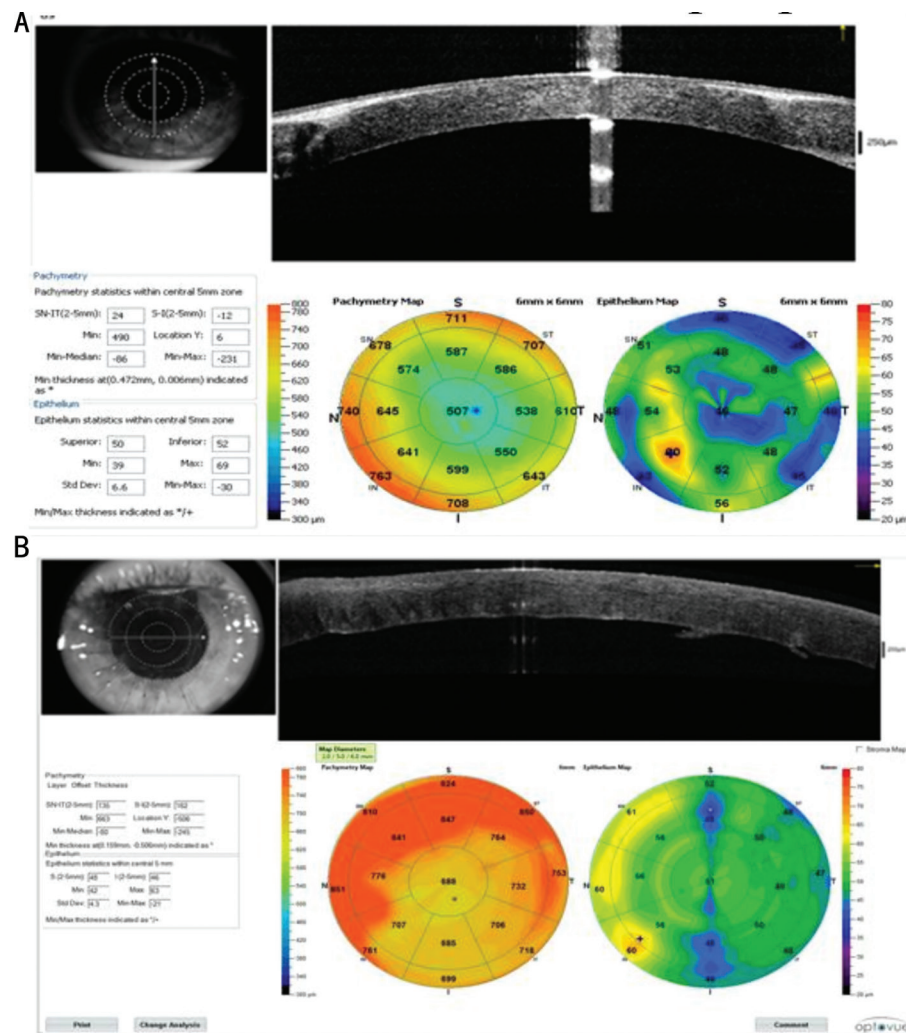


Figure 1 AS-OCT showing the pattern of epithelial thickness distribution A: A control group patient showing central thinning, mid peripheral relative thickening and peripheral thinning (central thin zone-paracentral within normal zone-peripheral thin zone) and a within normal CCT in pachymetry map; B: A rejection group patient showing progressive thickening of the epithelium as we move to the periphery (central thin zone-paracentral within normal zone-peripheral thick zone) and an increased CCT in pachymetry map.

or may occur as normal, nonpathogenic, changes during the healing process. It might represent one of the factors that affect graft clarity, which potentially improve the visual outcome and graft survival.

In order to find out if similar remodeling changes might occur in the epithelium of rejected corneal grafts, the results were compared to age matched group with corneal graft rejection. Allograft rejection was defined as new development of corneal haze, keratic precipitates, limbal injection in a patient with previously clear graft. We found a slight increase in epithelial thickness parameters in rejected grafts which were not significant. This could be explained by the inflammatory process of rejection in the form of graft edema as well as abnormal proliferation of corneal epithelium. This was further supported by the pattern of distribution of epithelial thickness in the rejected group which indicated the abnormal haphazard proliferation of epithelial cells in contrast to the study group which showed increased peripheral epithelial thickness

compared to decreased central corneal thickness. This pattern of distribution of epithelial thickness in the study group as well as the rejection group could be explained by the fact that the inflammatory process and epithelial cell proliferation and migration, start from the limbus to the center, resulting in increased epithelial thickness.

This might indicate that regular pattern of distribution of epithelial thickness associated with within normal corneal thickness could predict decreased possibility of corneal rejection. We assumed that a larger sample size could probably obtain more statistically significant results.

These results suggest the importance of following the changes that occur to the graft epithelium following PK. Progressive increase in the epithelial thickness might indicate the onset of epithelial rejection, while non-regression of this thickening might indicate progression into further stromal and even endothelial rejection.

To the best of our knowledge, no previous studies have

evaluated in vivo changes in the epithelial layer thickness following PK. Figueiredo *et al*^[20] tried to evaluate the changes that occur in the epithelium of rejected grafts in rat model but could not apply them to human model, being of different nature. They mentioned that epithelial changes could be a predictor for further progression into stromal and endothelial rejection.

This study concludes that persistent increase in the epithelial thickness may indicate early corneal graft rejection and that increased thickness of the peripheral corneal epithelium, compared to the central epithelium, together with within normal corneal thickness, might predict survival of the graft and that the same pattern of distribution associated with increased corneal thickness might necessitate the intake of anti-inflammatory drugs which could prevent graft rejection. However, this will need a further study with a larger sample size to monitor the sequence of pattern distribution of epithelial thickness among rejected grafts and their response to anti-inflammatory drugs.

We recommend future studies to be conducted with a larger number of patients, using ultra high resolution AS-OCT, to establish the correlation between the changes in epithelial-basement membrane zone and the risk for graft rejection. This study could be a nidus for future research evaluating the effect of treatment with frequent topical steroids and systemic immune modulators on regression of epithelial tomographic changes.

ACKNOWLEDGEMENTS

Conflicts and Interest: Arfeen SA, None; Allam RSHM, None; Khalil NM, None; Nassar GA, None.

Peer Review File: Available at: http://ier.ijo.cn/gjykier/ch/reader/download_attache_file.aspx?seq_id=20210326104717001&flag=1&journal_id=gjykier&year_id=2021&issue=1

REFERENCES

- Wilson SE, Kaufman HE. Graft failure after penetrating keratoplasty. *Surv Ophthalmol* 1990;34(5):325-356.
- Price FW Jr, Whitson WE, Collins KS, Marks RG. Five-year corneal graft survival. A large, single-center patient cohort. *Arch Ophthalmol* 1993;111(6):799-805.
- Ramos JL, Li Y, Huang D. Clinical and research applications of anterior segment optical coherence tomography - a review. *Clin Exp Ophthalmol* 2009;37(1):81-89.
- Kanellopoulos AJ, Asimellis G. *In vivo* three-dimensional corneal epithelium imaging in normal eyes by anterior-segment optical coherence tomography: a clinical reference study. *Cornea* 2013;32(11):1493-1498.
- Han SB, Liu YC, Noriega KM, Mehta JS. Applications of anterior segment optical coherence tomography in cornea and ocular surface diseases. *J Ophthalmol* 2016;2016:4971572.
- Ang M, Baskaran M, Werkmeister RM, Chua J, Schmidl D, Aranha Dos Santos V, Garhöfer G, Mehta JS, Schmetterer L. Anterior segment optical coherence tomography. *Prog Retin Eye Res* 2018;66:132-156.
- Rocha KM, Perez-Straziota CE, Perez-Straziota E, Stulting RD, Randleman JB. SD-OCT analysis of regional epithelial thickness profiles in keratoconus, postoperative corneal ectasia, and normal eyes. *J Refract Surg* 2013;29(3):173-179.
- Panda A, Vanathi M, Kumar A, Dash Y, Priya S. Corneal graft rejection. *Surv Ophthalmol* 2007;52(4):375-396.
- Kawamoto K, Morishige N, Yamada N, Chikama T, Nishida T. Delayed corneal epithelial wound healing after penetrating keratoplasty in individuals with lattice corneal dystrophy. *Am J Ophthalmol* 2006;142(1):173-174.
- Dohlman CH. On the fate of the corneal graft. *Acta Ophthalmol (Copenh)* 1957;35(4):286-302.
- Lemp MA. The surface of the corneal graft: *in vivo* color specular microscopic study in the human. *Trans Am Ophthalmol Soc* 1989;87:619-657.
- Lu L, Reinach PS, Kao WWY. Corneal epithelial wound healing. *Exp Biol Med (Maywood)* 2001;226(7):653-664.
- Brown AC, Lohman E, Rao N, Aquavella JV. *Human corneal epithelial appearance following penetrating keratoplasty*. ARVO Abstracts. Supplement to Invest. Ophthalmol Vis Sci St. Louis, C. V. Mosby, 1982:24.
- Khodadoust AA, Silverstein AM. The survival and rejection of epithelium in experimental corneal transplants. *Invest Ophthalmol* 1969;8(2):169-179.
- Tsubota K, Yamada M, Naoi S. Specular microscopic observation of human corneal epithelial abnormalities. *Ophthalmology* 1991;98(2):184-191.
- Tsubota K, Mashima Y, Murata H, Yamada M, Sato N. Corneal epithelium following penetrating keratoplasty. *Br J Ophthalmol* 1995;79(3):257-260.
- Li YJ, Kim HJ, Joo CK. Early changes in corneal edema following torsional phacoemulsification using anterior segment optical coherence tomography and Scheimpflug photography. *Jpn J Ophthalmol* 2011;55(3):196-204.
- Zheng T, Yang J, Xu JJ, He WW, Lu Y. Near-term analysis of corneal epithelial thickness after cataract surgery and its correlation with epithelial cell changes and visual acuity. *J Cataract Refract Surg* 2016;42(3):420-426.
- Kanellopoulos AJ, Asimellis G. Corneal epithelial remodeling following cataract surgery: three-dimensional investigation with anterior-segment optical coherence tomography. *J Refract Surg* 2014;30(5):348-353.
- Figueiredo FC, Nicholls SM, Easty DL. Corneal epithelial rejection in the rat. *Invest Ophthalmol Vis Sci* 2002;43(3):729-736.