

Protective effect of Danhong injection on retina of diabetic rats

Hai-Yan Fan^{1,2}, Jun-Fang Wang^{1,2}, Zheng Li³, Zhong Chen⁴

¹Department of Ophthalmology, the Ninth People's Hospital, Shanghai Jiao Tong University School of Medicine, Shanghai 200011, China

²Shanghai Key Laboratory of Orbital Diseases and Ocular Oncology, Shanghai 200011, China

³Yueyang Hospital of Integrated Traditional Chinese and Western Medicine, Shanghai University of Traditional Chinese Medicine, Shanghai 200437, China

⁴Shanghai Linfen Community Health Service Center, Shanghai 200435, China

Correspondence to: Jun-Fang Wang. Department of Ophthalmology, the Ninth People's Hospital, Shanghai Jiao Tong University School of Medicine, Shanghai 200011, China; Shanghai Key Laboratory of Orbital Diseases and Ocular Oncology, Shanghai 200011, China. 519759484@qq.com

Received: 2020-01-15 Accepted: 2020-04-08

Abstract

• **AIM:** To observe the protective effect of Danhong injection on retina of diabetic rats and explore its mechanism.

• **METHODS:** Sixty male SD rats were randomly divided into four groups: normal group, diabetic group, Danhong intervention group and blank intervention group. The rats in the latter three groups were injected with 50 mg/kg of streptozotocin (STZ) into the abdominal cavity to establish diabetic retinopathy rat model. On the day after successful modeling, Danhong treatment group was injected with 5 mL/kg Danhong injection intraperitoneally every day, while the blank intervention group was treated with intraperitoneal injection of distilled water with the same volume as Danhong treatment group. Therapeutic effects were observed from two levels: retinal vascular disease and nerve injury. Retinal morphology was observed by hematoxylin-eosin (HE) staining at the level of vascular disease. The expression of retinal vascular endothelial growth factor (VEGF) was detected by immunohistochemistry. Neurological injury level: Tunel staining was used to observe apoptotic cells, and transmission electron microscopy was used to observe the morphology of retinal ganglion cells.

• **RESULTS:** Vascular level: in the normal group, the structure of retinal tissues showed clear layers. The

structure of the diabetic group and blank intervention group was more disordered than that of the normal group, and the Danhong treatment group was better than that of the diabetic group and blank intervention group. Compared with the diabetic group and blank intervention group the expression of VEGF in danhong intervention group decreased. Neurological injury level: there was a larger degree of apoptosis of ganglion cells in the diabetic group and the blank intervention group, while the number of apoptotic cells in the Danhong intervention group was lower than the diabetic group and blank intervention group.

• **CONCLUSION:** Danhong injection has protective effect on the retina of diabetic rats. It can improve the condition of retinal ischemia and hypoxia by down-regulating VEGF, reduce the formation of retinal neovascularization. At the same time, it can reduce the apoptosis of retinal nerve cells to ascertain extent.

• **KEYWORDS:** Danhong; diabetic retinopathy; retinal ganglion cells; apoptosis; rats

DOI:10.18240/ier.2020.04.07

Citation: Fan HY, Wang JF, Li Z, Chen Z. Protective effect of Danhong injection on retina of diabetic rats. *Int Eye Res* 2020;1(4):240-245

INTRODUCTION

Diabetic retinopathy is a serious blinding eye disease and the most common complication of diabetes. At present, there is no effective drug for the early prevention of the disease, and many targeted treatments are for the late complications. Therefore, it is very necessary to explore a drug for the early prevention of diabetic retinopathy. Danhong injection is made from the traditional Chinese medicine *salvia miltiorrhiza* and *safflower*. It can reduce the damage of vascular endothelial cells, improve local blood circulation, and also has the effect of protecting neurons^[1]. The purpose of this study was to observe whether Danhong injection had protective effects on retinal vascular disease and nerve injury in diabetic rats, and to explore the mechanism preliminarily.

MATERIALS AND METHODS

Experimental Animals and Groups Totally 60 SD rats (purchased from Shanghai Silaike Experimental Animal Co., Ltd.), male, SPF grade, body weight 180g-220g,

were randomly divided into normal group, diabetes group, Danhong intervention group and blank intervention group. 15 rats in each group were fed with normal diet. All animals were required to be healthy and excluded from eye diseases before enrollment. The feeding and use of experimental animals follow the requirements of experimental animal ethics and comply with the relevant ethical regulations of animal experiments of the Ninth People's Hospital affiliated to Shanghai Jiao Tong University School of Medicine.

Main Reagents, Drugs and Instruments Danhong injection (Shandong Buchang Pharmaceuticals), streptozotocin (sigma companies in the United States), ready-to-use SABC immunohistochemical staining kits(Wuhan Boster Biological Technology), Philips transmission electron microscope, DAB staining box (Wuhan Boster Biological Technology), VEGF a fight (Santa cruz, USA), and blood glucose meter and test paper (Switzerland Roche), Cell Cycle and Apoptosis Analysis Kit (Roche company, USA)

Methods

Establishment of diabetes model All rats needed adaptive feeding for 1wk, diet was forbidden for 18h before fasting blood glucose test. This time blood glucose was taken as the basic blood glucose, and if there was >14 mmol/L in rats, it was excluded into the group. STZ was intraperitoneally injected into rats in the diabetes group, Danhong intervention group and blank intervention group at a dose of 50 mg/kg, and was injected strictly according to body weight. After 72h of administration, all rats were forbidden to eat for 18h again. If the fasting blood glucose was >16.7 mmol/L, the model was established successfully. If the blood glucose was less than 14mmol/L, the rats were injected with STZ once more. In this experiment, fasting blood glucose was >16.7 mmol/L in all rats and without repeated injection.

Intervention and observation Intraperitoneal injection was used on the day of modeling. In the Danhong intervention group, 5 mL/kg body weight of Danhong injection was intraperitoneally injected every day, and in the blank intervention group, each animal was injected with distilled water equal to that in the Danhong intervention group. Normal feed was provided, and the drug was given once a day for a total of 12wk. During the experiment, we measured blood glucose twice a week, and the blood glucose of the modeled rats did not recover spontaneously. Their body weight was significantly lower than that of the normal group, and their daily water intake and urine volume were significantly higher than that of the normal group.

Sampling and specimen preparation Rats were killed 1wk after stopping the injection, and we gathered the full eye immediately and placed it in a fixed liquid and at 4°C refrigerator, and fixed for 48-72h. The cornea and lens were cut

off and paraffin sections were performed. During sectioning, care was taken to prevent tissue fragmentation, and then conventional hematoxylin-eosin (HE) staining was performed.

TUNEL staining Paraffin sections were routinely dewaxed and hydrated. Operations were carried out according to the instructions of the kit: first, sections were treated with hydrogen peroxide for 10min; rinse off the hydrogen oxide with distilled water and digest for 15min; flush with PBS and drop in buffer; dry the remaining liquid and add the labeled liquid. Labeling liquid should be prepared in advance, biotin 1ul, TDT1ul and labeling buffer 18ul should be prepared. We wait for 2h and add the sealing liquid for treatment, then add antibody diluent and peroxidase DAB color rendering. TUNEL labeled positive cells were counted that is, the nuclei were marked brown and black.

Electron microscopy The eyeball of the other side of the rat was completely removed by the same method and placed in a special fixative solution of 2.5% glutaraldehyde. The fixation time of the eyeball should be more than 72h, and the retinal tissue should be cut into a size of 1 mm×1 mm after 36h of fixation to ensure sufficient fixation of the tissue. After conventional dehydration and embedding, ultra-thin sections were prepared with a thickness of 10 nm and double staining (dioxuranium acetate 2% and lead citrate). Observe and photograph under transmission electron microscope.

Immunohistochemical detection After conventional dewaxing, paraffin sections were placed at room temperature and treated with H₂O₂ for 10min; antigen repair was performed by dropping citrate buffer and the reaction time was 3min; the blocking solution was added and let stand for 10min; then the VEGF primary anti-VEGF working solution was added and left overnight. The next day, add biotin-labeled goat anti-IgG secondary antibody, slice and incubate at room temperature for 30min. Add DAB to develop color and repeat with hematoxylin.

Quantitative measurement of VEGF the quantitative measurement was carried out with image-pro plus professional Image analysis software from the United States. The measurement index was the cumulative absorbance of slices (IOD). Four slices were randomly selected from each eyeball. At the time of determination, the magnification of slices should be kept consistent at 400 times, and the mean value of IOD was taken for statistical analysis.

Statistical Analysis SPSS 17.0 software was used for statistical analysis of the data. All the data were expressed as mean±SD. The homogeneity test of variance was carried out before the analysis of univariate variance, and Snk-q test was used for pair-wise comparison of mean. $P<0.05$ was considered to be the baseline statistical significance level. Four comparisons were made: diabetes versus each of the

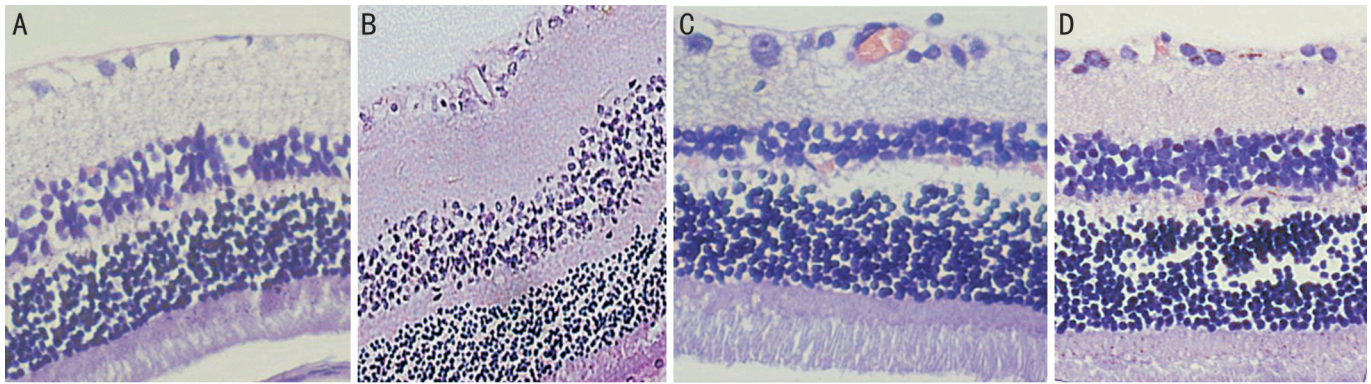


Figure 1 HE staining ($\times 400$) A: Normal group; B: Diabetes group; C: Danhong intervention group; D: Blank intervention group.

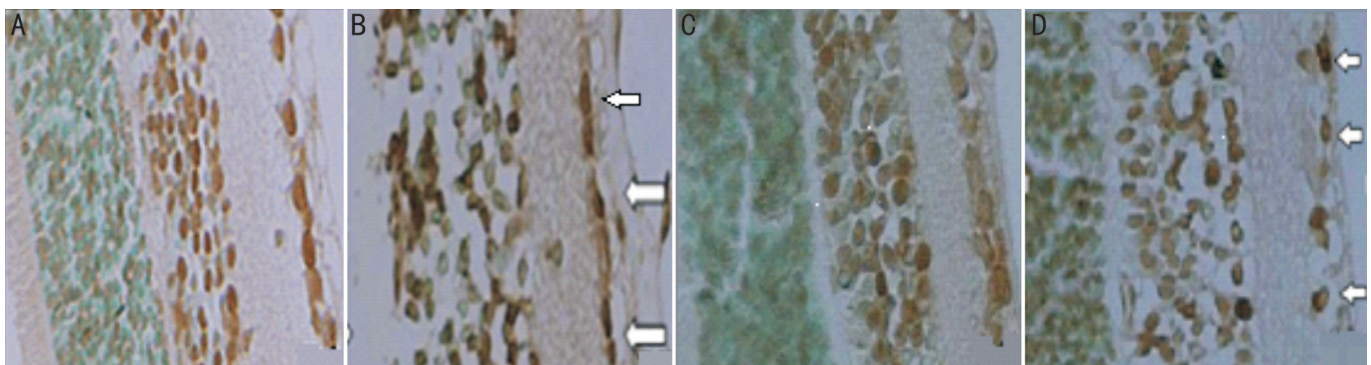


Figure 2 RGCL cells of rats (TdT marker $\times 400$) A: Normal group; B: Diabetes group; C: Danhong intervention group; D: Blank intervention group.

three other groups and Danhong versus blank intervention, so a significance level of 0.0125 was used after Bonferroni correction for multiple hypothesis testing.

RESULTS

Observation of Retinal Tissue Morphology The structure of each layer of the retina was clearly seen in the normal group of rats, with nerve fibers in neat arrangement, no edema and endothelial cells breaking through the inner boundary membrane, and the morphology of capillary lumen was normal.

In the diabetic group and the blank intervention group, the retinal cells in each layer were arranged in relative disorder, and partial capillary lumen occlusion was observed. The ganglion cells showed nucleation and nucleolysis.

Compared with the diabetic group, the cells in the Danhong intervention group were arranged in a neat order. There was no cell edema, no endothelial cells breaking through the inner boundary membrane, less edema between pericytes and between endothelial cells, no fusion between the inner and outer nuclear layers, and no occlusion of capillaries. Ganglion cell morphology was basically normal, and the pathological changes were less severe in the diabetic group (Figure 1).

TUNEL Staining Two sections were randomly selected from each eyeball. After staining by TUNEL technique, the nuclei of some RGCL cells were brown-yellow particles, namely positive cells (Figure 2).

The average number of positive cells in each eye of the four groups was 1.11, 5.60, 2.90, 6.50 (Figure 3) and the difference was statistically significant ($P < 0.001$). The number of positive cells in the diabetes group was significantly higher than that in the normal group ($P < 0.001$). The number of positive cells in the danhong intervention group was significantly lower than that in the diabetes group ($P < 0.001$) and the blank intervention group ($P < 0.001$). There was no statistically significant difference between the blank intervention group and the diabetes group ($P = 0.799$).

Retinal Electron Microscopy In the normal group, the retinal ganglion cells had intact nuclear membrane, abundant cytoplasm, normal intracellular structure and morphology, and no nuclear membrane shrinkage or fragmentation (Figure 4A). In the diabetic group, retinal ganglion cells were visibly shrunken, cells lost their normal morphology, the nucleus was broken, the nuclear membrane was indistinct, chromatin was decreased, and mitochondria were swollen (Figure 4B). The cell membrane of ganglion cells in the rats of the Danhong injection group showed mild puckering, and the cytoplasm was still abundant. No obvious puckering and fragmentation of nuclear membrane was observed, chromatin showed mild edge set, and mitochondrial swelling was not obvious (Figure 4C). In the blank intervention group, the cell structure of retinal ganglion cells was disorganized and the cell membrane was shriveled obviously. The cells were disordered, lose their

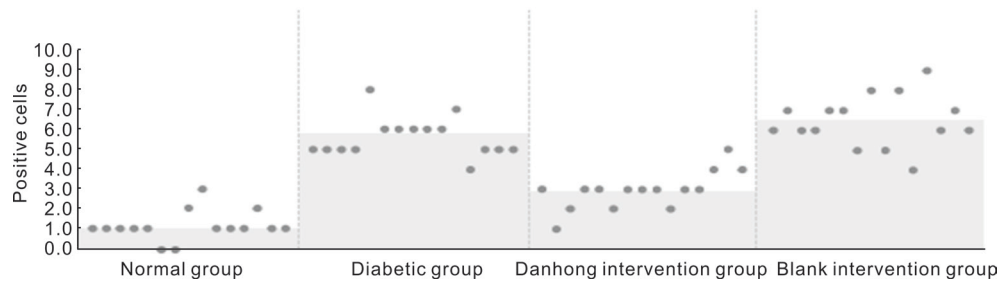


Figure 3 TUNEL Staining in four groups.

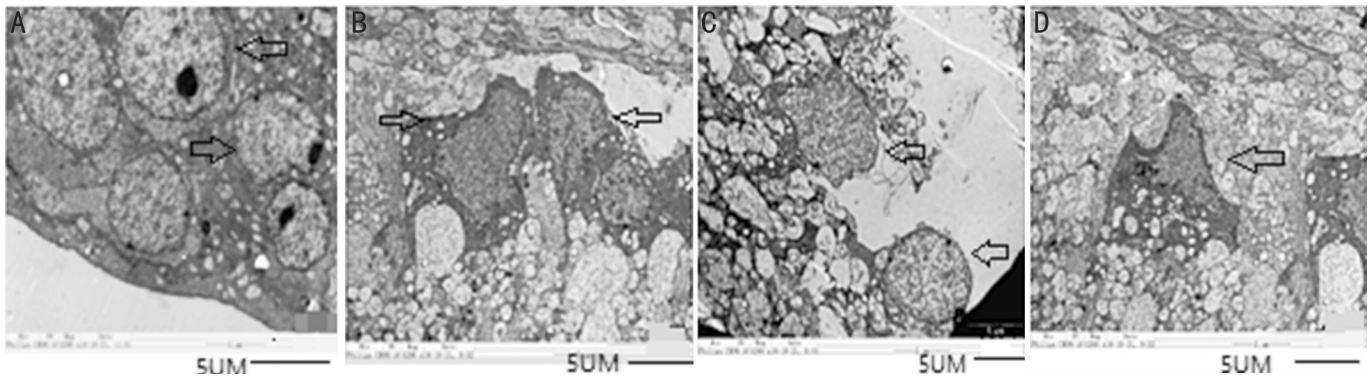


Figure 4 Observation of retinal ganglion cells under electron microscope (×20500) A: Normal group; B: Diabetes group; C: Danhong intervention group; D: Blank intervention group.

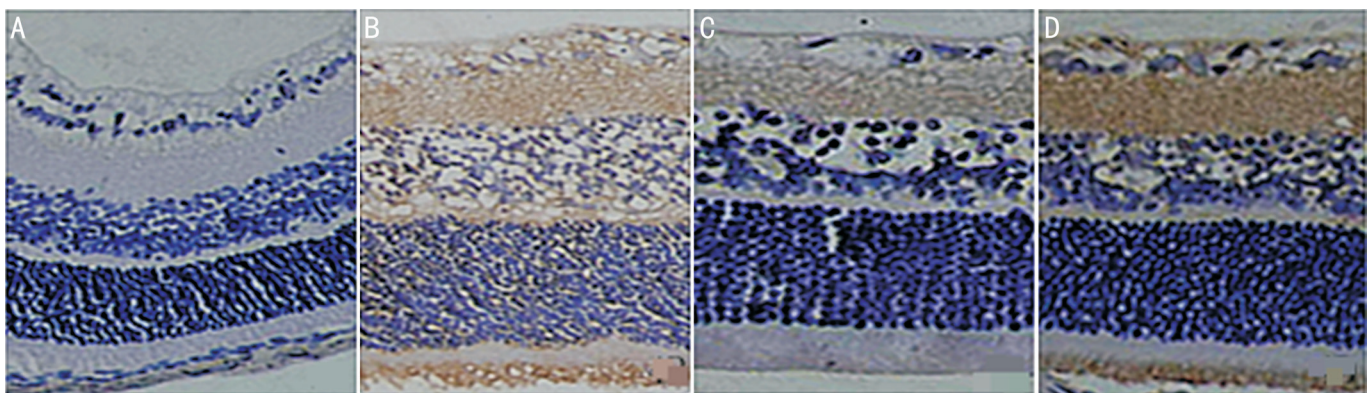


Figure 5 Retinal VEGF expression in rats (SABC ×400) A: Normal group; B: Diabetes group; C: Danhong intervention group; D: Blank intervention group.

normal cell form .The nucleus was condensed and the nuclear membrane was invaginated. Internuclear space could be seen, along with swollen mitochondria and vacuolar changes (Figure 4D)

Immunohistochemical Results VEGF was almost not expressed in the retinal layers of the normal group (Figure 5A). VEGF expression was strongly positive in the diabetes group (Figure 4B) and the blank intervention group (Figure 5D), and was expressed in all layers of the retina.VEGF was also expressed in danhong intervention group (Figure 5C), but showed a weak expression, especially in ganglion cell layer and outer plexus layer. Four groups of VEGF level of immune response IOD determination results for: normal group of 2023±1167, diabetes group of 5682±3763, Danhong intervention group 2221±1301, blank intervention group 5133±2385. There was a marginal difference in VEGF

expression between the normal group and the diabetes group ($P=0.014$), and a marginal difference between the Danhong intervention group and the diabetes group ($P=0.017$). There was no statistically significant difference between the blank intervention group and the diabetes group ($P=0.682$). There was a marginal difference between the Danhong intervention group and blank intervention group ($P=0.019$).

DISCUSSION

DR is one of the most common complications of diabetes and an important cause of adult blindness^[2]. After 20 years of diabetes, the vast majority of type 1 diabetics, 80% of insulin-dependent type 2 diabetics and 50% of non-insulin-dependent type 2 diabetics develop DR^[3]. At present, there is no effective prevention method for early DR, retinal photocoagulation, condensation and surgical treatment are all aimed at the lesions in the late proliferative stage^[4], so it is critical to find

a prevention and treatment method for early DR. Traditional Chinese medicine has certain advantages in the prevention and treatment of chronic diseases^[5-6].

Danhong injection is extracted from salvia miltiorrhiza and safflower. Salvia miltiorrhiza can improve microcirculation^[7]. Safflower can promote blood circulation, remove blood stasis and relieve pain^[8]. Modern pharmacological studies have shown that the effective components of salvia miltiorrhiza include tanshinone, salvianolic acid, salvianolic acid, which have strong antioxidant effects. These effective components can reduce vascular endothelial injury by inhibiting low-density lipoprotein (LDL) oxidation and enhance the ability of microvessels to resist hypoxia^[9]. The effective components of safflower include safflower and safflower yellow pigment, which can reduce thrombosis by reducing blood viscosity and anti-platelet aggregation. It can expand arterioles to a certain extent, enhancing the ability of tissue to tolerate hypoxia^[10-11]. According to Chinese pharmacopoeia, salvia miltiorrhiza is a kind of sedimentation, safflower is a kind of rising and floating, and the combination of the two drugs can remove pathogenic factors without hurting the positive energy.

Danhong injection has a strong protective effect on vascular endothelial cells, anti-apoptosis of nerve cells and promoting nerve regeneration. Promising results from clinical trials have fueled a growing acceptance of Danhong injection (DHI) as a Chinese Materia Medica standardized product for the treatment of ischemic stroke^[12]. Kuang and Tang^[13] believed that Danhong could prevent cerebral vasospasm after subarachnoid hemorrhage through clinical observation. Chen *et al*^[14] showed that Danhong injection enhance the therapeutic efficacy of mesenchymal stem cells in myocardial infarction by Promoting angiogenesis. Feng *et al*^[15] used Danhong injection in combination with lipid regulation in the treatment of patients with angina pectoris of coronary heart disease, and believed that Danhong injection could inhibit the apoptosis of endothelial cells, and the mechanism was related to the reduction of intracellular production of reactive oxygen species. Mao *et al*^[16] showed that Danhong injection attenuate isoproterenol-induced cardiac hypertrophy by regulating p38 and NF-kappa b pathway. In clinical studies, danhong injection has also been shown to be significantly effective in the prevention and treatment of diabetic nephropathy^[17-18], diabetic peripheral neuropathy^[19] and diabetic foot^[20], while the study on the prevention and treatment effect of DR is still blank.

In the past, it has been believed that the classic change of DR is diabetic retinal microvascular disease. In recent years, scholars have gradually found that DR also causes the damage of retinal nerve cells, which appears even earlier than the appearance of microcirculation disorder^[21-23]. In view of the pathological changes in these two aspects, we observed the retinal vascular

lesion and retinal nerve cell injury at both levels, hoping to further understand whether Danhong injection has a protective effect on the retina of diabetic rats.

In this study, we established a diabetic rat model by one-time injection of STZ, which is a relatively mature and stable diabetic animal model. At 12wk, two animals in the blank intervention group died. By observing the retinal HE staining, it was found that compared with the normal group, the diabetic rats had incomplete inner retinal boundary membrane, blurred inner and outer nuclear layer boundaries, disordered cell arrangement, and obvious swelling of nerve fiber layer. The morphology of retinal cells in Danhong intervention group was more regular than that in diabetes group, and the boundary of inner and outer nuclear layer was clearer than that in diabetes group. Looking at in the form of the retina at the same time, we are curious about its for retinal vascular endothelial growth factor (VEGF) expression. VEGF is recognized as the most important substance in retinal neovascularization^[24-27]. Although anti-VEGF drugs have been applied in clinical practice, they cannot be used as routine preventive drugs due to their high price. If there is a drug that is cheap and can prevent the production of VEGF, it should be widely used in clinical practice. Therefore, the expression of VEGF was detected by immunohistochemistry in our experiment. Finally, we found that the expression of VEGF in the diabetic group was marginally higher than that in the normal group, while the expression of VEGF in the Danhong intervention group was marginally lower than that in the diabetic group, which suggested that Danhong injection could reduce the generation of retinal new blood vessels by inhibiting the expression of VEGF.

In this experiment, a mature diabetic animal model was established by injecting STZ. After drug intervention, diabetic vascular disease and retinal nerve cell injury were observed at both levels. It was confirmed that Danhong injection has a protective effect on the retina of diabetic rats. It can improve the status of retinal ischemia and hypoxia, possible in part through down-regulation of

VEGF expression, reduce the formation of retinal neovascularization, and reduce the apoptosis of retinal nerve cells to a certain extent. In the following work, we will further explore the protective mechanism of the optic nerve and its influence on other organs of the body and explore in more depth the potential role of Danhong in modulating VEGF expression.

ACKNOWLEDGEMENTS

Foundation: Supported by Science and Technology Fund Project of Shanghai Jiao Tong University School of Medicine (No.14XJ22010).

Conflicts of Interest: Fan HY, None; Wang JF, None; Li Z, None; Chen Z, None.

REFERENCES

- 1 Li PL, Su WW, Yun S, Liao YQ, Liao YY, Liu H, Li PB, Wang YG, Peng W, Yao HL. Toward a scientific understanding of the effectiveness, material basis and prescription compatibility of a Chinese herbal formula Dan-Hong injection. *Sci Rep* 2017;7:46266.
- 2 Safi SZ, Qvist R, Kumar S, Batumalaie K, Ismail ISB. Molecular mechanisms of diabetic retinopathy, general preventive strategies, and novel therapeutic targets. *Biomed Res Int* 2014;2014:801269.
- 3 Nentwich MM. Diabetic retinopathy - ocular complications of diabetes mellitus. *World J Diabetes* 2015;6(3):489.
- 4 Bornfeld, Norbert. Treatment of proliferative diabetic retinopathy. *World J Diabetes* 2018;14(12):590-596.
- 5 Cheng TT, Huang JL, Liu XX, Shen DQ, Ma Y, Qian Q, Gao F, Zhou B, Du L. Research progress of diabetic retinopathy treated by traditional Chinese medicine. *Clinical Journal of Traditional Chinese Medicine* 2017;29(5):607-609.
- 6 Han JY, Li Q, Ma ZZ, Fan JY. Effects and mechanisms of compound Chinese medicine and major ingredients on microcirculatory dysfunction and organ injury induced by ischemia/reperfusion. *Pharmacol Ther* 2017;177:146-173.
- 7 Tung NH, Nakajima K, Uto T, Hai NT, Long DD, Ohta T, Oiso S, Kariyazono H, Shoyama Y. Bioactive triterpenes from the root of *Salvia miltiorrhiza bunge*. *Phytother Res* 2017;31(9):1457-1460.
- 8 Wang KH, Li SF, Zhao Y, Li HX, Zhang LW. *In vitro* anticoagulant activity and active components of safflower injection. *Molecules* 2018;23(1):170.
- 9 Li ZM, Xu SW, Liu PQ. *Salvia miltiorrhiza* Burge (Danshen): a golden herbal medicine in cardiovascular therapeutics. *Acta Pharmacol Sin* 2018;39(5):802-824.
- 10 Li LJ, Li YM, Qiao BY, Jiang S, Li X, Du HM, Han PC. Corrigendum to "the value of safflower yellow injection for the treatment of acute cerebral infarction: a randomized controlled trial". *Evid - Based Complementary Altern Med* 2016;2016:4270317.
- 11 Liao YQ, Liang FY, Liu H, Zheng YY, Li PB, Peng W, Su WW. Safflower yellow extract inhibits thrombus formation in mouse brain arteriole and exerts protective effects against hemorheology disorders in a rat model of blood stasis syndrome. *Biotechnol Biotechnol Equip* 2018;32(2):487-497.
- 12 Xu J, Tang LY, Zhang Q, Wei JY, Xian MH, Zhao Y, Jia Q, Li X, Zhang Y, Zhao Y, Wu HW, Yang HJ. Relative quantification of neuronal polar lipids by UPLC-MS reveals the brain protection mechanism of Danhong injection. *RSC Adv* 2017;7(72):45746-45756.
- 13 Kuang RZ, Tang XP. Prevention and treatment of cerebral vasospasm after subarachnoid hemorrhage with Danhong. *Chinese Journal of Experimental Surgery* 2015;32(9):2315.
- 14 Chen JR, Wei J, Huang YT, Ma YL, Ni JY, Li M, Zhu Y, Gao XM, Fan GW. Danhong injection enhances the therapeutic efficacy of mesenchymal stem cells in myocardial infarction by promoting angiogenesis. *Front Physiol* 2018;9:991.
- 15 Feng QT, Wang RX, Chen SJ. Effect of Danish injection combined with regulating therapy on vascular endothelial function in patients with angina pectoris. *Chinese Archives of Traditional Chinese Medicine* 2017;(9):2412-2414.
- 16 Mao HP, Wang XY, Gao YH, Chang YX, Chen L, Niu ZC, Ai JQ, Gao XM. Danhong injection attenuates isoproterenol-induced cardiac hypertrophy by regulating p38 and NF- κ B pathway. *J Ethnopharmacol* 2016;186:20-29.
- 17 Yang X, Xiao X, Wang HL, Li Y, Wang L, Li GS, Deng SP. Renoprotective effect of Danhong injection on streptozotocin-induced diabetic rats through a peroxisome proliferator-activated Receptor-mediated pathway. *Evid - Based Complementary Altern Med* 2018;2018:1-10.
- 18 Liu MY, Pan Q, Chen YL, Yang XX, Zhao BC, Jia LF, Zhu Y, Zhang BL, Gao XM, Li XJ, Han JH, Duan YJ. Administration of Danhong Injection to diabetic db/db mice inhibits the development of diabetic retinopathy and nephropathy. *Sci Rep* 2015;5:11219.
- 19 Wang Q, Guo ZL, Aori GL, Kong DW, Yang WQ, Zhang L, Yu YB. Danhong injection alleviates mechanical allodynia via inhibiting ERK1/2 activation and elevates BDNF level in sciatic nerve in diabetic rat. *Evid - Based Complementary Altern Med* 2018;2018:1-7.
- 20 Wu F, He ZQ, Ding R, Huang ZG, Jiang QX, Cui HM, Lin Y, Huang SB, Dai XL, Zhang JY, Wu ZG, Liang C. Danhong promotes angiogenesis in diabetic mice after critical limb ischemia by activation of CSE-H₂S-VEGF axis. *Evid - Based Complementary Altern Med* 2015;2015:1-8.
- 21 Ng DS, Chiang PP, Tan G, Cheung CG, Cheng CY, Cheung CY, Wong TY, Lamoureux EL, Ikram MK. Retinal ganglion cell neuronal damage in diabetes and diabetic retinopathy. *Clin Exp Ophthalmol* 2016;44(4):243-250.
- 22 Kim K, Kim ES, Yu SY. Longitudinal relationship between retinal diabetic neurodegeneration and progression of diabetic retinopathy in patients with type 2 diabetes. *Am J Ophthalmol* 2018;196:165-172.
- 23 Gu RD, Hao YY, Chen XL. Study on the mechanism of retinal ganglion cell apoptosis in early stage of diabetic rats. *Int J Ophthalmol* 2014;(3):402-406.
- 24 Simó R, Sundstrom JM, Antonetti DA. Ocular anti-VEGF therapy for diabetic retinopathy: the role of VEGF in the pathogenesis of diabetic retinopathy. *Dia Care* 2014;37(4):893-899.
- 25 Bandello F, Corvi F, La Spina C, Benatti L, Querques L, Capuano V, Naysan J, Chen XJ, Sarraf D, Parodi MB, Souied E, Freund KB, Querques G. Outcomes of intravitreal anti-VEGF therapy in eyes with both neovascular age-related macular degeneration and diabetic retinopathy. *Br J Ophthalmol* 2016;100(12):1611-1616.
- 26 Thomas AA, Feng B, Chakrabarti S. ANRIL: a regulator of VEGF in diabetic retinopathy. *Invest Ophthalmol Vis Sci* 2017;58(1):470.
- 27 Song LJ, Wang Y, Chen D, Gao FJ, Ding H, Li YM, Zhong M. Retinal morphology and expression of Bcl-2, Bax and VEGF in early diabetic rats. *Int J Ophthalmol* 2018;18(11):1951-1957.